



Comparative Study of Hollow Viscus and Solid Organ Injury in Blunt Trauma Abdomen

Dr. Sushil Kumar¹, Brajesh Kumar², Bikram Kumar³, Sunay Damle⁴,
Room No-55, Hostel No, RIMS, Bariatu, Ranchi, India

Received; 20 November 2016 Accepted; 29 November 2016; © The author(s) 2016. Published with open access at www.questjournals.org

ABSTRACT: Abdominal injury as a result of both blunt and penetrating trauma has an appreciable mortality rate from haemorrhage and sepsis. This study represents the experience with blunt trauma to the abdomen of patients from a tertiary care centre. The study was undertaken to know the demographic details, mode of injury, management and outcome of blunt trauma abdomen (BTA). All the blunt trauma abdomen cases admitted in RIMS Ranchi during period of July 2014 to September 2016. There were 55 consecutive cases of blunt trauma abdomen. Most common age group involved was 30-40 years followed by 20 to 30 year. Male and Female ratio was 3:1. Most common mode of injury was RTA 47.2%. Diagnosis was established in all cases by clinical examination, X-ray, ultrasound or CECT. Spleen (49%) was the commonest organ injured next Liver (21.8%). 67.2% (37patients) of cases underwent successful conservative treatment and 32.7% (18) operative treatment. Mortality was 10%. Non operative management (NOM) for BTA was found to be highly successful and safe. Definitive indications for laparotomy were hemodynamic instability and peritonitis. Patients with initial Hemodynamic instability are associated with a high risk of NOM failure. USG (FAST scan) in haemodynamically unstable patients as compared to CECT in stable patients were investigations of choice. Associated injuries influenced morbidity and mortality

I. INTRODUCTION

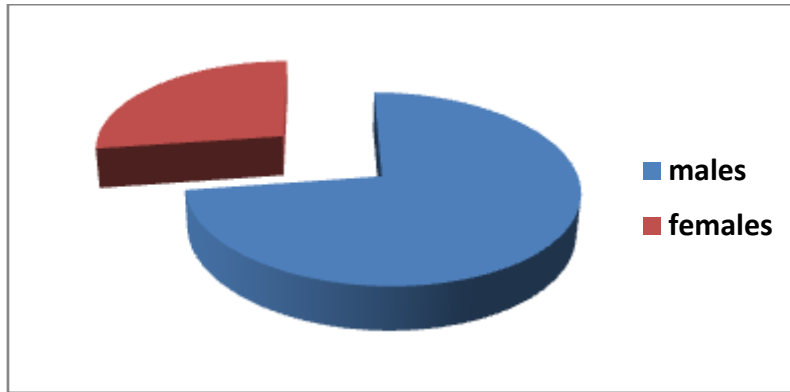
Blunt abdominal trauma (BAT) is a frequent emergency and is associated with significant morbidity and mortality in spite of improved recognition, diagnosis and management. Trauma is the leading cause of death and disability in developing countries and the most common cause of death under 50 years of age. In World BAT is the 7th cause of mortality and abdomen is the third most common injured region. Abdominal injuries require surgery in about 25% of cases. 85% of abdominal traumas are of blunt character. The spleen and liver are the most commonly injured organs as a result of blunt trauma. Initial resuscitation along with focused assessment with sonography in trauma (FAST) and computed tomography (CT) abdomen are very beneficial to detect those patients with minimal and clinically undetectable signs of abdominal injury. There has been increasing trend towards non operative management (NOM) of blunt trauma amounting to 80% of the cases with failure rates of 7-8%. NOM is a standard protocol for hemodynamically stable solid organ injured patients. Pre-hospital transportation, initial assessment, thorough resuscitative measures and correct diagnosis are of utmost importance in trauma management.

II. MATERIALS AND METHODS

All the blunt trauma abdomen cases admitted in RIMS Ranchi during period July 2014 to September 2016. After initial resuscitation, detailed clinical history, physical examination, laboratory tests and x-rays, ultrasonography (FAST) was done to arrive at the diagnosis. CT scan was done in some of the cases. The progress of patients was closely monitored and decision was taken to either continue with conservative management or to undertake laparotomy. Inferences were made for various variables like age, sex, cause of blunt abdominal trauma, time of presentation of patient, various procedures employed, associated extra abdominal injuries, post-operative complications and mortality.

III. RESULTS

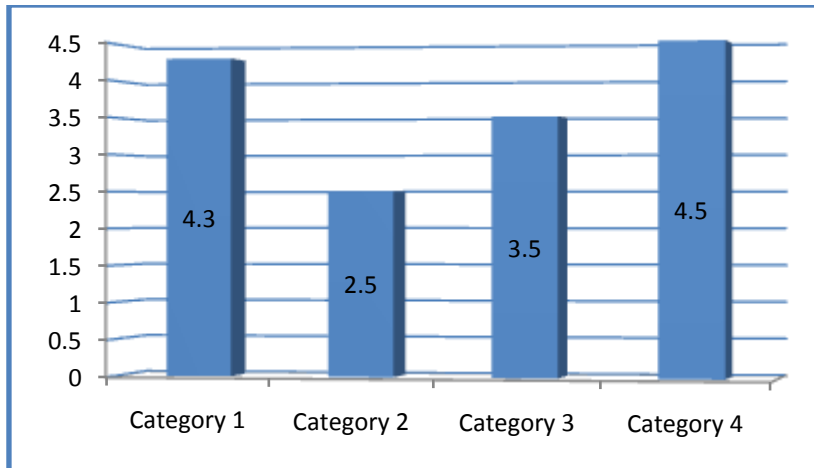
[1]. Sex Incidence: Out of 55 total cases of blunt abdominal trauma, 40(72.7%) were male and 15(27.2%) were female



IV. AGE INCIDENCE

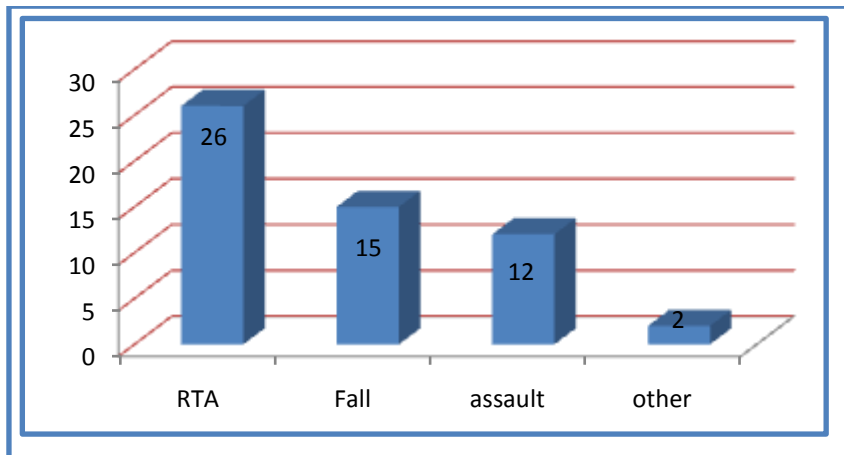
Patients of blunt abdominal trauma were divided in four age groups.

In 14-20 age group total 7 (12.7%) cases were there out of which 4 were males and 3 were females
 In 20-30 age group total 15(27.2%) cases were there out of which 14 were males and 1 was female
 In 30-40 age group total 20(36.36%) cases were there out of which 14 were males and 6 were females
 In >40 age group total 13(23.6%) cases were there out of which 8 were males and 5 were females



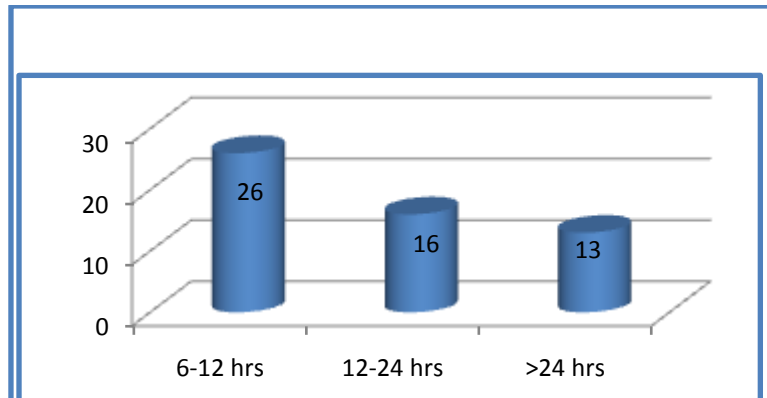
Mode Of Injury

Cause of blunt abdominal trauma in study population was as follows- road traffic accidents in 26(47.2%) patients, fall from height in 15(27.2%) patients, assault in 12(21.8%) patients and other causes in 2(3.6%) patients.



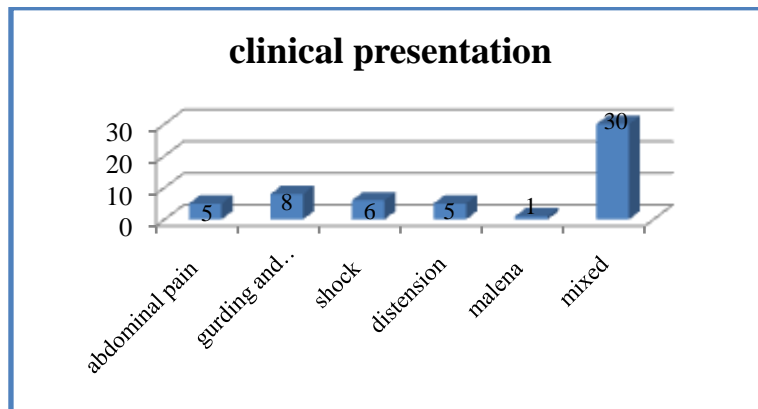
V. TIME OF PRESENTATION

Out of 55 cases, 26(47.2%) came to hospital within 12 hours of trauma; 16(29.09%) cases came within 12-24 hours after trauma and 13(23.6%) patients came after 24 hours of trauma



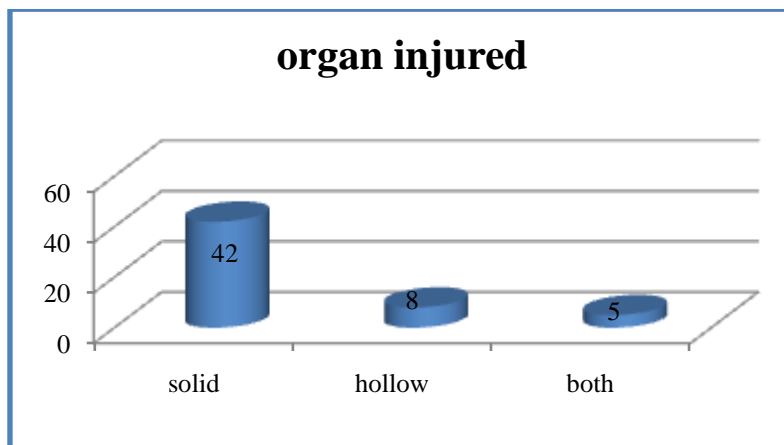
Clinical presentations:

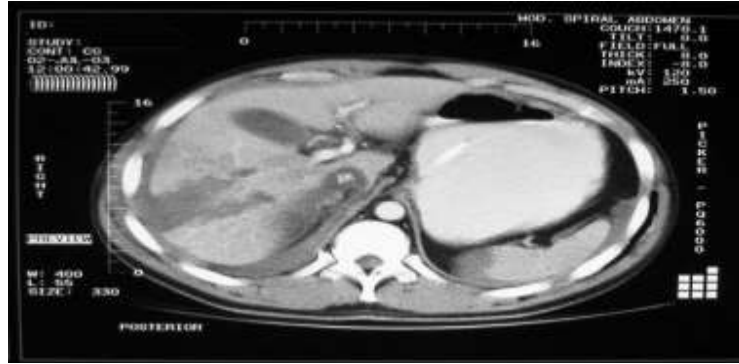
out of total 55 patients 5(9.09%) presented with abdominal pain, 8(14.5%) presented with demonstrable guarding and rigidity, 6(10.9%) presented with features of shock, 5(9.09%) patients presented with abdominal distension, 1(1.8%) patient presented with malena, and mixed sign & symptoms were seen in 30(54.5%) cases.



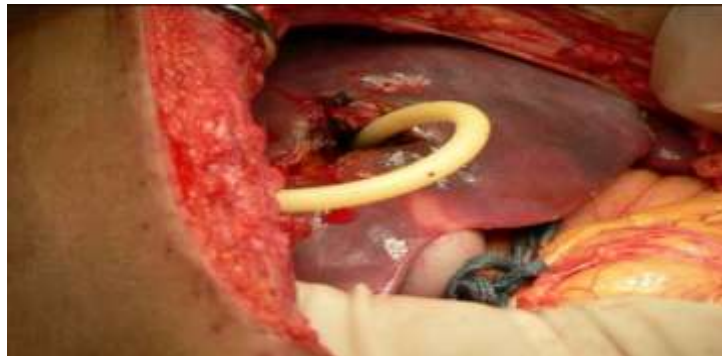
6 organs injured:

In the study population solid visceral injury was found in 42(76.3%) patients, hollow viscus injury was found in 8(14.5%) patients and both hollow & solid viscera were injured in 5(9.09%) patients.

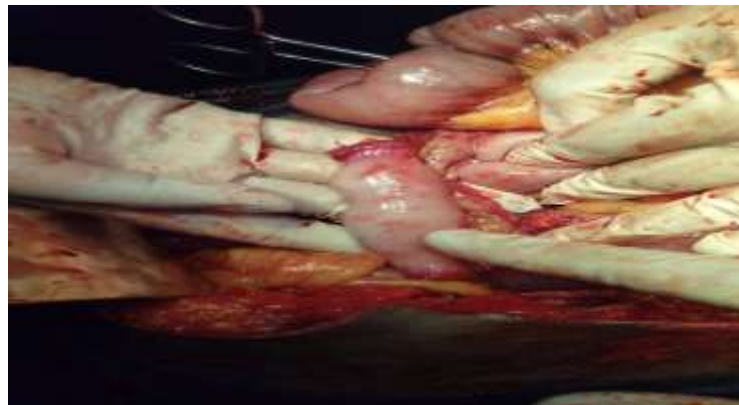




Blunt abdominal trauma with liver laceration

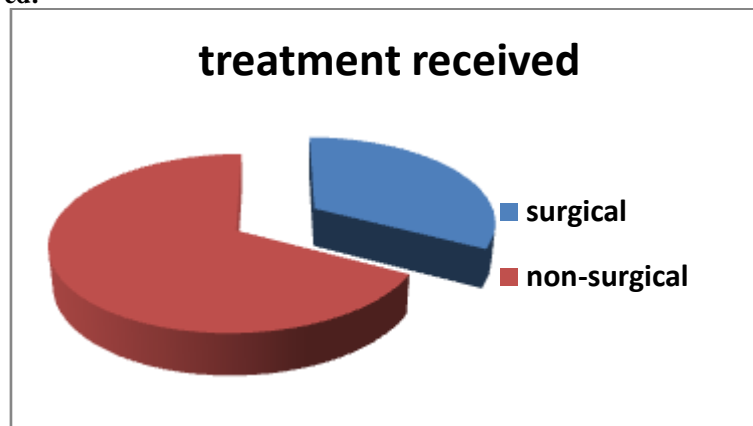


Liver laceration



Bowel transection

7 treatments received:



Morbidity and Mortality:

Mortality rate in our study was seen in 6(10%) cases. Commonest cause was polytrauma in 4 patients followed by sepsis/ARF in 2 patients. Post-operative complications most frequently observed in our study were Surgical site wound infection 16%, sepsis-(12%), , abdominal dehiscence(5.4%), other complications(12.7%), traumatic pancreatitis-1(1%).

VI. DISCUSSION

Blunt abdominal trauma is a hazardous task. Abdominal findings may be absent in 40% of patients with haemoperitoneum. Sometimes clinical evaluation of blunt abdominal injuries may be masked by other more obvious external injuries. Unrecognized abdominal injury is a frequent cause of preventable death after trauma. The patients who had sustained blunt abdominal trauma may have sustained injury simultaneously to other systems and it is particularly important to examine for injuries of head, thorax and extremities. 55 cases in our study with age of presentation is above 14 years. Male female ratio-3:1. Spleen (49%) was the commonest organ injured next liver (21%). Liver injuries were managed conservatively in most of the cases and in some cases hepatotomy was done (6). Splenic trauma in our study were managed either conservatively or splenectomy. Bowel perforation were managed by primary repair and resection - anastomosis. Nephrectomy was done in-1 patients. Laparotomy and bladder repair was done in 1 patients. Abdominal injuries were associated with various extra-abdominal injuries amongst which most common were rib fractures. Non-recognition of an extra abdominal injury may contribute to the patients' death when a relatively simple procedure might otherwise have saved the patient's life. Commonest post-operative complication in our study was wound infection and was managed by debridement and serial dressing. Early diagnosis can decrease mortality by 50%. Mortality is related to delayed presentation and diagnosis, associated injuries and delayed surgical intervention.

VII. CONCLUSION

Following Conclusions Can Be Drawn From This Study:

1. Conservative management is the treatment of choice in clinically stable patients. In patients not responding to conservative management or those with severe injuries; surgical treatment is needed.
2. Road traffic accident is the most common cause of such injuries. Road side safety measures and dedicated trauma centers near accident prone areas is necessary to limit the associated morbidity and mortality.
3. Males are more commonly injured in cases of blunt abdominal trauma. Incidence is highest in 30-40 years age group which is young and productive age group.
4. Plain X-ray abdomen is very useful investigation in blunt trauma abdomen cases more so in cases of hollow viscus injury.
5. Diagnostic peritoneal lavage; in recent times is not used commonly as it is invasive and can lead to unnecessary complications.
6. Ultrasound examination gives fairly good idea about solid organ injury and fluid collection. It has played important role in decreasing the popularity of diagnostic peritoneal lavage.
7. The most common viscera injured in present study is spleen followed by liver.
8. Small intestine is the most commonly injured hollow viscus in this study.
9. While most of the solid viscera injuries were managed conservatively; surgical treatment was very commonly needed in cases of hollow viscus injury.
10. Most of the patients in this study recovered without any complication.
11. Surgical wound infection was most common complication overall.
12. Other complications noted are; respiratory tract infection and fever, pancreatitis.
13. Mortality in present study is low.
14. A thorough and repeated clinical examination and appropriate diagnostic investigation is necessary for successful treatment of such patients.

REFERENCES

- [1]. Isenhour JL, Marx J (August 2007). "Advances in abdominal trauma". *Emerg Med Clin North Am.* **25** (3): 713–33, ix. doi:10.1016/j.emc.2007.06.002. PMID 17826214.)
- [2]. Blunt Trauma to Abdomen in Rural Setup: A Multiple Case Study by Shantanu Kulkarni **et al**
- [3]. Mukhopadhyay M (October 2009). "Intestinal Injury from Blunt Abdominal Trauma: A Study of 47 Cases". *Oman Med J.* **24** (4): 256–259. doi:10.5001/omj.2009.52. PMC 3243872. PMID 22216378
- [4]. Saxena AK, Nance ML. Abdominal trauma. <http://emedicine.medscape.com/article/940726-overview>
- [5]. Udeani J, Steinberg SR. Blunt abdominal trauma. <http://emedicine.medscape.com/article/433404-overview>
- [6]. *Journal of Trauma-Injury Infection & Critical Care*: January 2001 - Volume 50 - Issue 1 - pp 108-112
- [7]. Article Titles-2,576 *Ultrasounds for Blunt Abdominal Trauma* Dolich, Matthew O. MD; McKenney, Mark G. MD, FACS; Varela, J. Esteban MD; Compton, Raymond P. MD; McKenney, Kimberly L. MD; Cohn, Stephen M. MD, FACS.
- [8]. *Injury* Volume 47, Issue 9, September 2016, Pages 2006–2011. CT scan and Diagnostic Peritoneal Lavage: towards a better diagnosis in the area of nonoperative management of blunt abdominal trauma Nathalie Chereau^a et al

- [9]. Retrospective And Prospective Study Of Management And Outcome Of Blunt Abdomen Trauma In Tertiary Health Center In Last 5-Year 2009-2014 R. S. Raikwar¹, Abhay Brahmane², Sachin Arora
- [10]. Ministry of Health and Family Welfare. Integrated Disease Surveillance Project- Project Implementation Plan 2004-2009. New Delhi: Government of India; 2004:1-18.
- [11]. Raza et al.: Non operative management of abdominal trauma – a 10 years review. World Journal of Emergency Surgery 2013 8:14.
- [12]. Ahmet K, Tongue Y. Blunt abdominal trauma: evaluation of diagnostic options and surgical outcomes. Turkish J Trauma Emerg Surg 2008; 14:205-10.

Author Profile:



Dr. Sushil Kumar
M.B.B.S M.S (General surgery)
RIMS Ranchi