



Endodontic Management of Mandibular First Molar with Middle Mesial Canal – Case Reports

Dr. Pradnya V. Bansode¹, Dr. Seema, D. Pathak², Dr. M. B. Wavdhane³,
Dr. S. B. Khedgikar⁴, Dr. Reshma Sakharkar⁵

¹Professor and Head Of Department Of Conservative Dentistry and Endodontics. Govt Dental College & Hosp, Aurangabad

²Asso. Professor, ³- Asso. Professor, ⁴- Assit Professor, ⁵- Post Graduate Student

Received 12 Dec, 2016; Accepted 22 Dec, 2016 © The author(s) 2016. Published with open access at www.questjournals.org

ABSTRACT: For a successful root canal treatment meticulous cleaning, shaping and filling of the root canal system three dimensionally are primary requisites. It's proved beyond doubt that root canal system is highly complex, intricate and variable. The knowledge and attention to typical and atypical anatomy can be a critical factor in determining the success of endodontic therapy. The roots and canals of mandibular permanent first molars have several typical anatomical features, as well as a great number of anomalies. Therefore every effort must be made to identify and diagnose the variations. This article presents the case reports of endodontic management of mandibular first molars with middle mesial canals.

Keywords: mandibular first molar, middle mesial canal, root canal anatomy.

I. INTRODUCTION

The main objective of root canal treatment is the thorough mechanical and chemical cleansing of the entire pulp space followed by complete obturation with inert filling material [1]. Teeth with unusual canal morphologies are probably more prone to treatment failures due to insufficient knowledge of canal anatomy and aberrations associated with it.

Among the most frequent types of teeth treated by root canal therapy, mandibular first molars are the most prominent statistically in comparison to other types of teeth.[2,3] Various studies have shown that mandibular first molars are one of the teeth with complex root canal anatomy. This tooth presents high incidence of additional canals, intercanals, anastomosis and isthmus, mainly in the apical 5mm, which present challenge to accomplish the basic objectives of the root canal treatment which may lead to endodontic failures. Therefore, it is imperative that aberrant anatomy is identified before and during root canal treatment of such teeth.[4] Traditionally, mandibular molars are described as 2 rooted teeth with 2 canals in the mesial root and 1 or 2 canals in the distal root.[5] Vertucci and Williams first reported the presence of a middle mesial canal in a mandibular molar.[6] The reported prevalence of the MM canal in mandibular molars varies among studies using plastic casts [4], clearing [7], use of a file under magnification [8], scanning electron microscopy [9] and micro-computed tomographic (mCT) imaging [10].

With the advent of magnification, the astute clinician must be aware of literature reports that state that the mandibular first molar has a 1-15 % chance of a fifth canal.[11] In a clinical evaluation of 100 mandibular molars, Pomeranz et al [12] found that 12 molars had middle mesial canals in their mesial roots and classified them into three morphologic categories as follows: fin, confluent, and independent. According to their classification, an independent canal implies the canal originated as a separate orifice and terminated as a separate foramen, and only two cases were identified as independent. Goel et al [13] reported mandibular first molars had MM canals in 15.0% of specimens. Among these MM canals, only 6.7% of MM canals were independent. Fabra – Campos et al studied 145 teeth in vivo and reported 2.1% cases of middle mesial canal and 0.6% of middle distal canal.[14]

With increasing reports of aberrant canal morphology along with technically improved clinical environment, the clinician needs to be aware of this varied anatomy. Through this article, here we are presenting the successful endodontic management of mandibular molars with three mesial canals.

II. CASE I

A 22 year old male patient, reported to Department of Conservative dentistry and Endodontics, with the chief complaint of pain in the lower right back region of the jaw since past 1 month. On further questioning the patient revealed that the pain was dull aching and intermittent in nature. The pain aggravated during mastication after which it lingered for about 2-5 minutes. The past medical and dental history of the patient was non contributory. On clinical examination of area of chief complaint showed deep occlusal carious lesion was present with lower right first molar. Radiograph showed a large occlusal carious lesion with 1st molar. [“Fig, 1”] Two canals in the mesial root and one canal in the distal root were appreciated from the pre-operative radiograph. Diagnosis of chronic irreversible pulpitis was established root canal treatment was planned.

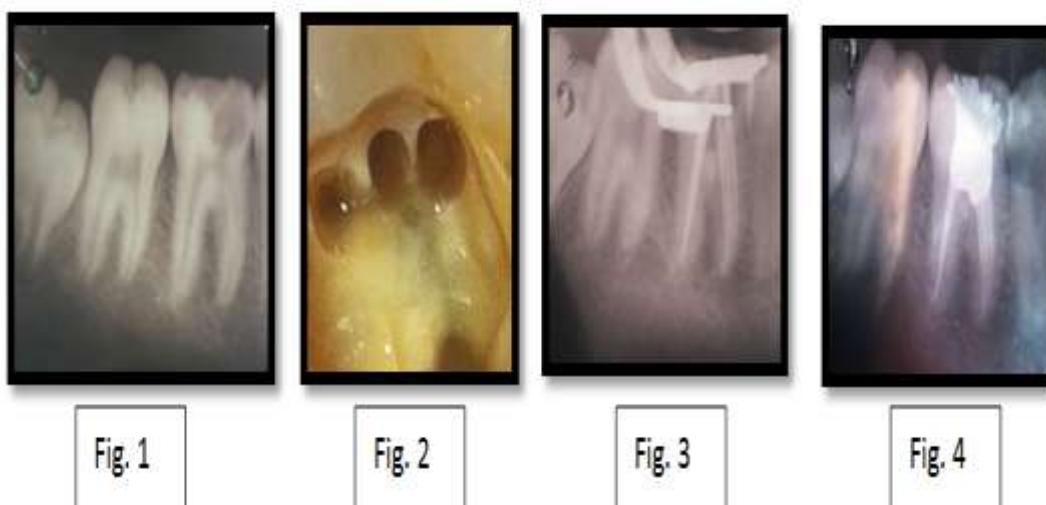Local anaesthesia was induced using 1.8 ml 2% lidocaine with 1: 200,000 epinephrine (Xylocaine, AstraZeneca Pharma India Ltd, Bangalore, India). Rubber dam was placed and a conventional endodontic access opening was established with an Endo Access Bur (Dentsply Tulsa, Tulsa, OK). On examining the pulpal floor, a small orifice was noted in between the MB and ML canal orifices and a canal orifice seen distally [“Fig.2”]. All canals were negotiated till full length. Working lengths were estimated by using an electronic apex locator (iPEX II, NSK) and then confirmed with a radiograph. All canals were cleaned and shaped with protaper rotary instruments (Dentsply-Maillefer, Switzerland) copious irrigation with 3% sodium hypochlorite. After preparation, the root canals were inserted with gutta-percha cones (Diadent, Seoul, Korea) to reconfirm working lengths [“Fig. 3”]. An angled radiograph showed three separate gutta percha cones till full working length. [“Fig. 4”] The patient experienced no post-treatment pain or discomfort and post endodontic restoration was done subsequently.

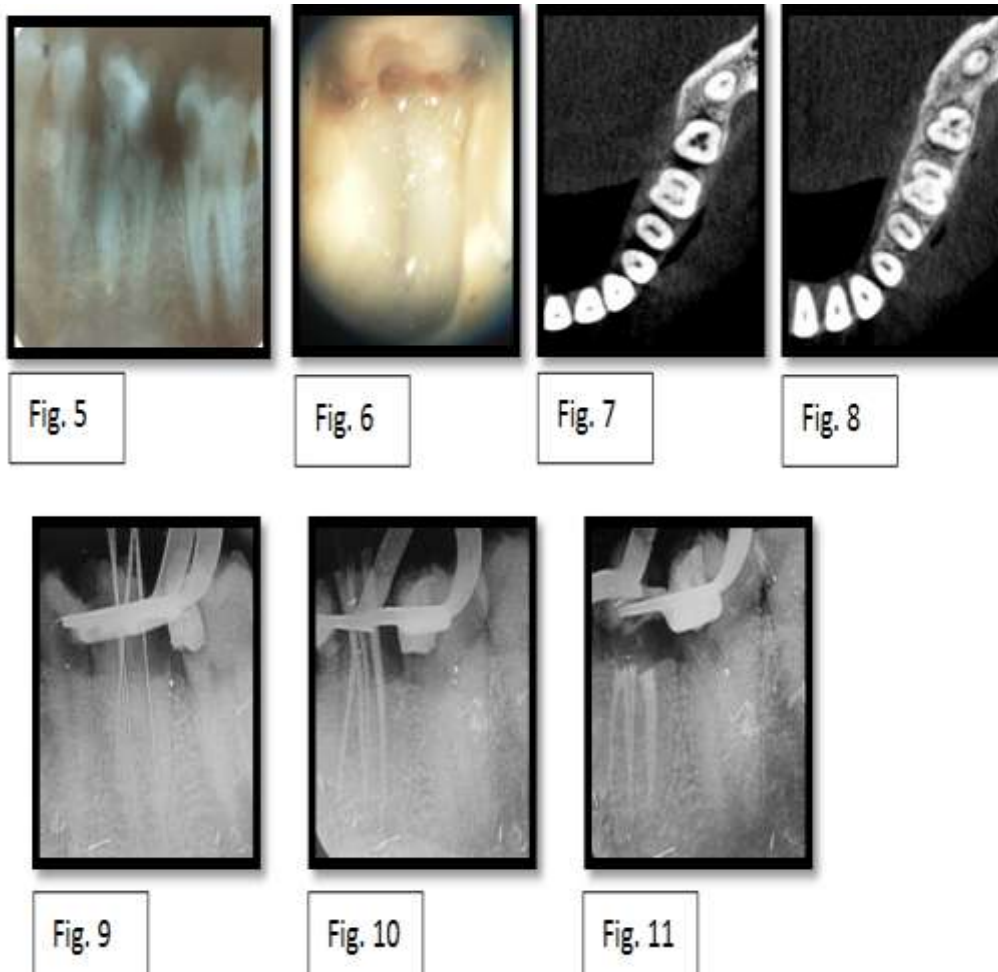
III. CASE II

A 24 years female patient came to the Dept of Conservative Dentistry & Endodontics with the chief complaint of pain in lower left back region of jaw since 15days. Patient gave a history of night pain in the given region since 2 days. On clinical examination deep carious lesion was seen with 35, 36 and 37, and pain on percussion was found with 36. Electric pulp test gave no response with 36. Radiographic Examination showed mesio-disto-occlusal undermining radiolucency with pulpal involvement and periodontal space widening in relation to the distal root of 36 [“Fig.5”]. Also large coronal radiolucency with 35 & 37. Diagnosis of pulp necrosis with acute apical periodontitis was made with mandibular first molar and endodontic treatment was discussed with patient and scheduled.

After profound anaesthesia and rubber dam application, standard endodontic access was made. By exploring the fissure located on the lingual aspect of the ML canal orifice with a sharp endodontic explorer, a “stick” was encountered. Access cavity was then examined under dental operating microscope (OPMI, Carl Zeiss, Germany) for better magnification. A third canal orifice was found between MB and ML canal orifices. [“Fig.6”] Further it was decided to take a CBCT scan for the same tooth. Evaluation of CBCT images showed three different canal orifices in the mesial root at cervical level while at apical third only two canal orifices were visible. [“Fig. 7 & 8”] Clinically when middle mesial canal negotiated with No. 10 k file, it was merged into mesio-lingual canal just below the middle third of the root. Standard procedure as mentioned above was followed to complete the root canal treatment. [“Fig.9,10 & 11”]

IV. FIGURES





V. DISCUSSION

Failure of root canal treatment is related to the presence of bacterial biofilm in the root canal system [15]. A missed canal or an unclean root canal system can be a cause for treatment failure. Among the anatomic variances, multiple canals in the mesial root of mandibular molars have been reported in the literature as having an incidence of 2.07% up to 13.3% of the examined cases [13,14]. Although many authors have agreed on the presence of three foramina in the mesial root, only a few have reported the presence of three independent canals, which presents itself as a rare anatomic variant [16]. This additional canal may be independent with a separate foramen or the additional canal may have a separate foramen and join apically with either the mesiobuccal or the mesiolingual canal.[13,17]

The detection of additional root canals requires a careful clinical and radiographic inspection. Diagnostic tools such as multiple radiographs, careful examination of the pulpal floor with a sharp explorer, and better visualization using an operating microscope are all important aids in the detection of additional root canals. Recently, various attempts have been made to use CT imaging for the confirmatory diagnosis of morphologic aberrations in the endodontic field.

In the first case, independent middle mesial canal was found, which considered as a rare finding. On the other hand, in second case middle mesial was merging with the mesio-lingual canal. Dental operating microscope and CBCT were used in the second case which was proved useful.

VI. CONCLUSION

Treating additional aberrant canals can be challenging, but the inability to find root canals may cause failures. The evaluation of CBCT images can result in better understanding of root canal anatomy, which enables the clinician to investigate the root canal system and to clean, shape, and obturate it more efficiently.

ACKNOWLEDGMENT

We wish to thank Dean, Dr. S. P. Dange, for his support and able guidance.

REFERENCES

- [1]. Vertucci FJ. Root canal anatomy of the human permanent teeth. *Oral Surg Oral Med Oral Pathol* 1984, 58:589-599.
- [2]. Hull TE, Robertson PB, Steiner JC, del Aguila MA. Patterns of endodontic care for a Washington state population. *J Endod* 2003;29(9):553-556.
- [3]. Wayman BE, Patten JA, Dazey SE. Relative frequency of teeth needing endodontic treatment in 3,350 consecutive endodontic patients. *J Endod* 1994;20(8):399-401.
- [4]. Kenia Maria Pareriara Soares de Toubes, Maria Ilma de Souza Cortes, Maria Alice de Abreu Valadares et al. Comparative Analysis Of Accessory Mesial Canal Identification In Mandibular First Molars By Using Four Different Diagnostic Methods. *J Endod* 2012;38:436-441.
- [5]. Skidmore AE, Bjorndal AM. Root canal morphology of the human mandibular first molar. *Oral Surg Oral Med Oral Pathol* 1971;32:778-84.
- [6]. Vertucci FJ, Williams RG. Root canal anatomy of the mandibular first molar. *JNJ Dent Assoc* 1974;48:27-8.
- [7]. Gulabivala K, Aung TH, Alavi A, Ng YL. Root and canal morphology of Burmese mandibular molars. *Int Endod J* 2001;34:359-70.
- [8]. Karapinar-Kazandag M, Basrani BR, Friedman S. The operating microscope enhances detection and negotiation of accessory mesial canals in mandibular molars. *J Endod* 2010;36:1289-94.
- [9]. Navarro LF, Luzi A, Garcia AA, Garcia AH. Third canal in the mesial root of permanent mandibular first molars: review of the literature and presentation of 3 clinical reports and 2 in vitro studies. *Med Oral Patol Oral Cir Bucal* 2007;12:E605-9.
- [10]. Harris SP, BowlesWR, Fok A,McClanahan SB. An anatomic investigation of the mandibular first molar using micro-computed tomography. *J Endod* 2013;39:1374-8.
- [11]. Baugh. Middle mesial canal of the mandibular first molar: a case report and Literature review. *JOE* 2004
- [12]. Pomeranz HH, Eidelman DL, Goldberg MG. Treatment considerations of the middle mesial canal of mandibular first and second molars. *J Endod* 1981;7:565-8.
- [13]. Goel NK, Gill KS, Taneja JR. Study of root canals configuration in mandibular first permanent molar. *J Indian Soc Pedod Prev Dent* 1991;8:12-4.
- [14]. Fabra-Campos H. Unusual root anatomy of mandibular first molars. *J Endod* 1985;11:568-72.
- [15]. Ricucci D, Siqueira JF Jr, Bate AL, Pitt Ford TR. Histologic investigation of root canal-treated teeth with apical periodontitis: a retrospective study from twenty-four patients. *J Endod* 2009;35:493-502.
- [16]. Holtzmann L. Root canal treatment of a mandibular first molar with three mesial root canals. *Int Endod J* 1997;30:422-3.
- [17]. H, Cimilli Cimilli T, Mumcu G, Kartal N, Wesselink P. Spiral computed tomographic demonstration of C-shaped canals in mandibular second molars. *Dentomaxillofac Radiol.* 2005;34:164-7.