



## Dense Evaginatus: Management Using Novel Materials A Case Report

Dr. Pradnya V. Bansode<sup>1</sup>, Dr. M.B. Wavdhane<sup>3</sup>, Dr. Seema D. Pathak<sup>3</sup>,  
Dr. Shirish B. Khedgikar<sup>4</sup>, \*Dr. Hardik B. Rana<sup>5</sup>

<sup>1</sup>Professor And Head Of Department, Department Of Conservative Dentistry & Endodontics, Govt. Dental College And Hospital, Aurangabad-431001, (M.S), College, MUHS, India. Mobile No.:- 09421679094

<sup>2</sup>Associate Professor, Department Of Conservative Dentistry & Endodontics, Govt. Dental College And Hospital, Aurangabad-431001, (M.S), College, MUHS, India. Mobile No.:- 09890053082

<sup>3</sup>Associate Professor, Department Of Conservative Dentistry & Endodontics, Govt. Dental College And Hospital, Aurangabad-431001, (M.S), College, MUHS, India. Mobile No.:- 09850694750

<sup>4</sup>Assistant Professor, Department Of Conservative Dentistry & Endodontics, Govt. Dental College And Hospital, Aurangabad-431001, (M.S), College, MUHS, India. Mobile No.:- 09850055455

<sup>5</sup>PG Student, Department Of Conservative Dentistry & Endodontics, Govt. Dental College And Hospital, Aurangabad (M.S), College, MUHS, India.

Received 15 Apr, 2017; Accepted 28 Apr, 2017 © The author(s) 2017. Published with open access at [www.questjournals.org](http://www.questjournals.org)

**ABSTRACT:** *Dens evaginatus is an uncommon developmental anomaly of human dentition characterized by a projection of enamel and dentin that usually encloses pulp tissue. Most commonly found as the tubercle on the occlusal surface of mandibular premolars and lingual surface of anterior teeth. Due to occlusal trauma this tubercle tends to fracture thus exposing the pathway to the pulp chamber of teeth. This case reports about the presentation of dens evaginatus in mandibular premolar 35 which was associated with open apex and chronic apical periodontitis. Root canal treatment was performed with tooth 35. DFDBA apical barrier and Biodentine as an apical plug was placed showing successful management of the same.*

**Keywords:** *Biodentine, Dens evaginatus, DFDBA, Open apex, Talon cusp, Tubercle*

### I. INTRODUCTION

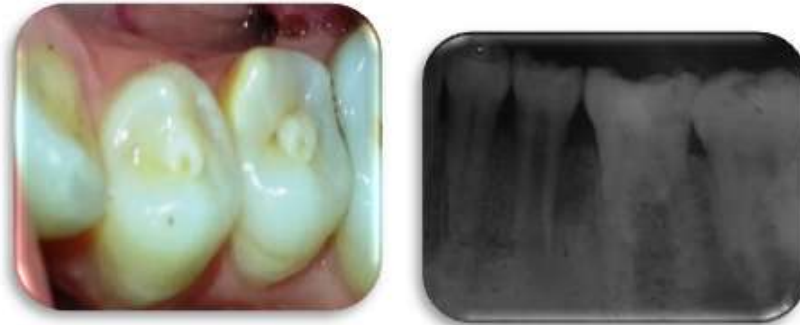Dens evaginatus (DE) or evaginatedodontoma is a developmental anomaly characterized by the presence of an accessory cusp, abnormal tubercle, or elevation that occurs in human dentition. It consists of enamel covering a dentinal core that usually contains pulp tissue. The presence of pulp within the cusp-like tubercle has clinical significance and distinguishes it from supplemental cusps, such as cusp of carabelli [1]. Early detection and management of this condition are important because trauma during mastication causes fracture or wear of the tubercle that leads to necrosis of pulp and periapical infection. This condition is predominantly found on the occlusal surface of mandibular premolars [2] and lingual surface of anterior teeth (mainly maxillary lateral incisors) [3]. Prevalence of DE studied in several population ranges from 1% to 4% [4]; the prevalence was found in approximately 2% of Asian descent population [5]. Higher rates of occurrence were reported among the Chinese population, 1.29%–3.6% [6]. It is usually observed as bilateral, symmetric distribution, with a slight sexual predilection for females.

### II. CASE REPORT

A 30-year-old male visited the department with concerned about the pain and difficulty on chewing on his left side of jaw. On examination patient had fair oral hygiene and occlusal tubercle present in mandibular second premolar was found (Figure 1). Tooth# 35 was tender on percussion. Pulp vitality testing with electric pulp tester showed no response with the same. Intraoral Periapical Radiograph (IOPAR) revealed periapical radiolucency with open apex in relation to 35 (Figure 2). No systematic and congenital disease was seen. As the root was having an open apex, it was planned to start with conventional root canal therapy followed by the placement of an apical barrier and apical plug and back filling with guttapercha. Access cavity preparation was done on tooth 35. By keeping in mind that not to weaken the radicular dentin more, minimal instrumentation

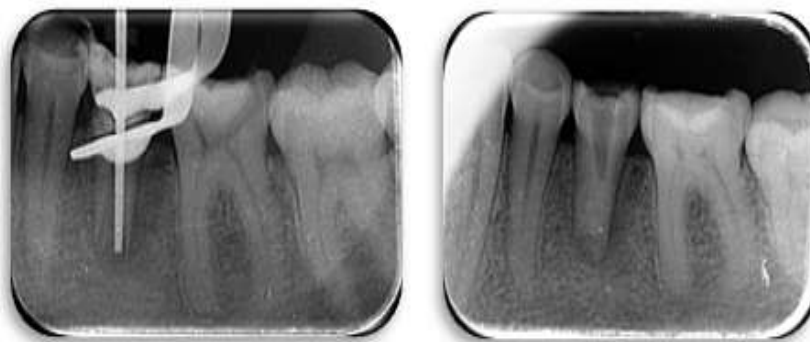
\*Corresponding Author: Dr. Pradnya V. Bansode<sup>1</sup>  
Professor And Head Of Department, Department Of Conservative Dentistry & Endodontics,  
Govt. Dental College And Hospital, Aurangabad-431001, (M.S), College, MUHS, India.

was done by circumferential filling using hand K-files (Mani, Inc., Japan). During instrumentation, the canals were irrigated copiously with 2.5% sodium hypochlorite solution followed by final wash with normal saline to remove extruded hypochlorite through open apex if any. Drying of the canal was done with absorbent paper points (Dentsply, Maillefer). Triple antibiotic paste root canal dressing was performed and changed every 14 days followed by frequent root canal irrigation with hypochlorite and saline for the period of one month. The access cavity was temporized with the intermediate restorative material (IRM, Dentsply Caulk, Milford, USA). After one month patient was asymptomatic.

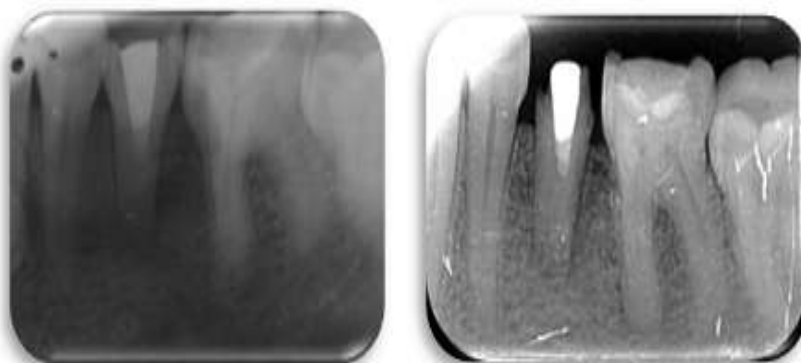


**Figure 1:** Occlusal tubercle in mandibular pre molars. **Figure 2:** Diagnostic IOPAR, periapical radiolucency and open apex with respect to 35.

The tooth was again isolated under rubber dam and the canals thoroughly irrigated with hypochlorite and saline to wash out any remnants of triple antibiotic paste. DFDBA was mixed with normal saline to packable consistency. It was then carried to periapical area under radiographic guidance with the help of endodontic plugger having rubber stop at pre adjusted working length (fig 3). After having confirmed an adequate matrix mass of DFDBA, Biodentine was mixed and placed over DFDBA with the help of mesing gun to get compact plug of 3-4 mm (fig 4). Biodentine plug was allowed to set for 10-12 minutes after which remainder of canal was obturated with guttapercha. Access opening was sealed with high copper silver amalgam. (fig 5). At 6 months follow up healing in periapical area can be appreciated (fig 6).



**Figure 3:** DFDBA placement using plugger **Figure 4:** Biodentine as an apical plug



**Figure 5:** Post-operative radiograph **Figure 6:** 6 months follow up

### III. DISCUSSION

Dens evaginatus is a tooth anomaly with considerable clinical significance causing occlusal interference. Maintaining clean area between the nodule and the tooth becomes difficult, and caries is often found. There are high chances of pulp exposure during early phases of root development, resulting in pulp necrosis and incomplete root formation. The unusual tubercle elevation on the tooth surface is the usual presentation but sometimes, due to fracture or attrition, no external evidence of the malformation may be evident [7]. Thus, early detection of these conditions is so important that preventive management can be started as early as possible. In the tooth/teeth with DE with vital pulp, selective reduction of the opposing occluding teeth can be done or, in a situation where the tubercle has fractured, it can be sealed with resin. In the case of DE with pulp exposure during the early phase of root development, pulpotomy is suggested. If the pulp is necrotic, root end barrier in the case of the immature apex and conventional root canal treatment should be performed on the mature tooth [1]. Interappointment antimicrobial medication can be advantageous to curtail bacterial regrowth and possibly even improve bacterial suppression [8]. Studies reported the clinical effectiveness of triple antibiotic paste in cases of apical periodontitis [9,10]. The antibiotic combination was reported to be more effective against mixed bacterial flora as in infected root canal tested when compared with calcium hydroxide, iodine potassium iodide, or iodoform [11]. Gomes-Filho et al. [12] evaluated the response and concluded that triple antibiotic paste is a biocompatible intracanal medicament.

A study conducted by Windley et al. [9] observed that the use of triple antibiotic paste following irrigation resulted in significant reduction in bacteria compared to that of irrigation with sodium hypochlorite alone. Studies have demonstrated that predictable disinfection of the root canal system can be achieved by proper antimicrobial intracanal medication [13]. The major problem in cases of a wide open apex is the need to limit the material to the perforation, thus avoiding the extrusion of a large amount of material into the periodontal tissue [14,15]. A large volume of the extruded material may set before it disintegrates and get resorbed. This might result in the persistence of the inflammatory process, which may complicate or even prevent repair of the tissue [14,15]. Using a matrix avoids the extrusion of the material into the periodontal tissues, reduces leakage in the sealing material and allows favorable response of the periodontal tissues. DFDBA is obtained from cortical bone of long bones due to its high content of bone inductive proteins and less antigenic activity than cancellous bone. The collagen matrix present in DFDBA acts as a scaffold that provides osteoconductive properties alongside the osteoinductive behavior [16]. BMPs are associated with the organic matrix of bone and embedded within mineral content, so demineralised process in formation of DFDBA increases its bioavailability. BMPs attract mesenchymal stem cells and induce them to differentiate into chondrocytes leading into endochondral bone formation [17]. This property is helpful in healing of large periapical lesions. Taking into consideration all these advantages of DFDBA, we have used these materials as an apical barrier matrix over which Biodentine was placed proving success of this case.

### IV. CONCLUSION

The communication of root canal to oral cavity due to the tubercle opening may contribute to harboring virulent microorganisms that succeeds in colonizing the canal and thus periapex. The clinician should be aware of such anomalies and their consequences so that proper treatment modalities can be instituted. Early detection and careful treatment planning are needed to prevent further complication of the condition.

### REFERENCES

- [1]. M. E. Levitan and V. T. Himel, "Dens evaginatus: literature review, pathophysiology, and comprehensive treatment regimen," *Journal of Endodontics*, vol. 32, no. 1, pp. 1–9, 2006.
- [2]. S. Stecker and A. J. DiAngelis, "Dens evaginatus. A diagnostic and treatment challenge," *The Journal of the American Dental Association*, vol. 133, no. 2, pp. 190–193, 2002.
- [3]. E. Dankner, D. Harari, and I. Rotstein, "Dens evaginatus of anterior teeth. Literature review and radiographic survey of 15,000 teeth," *Oral Surgery, Oral Medicine, Oral Pathology, Oral Radiology, and Endodontics*, vol. 81, no. 4, pp. 472–475, 1996.
- [4]. F. J. Hill and W. J. Bellis, "Dens evaginatus and its management," *British Dental Journal*, vol. 156, no. 11, pp. 400–402, 1984.
- [5]. C. E. Jerome and R. J. Hanlon Jr., "Dental anatomical anomalies in Asians and Pacific Islanders," *Journal of the California Dental Association*, vol. 35, no. 9, pp. 631–636, 2007.
- [6]. G. S. Kocsis, A. Marcsik, E. L. K'okai, and K. S. Kocsis, "Supernumerary occlusal cusps on permanent human teeth," *Acta Biologica Szegediensis*, vol. 46, no. 1-2, pp. 71–82, 2002.
- [7]. A. Ayer, M. Vikram, and P. Suwal. "Dens Evaginatus: A Problem-Based Approach Case Reports in Dentistry" Volume 2015, Article ID 393209
- [8]. Z. Metzger, B. Basrani, and H. E. Goodis, "Instruments, materials, and devices," in *Cohen's Pathways of the Pulp*, K. M. Hargreaves and S. Cohen, Eds., pp. 223–282, Elsevier, Mosby, 2011.
- [9]. W. Windley III, F. Teixeira, L. Levin, A. Sigurdsson, and M. Trope, "Disinfection of immature teeth with a triple antibiotic paste," *Journal of Endodontics*, vol. 31, no. 6, pp. 439–443, 2005.
- [10]. B. Thibodeau, F. Teixeira, M. Yamauchi, D. J. Caplan, and M. Trope, "Pulp revascularization of immature dog teeth with apical periodontitis," *Journal of Endodontics*, vol. 33, no. 6, pp. 680–689, 2007.
- [11]. R. C. Pallotta, M. S. Ribeiro, and M. E. D. L. Machado, "Determination of the minimum inhibitory concentration of four medicaments used as intracanal medication," *Australian Endodontic Journal*, vol. 33, no. 3, pp. 107–111, 2007.

- [12]. J. E. Gomes-Filho, P. C. T. Duarte, C. B. de Oliveira et al., "Tissue reaction to a triantibiotic paste used for endodontic tissue self-regeneration of nonvital immature permanent teeth," *Journal of Endodontics*, vol. 38, no. 1, pp. 91–94, 2012.
- [13]. C. J. Baumgartner, J. F. Siqueira, C. M. Sedgley, and A. Kishen, "Microbiology of endodontic disease," in *Ingle's Endodontics 6*, J. I. Ingle, L. K. Bakland, and J. C. Baumgartner, Eds., pp. 221–308, BC Decker Inc, Hamilton, Canada, 2008.
- [14]. Broon NJ, Bramante CM, Assis GF, Bortoluzzi EA, Bernardineli N, Moraes IG, et al. Healing of root perforations treated with mineral trioxide aggregate (MTA) and Portland cement. *J Appl Oral Sci* 2006;14:305-11.
- [15]. Holland R, Mazuqueli L, Souza V, Murata SS, Dezan E Jr. Influence of the type of vehicle and limit of obturation on apical and periapical tissue response in dogs teeth after root canal filling with mineral trioxide aggregate. *J Endod* 2007;33:693-7.
- [16]. Drosos GI, Kazakos KI, Kouzoumpasis P & Verettas DA. (2007). *Injury*;38Suppl 4:S13-21.
- [17]. Esposito M, Piattelli M, Pistilli R, Pellegrino G. & Felice P. *Eur J Oral Implantol* 2010;3(4):297-305.