



## The Prevalence of Carotid Artery Calcifications in Periodontology Clinics in Eastern Turkish Population

Hacer Sahin Aydinyurt <sup>1</sup>

<sup>1</sup>(Periodontology Department Van Yuzuncu Yil University Faculty of Dentistry, Turkey)  
Corresponding Author: Assist. Prof. Hacer Sahin

**ABSTRACT:** Panoramic radiographs are frequently used with intraoral radiographs for diagnosis, treatment planning and evaluation of treatment outcomes in periodontology. The aim of this study was to determine the prevalence of carotid artery calcification (CAC) on digital panoramic radiographs in patients administering to the periodontology clinic. This retrospective study included a total of 999 patients, 544 women, 455 men, 50 years old and over who applied to the Periodontology Clinic of the Faculty of Dentistry in Van Yuzuncu Yil University. CAC was not detected in 832 (83.2%) of the total 999 patients, while CAC (+) was detected in 167 (16.71%) patients. Of the CACs detected in patients included in the study, 2.5% were detected as vertical linear, 5.61% as nodular and 1.6% as heterogeneous. It is important in terms of health policies that there is no need for an additional cost for this early diagnosis of the CACs with panoramic radiographs. It is of utmost importance that periodontists or dentists direct patients, in whom CAC is detected in panoramic radiographs, to the cardiology department for further investigations in terms of reducing the risk of stroke. More studies are needed to better understanding of the relationship between periodontal disease and CACs.

**KEYWORDS:** Carotid artery calcification, Panoramic radiography, Periodontics

Received 29 November, 2018; Accepted 17 December, 2018 © The Author(S) 2018.

Published With Open Access at [Www.Questjournals.Org](http://Www.Questjournals.Org)

### I. INTRODUCTION

Periodontal disease is a disease characterized by inflammation of the periodontal tissues caused by microorganisms in the oral cavity and affects approximately 90% of the world population. Losses in the alveolar bone and connective tissue are observed due to periodontal diseases, which may lead to tooth loss [1–3]. In addition, periodontal disease has been associated with many systemic diseases such as coronary artery diseases, stroke, head and neck cancer, pregnancy complications and diabetes [4–9]. Periodontal disease is affected by risk factors such as smoking and diabetes, similar to vascular diseases [10,11].

Atherosclerosis is a progressive inflammatory disease and its prevalence of morbidity and mortality is reported to be very high in developed countries. It has been reported that atherosclerosis may cause peripheral arterial disease, coronary artery disease or stroke [12,13]. The most common region atherosclerosis is observed is the internal carotid artery, and 50% of cerebrovascular events caused by atherosclerotic plaques are reported in this region [14]. The World Health Organization reports that cerebrovascular events in North America, Europe and Asia are the third leading cause of death and disability worldwide [15]. In the literature, there are studies indicating that there is a significant relationship between periodontal disease and carotid atherosclerosis, as well as studies that reject this relationship [16–18].

Panoramic radiographs are frequently used with intraoral radiographs for diagnosis, treatment planning and evaluation of treatment outcomes in periodontology [19]. The advantage of panoramic radiographs is that they provide the opportunity to visualize teeth, alveolar bones and regional structures with a lower radiation dose than other alternative methods [20,21].

As known, early diagnosis of risk factors decreases the morbidity and mortality rate. First, Friedlander and Lande stated in 1981 that panoramic radiographs could be helpful in detecting carotid artery calcification (CAC), which is one of the important causes of stroke and can be observed at the level of C3-C4 vertebrae [22]. Panoramic radiographs allow monitoring of all dental and maxillofacial structures in a rapid and cost-effective manner, as well as be used in the detection of presence of CAC. CAC can easily be observed in cases where these lesions located at the carotid bifurcation area near the pharynx are calcified [23]. However, CAC is not the only cause of calcifications observed in the cervical region. Physicians should also consider anatomical

structures such as thyroid cartilage, hyoid bone, calcified stylohyoid ligament and epiglottis and pathological conditions such as calcified lymph node, phlebolith, submandibular salivary gland stone and tonsillolith in differential diagnosis [24,25]. The aim of this study was to determine the prevalence of CAC on digital panoramic radiographs in patients administering to the periodontology clinic.

## **II. MATERIAL and METHODS**

This retrospective study included a total of 999 patients, 544 women, 455 men, 50 years old and over who applied to the Periodontology Clinic of the Faculty of Dentistry in Van Yuzuncu Yil University between October 2017 and October 2018. The materials and methods of the study were approved by the Non-Invasive Clinical Research Ethics Committee in Van Yuzuncu Yil University. (Decree no: 12.10.2018-06) The inclusion criteria were determined as being over 50 years of age, digital panoramic radiography having been obtained during routine periodontal treatment and the cervical C3-C4 region being clearly observable.

Digital panoramic radiographs were taken from patients for periodontal diagnosis (Sirona Orthophos XG, 64 kW, 4 mA, 10 s), and a standard computer with 23" LED display and 1600\*900 pixel screen resolution was used for CAC analysis (Lenovo C560, Lenovo PC HK Limited, China).

Irregular, heterogeneous, vertical linear or nodular radiopaque masses detected at the cervical C3-C4 levels have been reported. In the differential diagnosis, thyroid cartilage, hyoid bone, calcified stylohyoid ligament, epiglottis, calcified lymph node, phlebolith, submandibular salivary gland stone and tonsillolith were taken into consideration. Digital panoramic radiographs in which anatomical structures and vertebrae were not clearly identified and patients with incomplete information were excluded from the study. Radiographs with low quality, those taken with over/under dose and those where the patient position was not correct were excluded from the study. All data were re-evaluated two weeks after the initial data analysis to minimize the margin of error.

### **Statistical Analysis**

The data were analyzed with SAS version 9.4. The prevalence of CAC was determined by frequency analysis. The likelihood ratio Chi-squared test was used to test the association between CAC prevalence and genders. The results were considered to have a significant difference if the significance level was less than .05. The Bowker's test for symmetry was conducted to compute the tests and measures of agreement for the contingency tables between left and right.

## **III. RESULTS**

The mean age of the patients included in the study was determined as  $59.67 \pm 7.69$ . There was no statistically significant difference between women ( $59.46 \pm 7.44$ ) and men ( $59.83 \pm 7.47$ ) in terms of the mean age ( $p > 0.05$ ) (Table-1). There was no statistically significant difference between patients with CAC ( $59.70 \pm 7.08$ ) and without CAC ( $59.62 \pm 7.53$ ) in terms of age ( $p > 0.05$ ). There was no statistically significant difference between men and women in terms of CAC prevalence ( $p > 0.05$ ) (Figure-1).

CAC was not detected in 832 (83.2%) of the total 999 patients, while CAC (+) was detected in 167 (16.71%) patients (Table-1). Of the CACs detected in patients included in the study, 2.5% were detected as vertical linear, 5.61% as nodular and 1.6% as heterogeneous (Table-2). CAC (-) was detected in 457 of the female patients, while CAC (+) was detected in 87 female patients. CAC (-) was detected in 375 of the male patients, while CAC (+) was detected in 80 male patients (Table-1) (Figure-1).

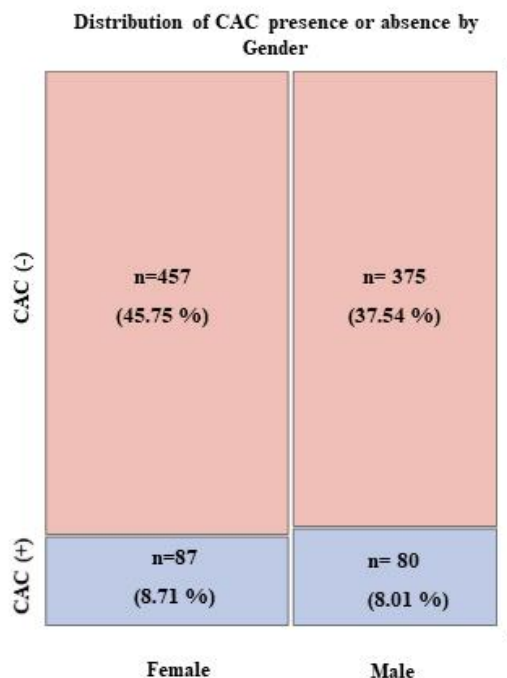
In the panoramic radiographs, 5.45% vertical linear, 5.81% nodular and 1.5% heterogeneous CAC were detected on the left side, while of the CACs detected on the right side in 9.71% of all patients, 2.50% were vertical linear, 5.61% were nodular and 1.60% were heterogeneous. The difference detected on both sides in terms of CAC characteristic was found to be statistically significant ( $p < 0.05$ ) (Figure-2). It was observed that 11.01% of 167 CACs detected on panoramic radiographs were unilaterally located and 5.7% were bilaterally located (Figure-3).

**Table-1:** Distrubution of age, frequency of CAC (-)s and CAC (+)s

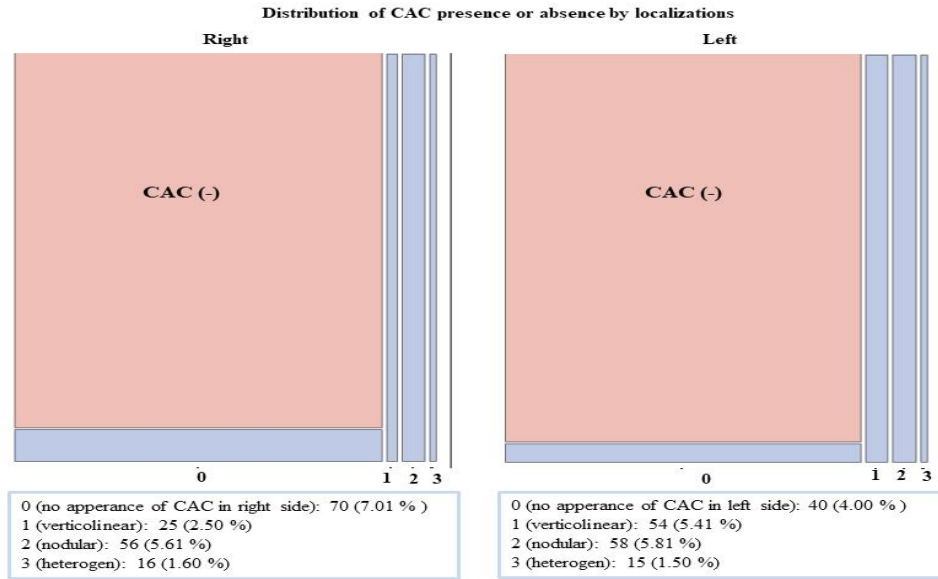
	Age (mean±SD)	CAC (-) n (%)	CAC (+) n (%)
Female	59.46±7.44 <sup>a</sup>	457 (45.75 %)	87 (8.71 %)
		Total 544	
Male	59.83±7.47 <sup>a</sup>	375 (37.54 %)	80 (8.01%)
		Total 455	
<b>Right</b>			97 (9.71)
Vertikal linear	61.64±7.13	902 (90.29 %)	25 (2.50 %) <sup>a</sup>
Nodular	58.26±5.87		56 (5.61 %) <sup>b</sup>
Heterogen	60.50±10.28		16 (1.60 %) <sup>c</sup>
<b>Left</b>			127 (12.72 %)
Vertikal linear	60.90±6.36	872 (87.28 %)	54 (5.41 %) <sup>a</sup>
Nodular	57.55±7.52		58 (5.81 %) <sup>b</sup>
Heterogen	60.40±9.03		15 (1.50 %) <sup>c</sup>
CAC-	59.62±7.53 <sup>a</sup>		
CAC +	59.70±7.08 <sup>a</sup>		
<b>Total</b>	59.67±7.69	832 (83.2%)	167 (16.71) %
		Total 999	

**Table-2:** Frequency of CAC characteristics in left and right sides

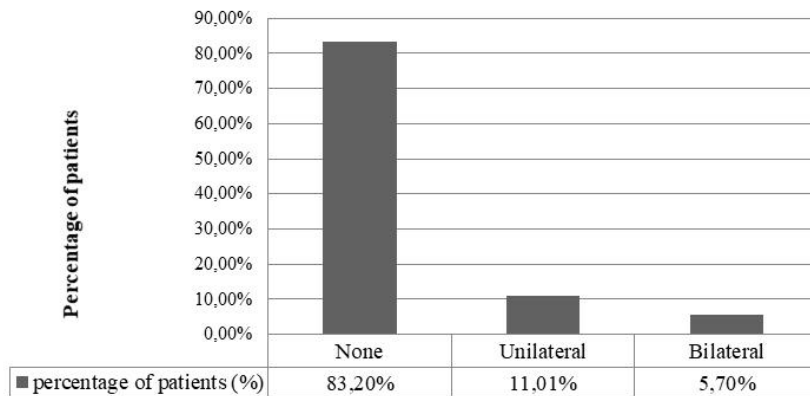
Right	None		Vertikolimeer	Left		Total
Frequency (percent)	None (%)	Vertikolimeer (%)	Nodular (%)	Heterogen (%)	Total (%)	
None (%)	832 (83.28)	40 (4.00)	23 (2.30)	7 (0.70)	902 (90.29)	
Vertikolimeer (%)	13 (1.30)	11 (1.10)	0 (0.00)	1 (0.10)	25 (2.50)	
Nodular (%)	21 (2.10)	2 (0.20)	30 (3.00)	3 (0.30)	56 (5.61)	
Heterogen (%)	6 (0.60)	1 (0.10)	5 (0.50)	4 (0.40)	16 (1.60)	
<b>Total (%)</b>	<b>872 (87.29)</b>	<b>54 (5.41)</b>	<b>58 (5.81)</b>	<b>15 (1.50)</b>	<b>999 (100.00)</b>	



**Figure-1:** Distribution of CAC presence or absence by gender



**Figure-2:** Distribution of CAC presence or absence by localizations



**Figure-3:** Distribution of CAC presence or absence by none, bilateral or unilateral

#### IV. DISCUSSION

Atherosclerotic cardiovascular diseases describe a group of diseases including fatal or non-fatal coronary artery diseases (myocardial infarction, angina), ischemic cerebrovascular diseases (stroke) and peripheral arterial diseases. Tonetti et al. reported strong epidemiological evidences describing the relationship between periodontal disease and cardiovascular diseases. It was stated that the relation of periodontitis with cardiovascular diseases may be caused by the microbiota, which plays a role in the pathogenesis of periodontitis, directly or indirectly increasing the systemic inflammation and affecting the pathogenesis of athero-thrombogenesis [26]. Panoramic radiographs routinely taken during dental or periodontal treatment in general may be useful in the detection of CAC, a risk factor for stroke [22, 27]. Dentists can distinguish CACs from anatomic and pathological structures in differential diagnosis [28,29]. Considering the importance of early diagnosis and treatment for health, CAC prevalence was evaluated on the panoramic radiographs of patients who applied to our clinic for periodontal treatment with or without surgery. Early diagnosis of CAC by is considered an important step towards reducing the risk of stroke by periodontists or dentists. However, it is reported in the literature that the gold standard for the detection of CAC is the use of panoramic radiographs together with color Doppler ultrasound [30]. It can be considered as a limitation of the study that the detection of CAC has not been confirmed with color Doppler ultrasound in this study.

Beckstrom et al. reported a significant correlation between alveolar bone loss and CAC incidences. It was reported that the increase in alveolar bone loss with age and the increase in the incidence of CAC were parallel [29]. Studies in the literature indicate that the severity and prevalence of periodontal disease increases with age [31,32]. Papapanou et al. showed that annual bone loss was 0.28 mm in 70-year-old individuals and 0.07 mm in 25-year-old individuals [33]. Bone loss with age and increased severity of periodontal disease can be

considered as a cumulative picture of long-term exposure to bacterial plaque and oral history of individuals [34]. Considering this relationship between age, periodontal disease and alveolar bone loss, it is thought a reasonable result to see that CAC is more common in patients compared to those applying to the general dentistry, since all the patients included in this study are elders (50 years and older) and in need of periodontal treatment.

In studies investigating the prevalence of CAC on panoramic radiographs, different prevalence rates have been reported (5.06% - 41%). This difference in CAC prevalence among studies is thought to be influenced by gender, age, lifestyle and ethnicity. Hubar et al. found the CAC prevalence to be 0.43% in their study where they evaluated 700 patients. However, the individuals included in this study were aged 50 and over, and in the mentioned study, the individuals were aged between 14 and 77 years. The dramatic difference between the two studies can be thought as due to age and racial differences [35]. In a CAC prevalence study on the Japanese over 80 years of age, this rate was found to be 5% [18]. When a comparison was made between smoking women and men, it has been reported that men had a higher risk of stroke and were at more risk than non-smokers [10]. The fact that habits such as smoking and diet were not evaluated in this study may be among the limitations of the study. In a study conducted by Sisman et al. on the panoramic radiographs of 750 patients aged over 40 in the Cappadocia region, CAC prevalence was reported to be 5.06% (3.46% unilateral, 1.6% bilateral). In addition, it was reported that there was no statistically significant difference between men and women in terms of the incidence of CAC [36]. It was determined that there was no statistically significant difference between the women and men participating in this study in terms of age difference and CAC prevalence. In this regard, the results of this study were found to be consistent with the study of Sisman et al., but the difference in prevalence rates could be explained by the age difference of the individuals included in the study and that the individuals specifically had periodontal disease. In addition, the fact that the incidence of unilateral CAC (11.01%) was higher than the incidence of bilateral CAC (5.7%) in this study was evaluated as a result consistent with the above-mentioned study and other studies in the literature [36,37]. However, there are also studies in the literature indicating that the incidence of bilateral CAC is higher [30].

When evaluated according to the location, it was observed that the CACs detected on the left side were statistically significantly higher than the right side in this study. However, Ertas and Sisman reported no statistical difference between the right and left regions [30]. Pornprasertsuk-Damrongsri and Thanakun stated that 14 of the 34 CACs were on the left, while 11 were on the right and both were unilateral, but they did not make a statistical evaluation of the difference between the regions [38]. In another study, the incidence of CAC on the right side was reported to be higher [36]. It is detected that there is no consensus in the literature about the location. There is no information in the literature about the reasons of the occurrence in the right and left regions.

The systemic conditions of the individuals included in the study and the fact that the relationship between the periodontal clinical-radiographic parameters (gingival index, bleeding, probing, probing, clinical attachment levels, alveolar bone loss, etc.) were not evaluated can be considered as the limitations of this study.

## V. CONCLUSION

In recent years, news have been published on press reports regarding the detection of CAC by dentists who frequently use panoramic radiographs; however, many dentists and particularly experts of periodontology, which is one of the surgical branches of dentistry, do not have the information on how to interpret these radiographs. In panoramic radiographs frequently used in dentistry, the periodontist should examine carefully not only the structures that form the periodontium, but also the adjacent anatomical structures. It is important in terms of health policies that there is no need for an additional cost for this early diagnosis. It is of utmost importance that periodontists or dentists direct patients, in whom CAC is detected in panoramic radiographs, to the cardiology department for further investigations in terms of reducing the risk of stroke. More prospective clinical studies are needed to better understand the relationship between periodontal disease and CAC.

## REFERENCE

- [1]. Al-Ghutaimel H, Riba H, Al-Kahtani S, Al-Duhaimi S. Common Periodontal Diseases of Children and Adolescents. *Int J Dent.* 2014;2014:1-7.
- [2]. Pihlstrom BL, Michalowicz BS, Johnson NW. Periodontal diseases. *Lancet.* 2005;366(9499):1809-20.
- [3]. Highfield J. Diagnosis and classification of periodontal disease. *Aust Dent J.* 2009;54:S11-26.
- [4]. Zeng X-T, Deng A-P, Li C, Xia L-Y, Niu Y-M, Leng W-D. Periodontal Disease and Risk of Head and Neck Cancer: A Meta-Analysis of Observational Studies. Hoque MO, editor. *PLoS One.* 2013;8(10):e79017.
- [5]. Bascones-Martínez A, González-Febles J, Sanz-Esporrín J. Diabetes and periodontal disease. Review of the literature. *Am J Dent.* 2014;27(2):63-7.
- [6]. Corbella S, Taschieri S, Francetti L, De Siena F, Del Fabbro M. Periodontal disease as a risk factor for adverse pregnancy outcomes: a systematic review and meta-analysis of case-control studies. *Odontology.* 2012;100(2):232-40.
- [7]. Lafon A, Pereira B, Dufour T, Rigouby V, Giroud M, Bèjot Y, et al. Periodontal disease and stroke: a meta-analysis of cohort studies. *Eur J Neurol.* 2014;21(9):1155-e67.
- [8]. Kelly JT, Avila-Ortiz G, Allareddy V, Johnson GK, Elangovan S. The association between periodontitis and coronary heart



- disease: a quality assessment of systematic reviews. *J Am Dent Assoc.* 2013;144(4):371–9.
- [9]. Leng W-D, Zeng X-T, Kwong JSW, Hua X-P. Periodontal disease and risk of coronary heart disease: An updated meta-analysis of prospective cohort studies. *Int J Cardiol.* 2015;201:469–72.
- [10]. Peters SAE, Huxley RR, Woodward M. Smoking as a Risk Factor for Stroke in Women Compared With Men. *Stroke.* 2013;44(10):2821–8.
- [11]. Peters SAE, Huxley RR, Woodward M. Diabetes as risk factor for incident coronary heart disease in women compared with men: a systematic review and meta-analysis of 64 cohorts including 858,507 individuals and 28,203 coronary events. *Diabetologia.* 2014;57(8):1542–51.
- [12]. Lusis AJ. Atherosclerosis. *Nature.* 2000 Sep 14 [cited 2018 Nov 6];407(6801):233–41.
- [13]. Ross R. Atherosclerosis — An Inflammatory Disease. Epstein FH, editor. *N Engl J Med.* 1999;340(2):115–26.
- [14]. Guzmán D, Concha X, Rudolph M, Guzmán. C. Aporte preventivo de Accidente Vascular Encefálico en Pacientes Sometidos a Exámenes Radiográficos en la Región Maxilofacial. *Rev Dent Chile.* 2007;99(3):34–41.
- [15]. Chicano R, Sánchez R, Castaño F, Merino M, López F. La Ortopantomografía como método para la detección de las placas de ateroma calcificadas. Revisión de la literatura. *Med Oral, Patol Oral y Cirugía Bucal [Internet]. Medicina Oral Place of publication not identified; 2006;11(3):167–73.*
- [16]. Aarabi G, Eberhard J, Reissmann DR, Heydecke G, Seedorf U. Interaction between periodontal disease and atherosclerotic vascular disease – Fact or fiction? *Atherosclerosis.* 2015;241(2):555–60.
- [17]. Beck JD, Elter JR, Heiss G, Couper D, Mauriello SM, Offenbacher S. Relationship of periodontal disease to carotid artery intima-media wall thickness: the atherosclerosis risk in communities (ARIC) study. *Arterioscler Thromb Vasc Biol.* 2001;21(11):1816–22.
- [18]. Ohba T, Takata Y, Ansai T, Morimoto Y, Tanaka T, Kito S, et al. Evaluation of calcified carotid artery atheromas detected by panoramic radiograph among 80-year-olds. *Oral Surg Oral Med Oral Pathol Oral Radiol Endod.* 2003;96(5):647–50.
- [19]. Tugnait A, Clerehugh D V, Hirschmann PN. Survey of radiographic practices for periodontal disease in UK and Irish dental teaching hospitals. *Dentomaxillofac Radiol.* 2000;29(6):376–81.
- [20]. Mol A. Imaging methods in periodontology. *Periodontol 2000.* 2004;34:34–48.
- [21]. Tugnait A, Clerehugh V, Hirschmann PN. The usefulness of radiographs in diagnosis and management of periodontal diseases: a review. *J Dent.* 2000;28(4):219–26.
- [22]. Friedlander AH, Lande A. Panoramic radiographic identification of carotid arterial plaques. *Oral Surg Oral Med Oral Pathol.* 1981;52(1):102–4.
- [23]. Biermann E. Harrison's Principles of Internal Medicine. 13a ed. Isselbacher KJ, editor. Mc Graw- Hill; 1994. 1106-1116 p.
- [24]. Almog DM, Tsimidis K, Moss ME, Gottlieb RH, Carter LC. Evaluation of a training program for detection of carotid artery calcifications on panoramic radiographs. *Oral Surgery, Oral Med Oral Pathol Oral Radiol Endodontology.* 2000;90(1):111–7.
- [25]. Friedlander AH, Dounis G, Gratt BM. Lateral cephalometric radiographs: an aid in detecting patients at risk of stroke. *J Am Dent Assoc.* 1996;127(12):1745–50.
- [26]. Tonetti MS, Van Dyke TE. Periodontitis and atherosclerotic cardiovascular disease: consensus report of the Joint EFP/AAP Workshop on Periodontitis and Systemic Diseases. *J Clin Periodontol [Internet]. Wiley/Blackwell (10.1111); 2013;40:S24–9.*
- [27]. Friedlander AH. Identification of stroke-prone patients by panoramic and cervical spine radiography. *Dentomaxillofac Radiol.* 1995;24(3):160–4.
- [28]. Kumagai M, Yamagishi T, Fukui N, Chiba M. Carotid artery calcification seen on panoramic dental radiographs in the Asian population in Japan. *Dentomaxillofac Radiol.* 2007;36(2):92–6.
- [29]. Beckstrom BW, Horsley SH, Scheetz JP, Khan Z, Silveira AM, Clark SJ, et al. Correlation between carotid area calcifications and periodontitis: a retrospective study of digital panoramic radiographic findings in pretreatment cancer patients. *Oral Surgery, Oral Med Oral Pathol Oral Radiol Endodontology.* 2007;103(3):359–66.
- [30]. Ertas ET, Sisman Y. Detection of incidental carotid artery calcifications during dental examinations: Panoramic radiography as an important aid in dentistry. *Oral Surgery, Oral Med Oral Pathol Oral Radiol Endodontology.* 2011;112(4):e11–7.
- [31]. Mack F, Mojon P, Budtz-Jørgensen E, Kocher T, Splieth C, Schwahn C, et al. Caries and periodontal disease of the elderly in Pomerania, Germany: results of the Study of Health in Pomerania. *Gerodontology.* 2004;21(1):27–36.
- [32]. Locker D, Leake JL. Periodontal attachment loss in independently living older adults in Ontario, Canada. *J Public Health Dent.* 1993;53(1):6–11.
- [33]. Papapanou PN, Wennström JL. Radiographic and clinical assessments of destructive periodontal disease. *J Clin Periodontol.* 1989;16(9):609–12.
- [34]. Løe H, Anerud A, Boysen H, Morrison E. Natural history of periodontal disease in man. Rapid, moderate and no loss of attachment in Sri Lankan laborers 14 to 46 years of age. *J Clin Periodontol.* 1986;13(5):431–45.
- [35]. Hubar JS. Carotid artery calcification in the black population: a retrospective study on panoramic radiographs. *Dentomaxillofac Radiol.* 1999;28(6):348–50.
- [36]. Sisman Y, Ertas ET, Gokce C, Menku A, Ulker M, Akgunlu F. The Prevalence of Carotid Artery Calcification on the Panoramic Radiographs in Cappadocia Region Population. *Eur J Dent. Dental Investigations Society; 2007;1(3):132–8.*
- [37]. Magat G, Tuncdemir A. Assessment of Calcified Carotid Artery Plaques on Digital Panoramic Radiographs of Middle-aged and Older Asymptomatic Persons in a Turkish subpopulation and Associated Risk Factors. *Iran Red Crescent Med J. Kowsar; 2018;In Press(In Press).*
- [38]. Pornprasertsuk-Damrongsri S, Thanakun S. Carotid artery calcification detected on panoramic radiographs in a group of Thai population. *Oral Surgery, Oral Med Oral Pathol Oral Radiol Endodontology.* 2006;101(1):110–5.

Assist. Prof. Hacer Sahin "The Prevalence of Carotid Artery Calcifications in Periodontology Clinics in Eastern Turkish Population "Quest Journals Journal of Medical and Dental Science Research 5.6 (2018): 01-06