



Research Paper

## Cytomorphological Pattern of Lymph Node Lesions in Tertiary Care Hospital: Retrospective Study of 883 Cases.

Dr. Priya.R<sup>1</sup>, Dr. Sarada.V<sup>2</sup>

<sup>1</sup>Assistant Professor, <sup>2</sup>Professor and HOD, Department of Pathology, Trichy SRM Medical College Hospital & Research Centre, Trichy, 621105, Tamil Nadu, India.

Corresponding Author: Dr. Priya.R, Assistant Professor, Department of Pathology, Trichy SRM Medical College Hospital and Research Centre, Trichy, 621105, Tamil Nadu, India.

### ABSTRACT:

**Introduction:** Lymphadenopathy is one of the frequently encountered clinical presentation among all age groups attending the outpatient department. FNAC is considered as a simple, safe, rapid, reliable and cost effective procedure for diagnosing lymphadenopathy cases with a high degree of precision. **Objective:** 1. To study the age group, sex distribution, site and side predilection of various lymph node lesions. 2. To study the cytomorphological pattern of lymph node lesions. 3. To Categorize the various lymph node lesion into Non-neoplastic and Neoplastic. **Materials and Methods:** The present study is a retrospective study done at Trichy SRM Medical College Hospital from January 2016 to January 2021 and includes 883 cases of lymph node lesions. All the patients referred to the Department of Pathology, TSRM medical college hospital with palpable lymph node were included in the study. FNAC was done and standard procedure was adopted. Clinical and Cytomorphological details were recorded, analysed and compiled. **Results:** A total of 883 patients were included in the present study. A maximum number of cases were in the 3<sup>rd</sup> decade in benign lesions whereas 4<sup>th</sup> and 6<sup>th</sup> decade in case of Metastatic lesions. Our study showed female preponderance (54.2%). Cervical group of lymph node was most commonly involved in both benign and metastatic lesions. Benign lymphadenopathies were diagnosed in 695 cases (78.7%), maximum being Tuberculous lymphadenitis (38.4%). Neoplastic lesions were reported in 188 cases, maximum being metastatic lymphadenitis diagnosed in 160 cases (1%). **Conclusion:** FNAC is safe, simple, reliable and cost effective diagnostic procedure with minimal trauma to contribute a prompt diagnosis for lymph node lesions, especially in lymph node aspirate where biopsies are not done routinely.

**KEYWORDS:** FNAC, Lymph node, Neoplastic, Non neoplastic and Metastatic.

Received 29 June, 2021; Revised: 11 July, 2021; Accepted 13 July, 2021 © The author(s) 2021.

Published with open access at [www.questjournals.org](http://www.questjournals.org)

### I. INTRODUCTION

Lymph nodes are small, oval or kidney shaped structures measuring 0.1 to 2.5 cm, lying along the course of lymphatic vessels and it develops from lateral part of mesoderm [1,2]. The main function of a lymph node includes lymphocyte production, biological filtration of lymphatic fluid, processing of antigen and presenting it to the receptor through antigen presenting cells [3]. Human body consists of more than 1000 lymph nodes and most of them are usually non-palpable in healthy individuals [4]. The commonest sites of distribution of lymph nodes are cervical, axillary, Inguinal, Iliac, mediastinal and retroperitoneal regions.

In the 15<sup>th</sup> century, Syringes were introduced to aspirate the fluid and it was available for usage since from 1830 [5]. Later, Greg and Gray diagnosed trypanosomiasis in patient suffering from sleeping sickness while doing a cervical lymph node aspirate [6]. In India, FNAC was introduced by Dr. Sukumaran in south madras during 1970's.

Nowadays, FNA is one of the important diagnostic procedure to find out the causes for Lymphadenopathy. The main reasons are easiest procedure to carry out, early availability of results, reliability and better patient compliance with minimal invasion. [7,8,9].

Lymphadenopathy is defined as any abnormal increase in size, number or consistency of lymph node. Lymph node enlargement may be generalized or localised [10]. To say significant lymphadenopathy, there should be either increase in size of more than 1 cm. It should be either firm or hard, well defined or ill

defined[11,12].The various etiological factors for lymphadenopathy are broadly classified as Iatrogenic, Infectious, Autoimmune and Malignancy[13].

The general approach for lymphadenopathy includes clinical evaluation,Fine needle aspiration cytology and excision biopsy[14].FNAC is simple, safe, rapid and inexpensive procedure, which could be carried out as an outpatient diagnostic procedure[14].It is a primary method for diagnosing the causes of lymphadenopathy and thereby, avoiding unnecessary biopsy and aiding earlier clinical management [15].

## II. AIMS AND OBJECTIVES:

- 1.To study the age group, sex distribution, site and side predilection of various lymph node lesions.
2. To study the cytomorphological pattern of lymph node lesions.
3. To Categorize the various lymph node lesion into Non-neoplastic and Neoplastic.

## III. MATERIALS AND METHODS

**Setting:** Department of Pathology, Trichy SRM Medical College Hospital and Research Centre, Trichy.

**Duration:** January 2016 to January 2021

**Type of study:** Retrospective study

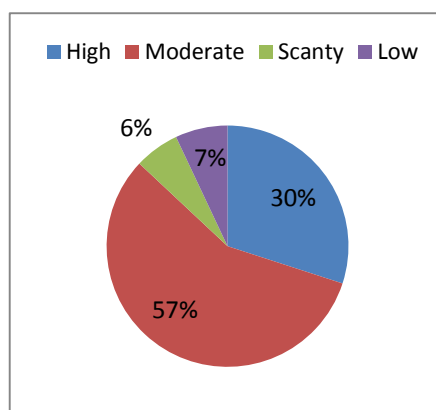
**Inclusion criteria:** The aspirate from the patient presenting with lymphadenopathy were included in the study.

**Exclusion criteria:** The smear which are hemorrhagic, Scanty cellular smear which were labelled as inadequate for opinion, were excluded.

**Data collection procedure:** All patients presenting with lymphnode enlargement were included in the study. FNAC was performed using 22- 24 Gauge needles attached to 10 ml syringe. The aspirated material was smeared on to glass slides. Smears was fixed in Isopropyl alcohol and stained with PAP stain and hematoxylin & Eosin. Air dried smears were stained with MayGrunwald Giemsa(MGG) stain and slides were examined under microscopy. Cytomorphological details were recorded, Data were plotted and statistical analysis was carried out with the help of SPSS 21.

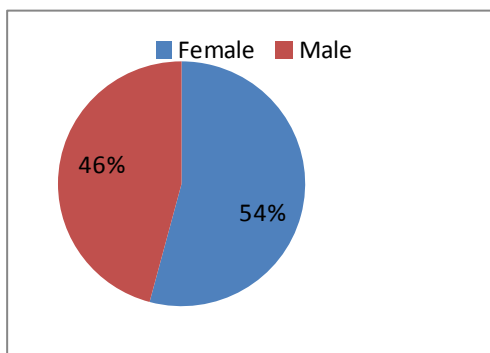
## IV. OBSERVATION AND RESULT:

During this study period, A total of 883 aspirates were obtained from the patient with lymphadenopathy.. In the present study almost 870 cases presented with significant lymphadenopathy and 13 cases presented with size of node less than 1 cm. The current study showed 49.87% of cases with firm lymph node and 22.4% of cases showed hard lymphnodes and most of the neoplastic cases presented with hard lymphnodes. In the current study, we observed that 56% of smear showed moderate cellularity followed by high cellular smear with an occurrence of 30 % of cases (Fig 1).



**Fig-1: Showed Cellularity Of Lymphnode Aspirates.**

The age of the patients varied from 7 to 79 years with a mean age of 28 years. The maximum incidence of cases occurs in age group of 20-30 years. Among 883 cases, 479 cases (54.2%) were females and 404 cases (45.8%) were males. A female preponderance were noted with a male female ratio of 0.8:1.The female preponderance was high in 3<sup>rd</sup> decade whereas male preponderance were noted in 5<sup>th</sup> and 6<sup>th</sup> decade. Fig 2 showed sexwise distribution of lymphnode cases.(Table 1) showed age and sexwise distribution of cases.



**Fig-2: Showed Sexwise Distribution Of Lymphnode Lesions**

**Table 1: Showed Age and Sexwise Distribution Of Cases.**

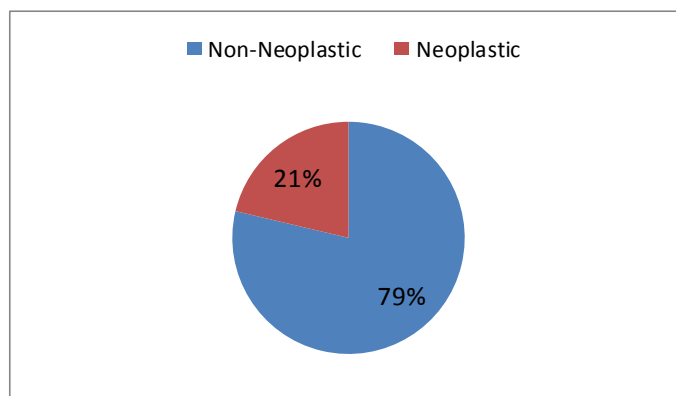
Age group	Male	Female	No of Cases	Percentage
0-10 yrs	43	21	64	7.2
10-20 yrs	60	97	157	17.8
20-30 yrs	77	143	220	24.9
30-40 yrs	59	88	147	16.6
40-50 yrs	37	70	107	12.2
50-60 yrs	66	36	102	11.5
60 -70 yrs	53	9	62	7.1
70-80 yrs	9	15	24	2.7

The most common group of lymphnode involved in our study was cervical 81.2% followed by axillary group of lymphnode in 6.3% cases and bilateral involvement in 39 cases.

**Table 2: Showed Site and Side of Lymphnode Group Involved In Various Lymphnode Lesions.**

Site	Right	Left	Bilateral	Total	Percentage
Cervical	280	405	32	717	81.2
axillary	22	31	3	56	6.3
Submandibular	13	24	-	37	4.2
supraclavicular	8	23	2	33	3.7
Inguinal	19	12	1	32	3.6
Multiple	3	4	1	8	0.9
<b>Total</b>	<b>345</b>	<b>499</b>	<b>39</b>	<b>883</b>	<b>100</b>

Among 883 cases, 695 cases(78.7%) were Non-Neoplastic lesions and 188 cases(21.3%) were Neoplastic lesions(Fig-3). Non-Neoplastic lesions were commonly seen in 3<sup>rd</sup> decade and Neoplastic lesions were seen in 4<sup>th</sup> and 6<sup>th</sup> decade(Table-3).



**Fig-3: Showed Cytomorphological Pattern Of Lymphnode Lesions.**

**Table 3 :Agewise Distribution Of Lymphnode Lesions.**

Age group	Non-Neoplastic	Neoplastic	Total	Percentage
0-10 yrs	60	4	64	7.2
10-20 yrs	151	6	157	17.8
20-30 yrs	216	4	220	24.9
30-40 yrs	122	25	147	16.6
40-50 yrs	62	45	107	12.2
50-60 yrs	61	41	102	11.5
60-70 yrs	17	45	62	7.1
70-80 yrs	6	18	24	2.7
<b>Total</b>	<b>695</b>	<b>188</b>	<b>883</b>	<b>100</b>

Among Non-Neoplastic lesions (695 cases), the most common cytological diagnosis made was Tuberculous lymphadenitis in 263 cases( 37.8% ) followed by reactive lymphadenitis in 168 cases(24.1%)and both lesions are common in 3<sup>rd</sup> decade.

**Table 4: Showed Cytomorphological Pattern Of Non-Neoplastic Lesions of Lymphnode**

Non-Neoplastic lesions	0-10	10-20	20-30	30-40	40-50	50-60	60-70	70-80	Total	Percentage
<b>Tuberculous lymphadenitis</b>	10	62	83	58	24	20	6	-	<b>263</b>	<b>37.8</b>
<b>Reactive lymphadenitis</b>	29	40	50	18	8	18	5	-	<b>168</b>	<b>24.1</b>
<b>Granulomatous lymphadenitis</b>	10	22	49	17	18	16	9	-	<b>141</b>	<b>20.2</b>
<b>Chronic lymphadenitis</b>	7	13	17	7	7	4	-	1	<b>56</b>	<b>8</b>
<b>Suppurative lymphadenitis</b>	2	7	14	20	2	-	-	-	<b>45</b>	<b>6.5</b>
<b>Necrotizing lymphadenitis</b>	2	5	6	2	3	2	-	-	<b>20</b>	<b>2.9</b>
<b>Others(Rosai Dorfmann Disease)</b>	-	-	-	2	-	-	-	-	<b>2</b>	<b>0.3</b>
<b>Total</b>	<b>60</b>	<b>149</b>	<b>219</b>	<b>124</b>	<b>61</b>	<b>60</b>	<b>20</b>	<b>1</b>	<b>695</b>	<b>100</b>

A total of 188 cases were diagnosed as Neoplastic lesions, Out of which Non Hodgkin's lymphoma was diagnosed in 13 cases(1.5%),Hodgkin's lymphoma was diagnosed in 15cases(1.7%) and 160 cases were diagnosed as metastatic malignancy(18.1%) [Table:5].

**Table 5: Showed Cytomorphological Pattern of Neoplastic Lesions of Lymphnode**

Neoplastic lesions	No of cases	Percentage
Hodgkin's lymphoma	15	7.9
Non-Hodgkin's lymphoma	13	6.9
Metastatic lymphadenitis	160	85.1
<b>Total</b>	<b>188</b>	<b>100</b>

Among 160 cases of metastatic lymphadenitis, maximum cases being metastatic deposits of squamous cell carcinoma 74 cases(46.2%) followed by adenocarcinoma 48 cases(0.3%). A marked male preponderance was noted with a maximum number of cases in the cervical group of lymphnode followed by supraclavicular lymphnode.

**Table 6: Showed Cytomorphological Distribution of Metastatic Lymphadenitis**

<b>Metastatic lymphadenitis</b>	<b>0-10</b>	<b>10-20</b>	<b>20-30</b>	<b>30-40</b>	<b>40-50</b>	<b>50 -60</b>	<b>60-70</b>	<b>70-80</b>	<b>Tot al</b>	<b>%</b>
Metastatic deposit - squamous cell carcinoma	-	-	-	10	16	18	20	10	<b>74</b>	<b>46.2</b>
Metastatic deposit- Adenocarcinoma	-	-	-	8	14	13	13	-	<b>48</b>	<b>0.3</b>
Metastatic deposit- Carcinoma of Thyroid	-	-	-	5	10	3	5	5	<b>28</b>	<b>0.18</b>
Metastatic deposit- ductal carcinoma of breast	-	-	-	-	2	2	2	-	<b>6</b>	<b>0.04</b>
Metastatic deposit- poorly differentiated	-	-	-	-	-	-	2	-	<b>2</b>	<b>0.01</b>
Metastatic deposit- Malignant melanoma	-	-	-	-	-	-	2	-	<b>2</b>	<b>0.01</b>
<b>Total</b>	-	-	-	<b>23</b>	<b>42</b>	<b>36</b>	<b>44</b>	<b>15</b>	<b>160</b>	

## V. DISCUSSION:

The causes for lymphadenopathy is broadly classified as Inflammatory, Infectious, Autoimmune and Malignancy. Among the different group of lymphnode, cervical group is easily accessed by FNAC and therefore it plays a major role in obtaining the diagnosis[16].The surgical excision of lymphnode is simple but the procedure requires anaesthesia exposure, Sterile instruments and operation theatre.FNAC is simple, safe, reliable, inexpensive method and plays a major role in diagnosing the etiology of lymphnode enlargement due to early availability of results, better patient compliance with minimal trauma[17,18].

In the current study, Out of 883 cases, we observed that maximum cases were recorded between the age group of 21 to 30 years. Non-neoplastic lesions were common in the 3<sup>rd</sup> decade whereas metastatic lesions were more common in 4<sup>th</sup> and 6<sup>th</sup> decade. Our study is correlated with the study conducted by other authors Prabhakar Patro et al [19] , Smita et al[20] and Kumar et al[21].This study shows that majority of lesions were found in women, with male female ratio is 0.8:1. This is concordance with study done by Sharma et al [22], Duraiswami et al[23] and Nidhi et al[24] with male female ratio Of 0.87:1, 1:1.6 and 1:1.4 respectively.

The most common group of lymph node involved in our study is cervical region of lymphnode(81.2%) which is concordance with study conducted by Uma et al [25] with 62.9% cases, Pavithra et al [26] and Mohanty et al[27].Left sided lymphnode lesions were most commonly involved in both Neoplastic and Non-Neoplastic with an occurrence of 56% whereas right sided lesions had an occurrence of 39.1%. Hence our study is concordance with study conducted by Attaullah et al[28].

The incidence of Non-Neoplastic lesions in our study was 695 cases(78.7%) and Neoplastic lesions was 188 cases(21.3%).Hence our study was concordance with study conducted by Maria et al [29] reported 77% of Non neoplastic lesions and 23% of Neoplastic lesions, Neha singh et al[30] reported 90% of Non neoplastic lesions and 10% of Neoplastic lesions.

Cytomorphological patterns obtained in this study were predominantly Non-Neoplastic. Among Non-Neoplastic lesions, Tuberculous lymphadenitis was the most common pattern with an occurrence of 263 cases(29.8%), followed by reactive lymphadenitis 168 cases(1.9%) and Metastatic lymphadenitis in 160 cases(18.1%). The next commonest Non-Neoplastic lesions in our study are Granulomatous lymphadenitis(141 cases).

In developing countries like India, the most commonest causes for lymphadenopathy includes Tuberculosis, Acute respiratory infection and Suppurative lymphadenitis[31].The present study showed 263 out of 883 cases of lymphadenopathy were due to Tuberculous etiology.The main reasons is due to low socioeconomic status, Poverty, illiteracy, treatment resistance and defaulter. Cervical group of lymphnodes were more commonly involved by tuberculosis. Similar observations were made by Rajesh Kumar chaurasia et al[32], Pavithral et al[26],Chand et al[33] and Vimal et al[31].The cytomorphological pattern in tuberculous lymphadenitis can be divided into three patterns.

Granuloma without necrosis:In India, Mycobacterium tuberculosis is the most commonest causes for granulomatous lymphadenitis compared to other causes and hence the presence of granuloma is highly suggestive of tuberculosis.A total of 90 cases(34.2%) presented with granuloma without necrosisand among these 4 cases were AFB Positive. Most of these lesions were from the cervical and supraclavicular lymphnode.

Epithelioid granuloma with necrosis: Among 263 cases, 110 cases(41.8%) had presented with epithelioid granuloma with necrosis. AFB positivity is higher in this category and showed 10 cases AFB positivity, which is concordance with the other studies[31,34,35]. The main reason was due to compromised immune status or inadequate immune response.

Necrotic Material without granuloma:

A total 63 out of 263 cases(23.9%) had presented with necrosis alone and no granuloma made out. Necrotic material with polymorphonuclear infiltrate can be confused with Suppurative lesions. AFB Positivity is highest in this group and it is around( 12 cases)[36].

Among the Neoplastic lesions, Metastatic lymphadenitis were the commonest lesions, reported 160 cases(18.1%) which is concordance with study conducted by sharma et al[37], Patil et al[38], and Shilpa et al[39]. In our study the cervical group was the most common site to be involved by metastatic lesions followed by supraclavicular lymph node which is similar to the study conducted by Hirachand et al[40] and Singh et al[41]. The most common histological type in our study was squamous cell carcinoma 74 cases( 46.2% ) and the primary was most often from the oral cavity, which is concordance with the study conducted by Singh et al [41] and Kochhar et al [42] observed 75% and 83.78% respectively. The occurrence of metastatic adenocarcinoma in our study was about 48 cases( 0.3% ) and the primary was most often from carcinoma in stomach, colon and rectum. The incidence of metastatic thyroid carcinoma in our study was about 28 cases(0.17% ). In 3 cases of lymphadenopathy, Ultrasonogram revealed cystic areas admixed with solid area in lymph node which were diagnosed as metastasis from Papillary carcinoma of thyroid. Hence, our study is concordance with the study conducted by Kessler et al which concluded that cystic change in lymph nodes were highly suggestive of metastatic papillary carcinoma of thyroid.

The other cytological diagnosis in the present study was Hodgkin's lymphoma which was found in 15 cases(1.7%) and Non Hodgkin's lymphoma was found in 13 cases(1.5%) aspirates comparable with the study done by other workers Gayathri et al (43) Khajuria et al (44) ranged from 0.56% to 3.66%.

**Table 7: Showed Comparison Of Cytomorphological Features Of Present Study With Other Studies.**

S.NO.	Author's Name	Total no. of cases	Non Neoplastic Lesions						Neoplastic Lesions			Other %
			TB LN	Rea LN	Gran LN	Ch NS LN	Ac S LN	Nec LN	Met LN	HL	NHL	
1	Patel A.S. et al [45]	250	50.8	20.8	8.4	1.2	8.8	0.8	8.8	0	0.4	-
2	Gayathri et al [43]	1774	14.65	26.22	14.7	18.5	3.94	-	21.2	0.17	0.56	-
3	Khajuria et al [44]	656	52.3	37.2	-	-	1	-	3.8	0.8	1.2	0.15
4	Patil et al [38]	1478	40.06	37.2	-	-	4.2	-	16.4	0.4	1.6	2
5	Shilpa et al [39]	943	48.5	27.4	-	-	6.9	-	23.9	0.2	1.7	0.2
6	Sharma et al [37]	736	56.93	26.22	-	-	6.11	-	6.38	0.4	2.31	0.28
7	Present study	883	29.8	19	16	6.3	5.1	2.3	18.1	1.7	1.5	0.2

## VI. CONCLUSION:

In the present study tuberculous lymphadenitis is found to be the most common cause of lymphadenitis in India, while reactive lymphadenitis is the second most commonest causes for lymphadenopathy. Cervical group of lymph nodes are most commonly involved followed by axillary lymph nodes. FNAC is safe, simple, reliable and cost effective diagnostic procedure with minimal trauma to contribute a prompt diagnosis for lymph node lesions, especially in lymph node aspirate where biopsies are not done routinely.

## REFERENCES:

- MacLennan KA, Underwood JCE. General and systemic pathology. 3rd ed. London : Churchill Living stone; 2000. Chapter 22 Lymph nodes, thymus and spleen .pg.589-613.
- Neas John F. Langhams text book of embryology. Lymphatic system embryological development. 3rd edition. Newyork: Elseiver publications; 2004: pg 87-96 .
- Ioachim HL, Medeiros LJ, Rotech H. Ioachim's lymph node pathology, 4<sup>th</sup>edn, Philadelphia: Wolters Kluwer Lippincott Williams & Wilkins; 2009 .pg. 2-104.
- Pamra SR, Baily GV, Gupta SP, et al. Cervical lymphadenopathies- A study of 100 cases with peripheral lymphadenopathy. Indian Journal of Tuberculosis. 1987;20: 96-100.
- Marilyn Rosa. Fine-Needle aspiration biopsy: A Historical overview. Diagnostic cytopathology 2008; 36(11): 773-775.
- Frale WJ. Needle aspiration biopsy: past, present and future. Hum Pathol 1989; 20: 504-517
- Bocato MD, polyvalent fixative for staining of fine needle aspiration. Acta J cytol 1982; 29(14):647-648.
- Saika UN, Dev P, Jindal B, et al., Fine needle aspiration cytology in lymphadenopathy of HIV positive cases. AcetaCytol. 2001;45:589-592.
- Saboorian MH, Ashfaq R. The use of fine needle aspiration biopsy in the evaluation of lymphadenopathy. Semin Diagn pathol. 2001; 18(2):110-123.
- Ferrer R. Lymphadenopathy-The differential diagnosis and evaluation.. American Journal of Family physician. 1998; Oct.58 (6) : 1-

- 10.
- [11]. Ahmad I. Primary lymphadenopathy presentation and evaluation. *Specialist* 2011;8[4]:13.
- [12]. Henry P, Longo D. Harrison's principles of Internal Medicine. 16 thdn. New York : McGraw Hill. Enlargement of lymph nodes and spleen. 2005; pg. 343-348.
- [13]. Bazemore AW, Smucker DR. Lymphadenopathy and malignancy. *Am Fam Physician*.2010; vol 66:2103-10.
- [14]. Keith VE, Harsharan SK, Jerald GZ. Fine needle aspiration biopsy of lymph nodes in the modern era: reactive lymphadenopathies. *Pathol Case Rev* 2007; 12(1):27-35.
- [15]. Kline TS. Handbook of fine needle aspiration biopsy cytology. In: St Louis: CV Mosby; 1981.
- [16]. ElinasAlkuwari, Manon Auger. Accuracy of fine needle aspiration cytology of axillary lymph nodes in breast cancer patients: A study of 115 cases with cytologic-Histologic correlation. *CANCER(Cancer Cytopathology)* 2008;114(2):89-93
- [17]. Khajuria R, Goswami KC, Singh K, Dubey VK. Pattern of lymphadenopathy on fine needle aspiration cytology in Jammu.JKSci 2006;8:157-9
- [18]. Ahmad T, Naeem M, Ahmad S, Samad A, Nasir A. Fine needle aspiration cytology (FNAC) and neck swellings in the surgical outpatient. *JAMA* 2008;20:30-2.
- [19]. Patro P, Lad P, Hoogar MB et.al. Spectrum of lesions in lymph nodes- a cytological study. *Int J Health Sci Res.* 2018; 8(11):75-81.
- [20]. Smita. Bhide et al. Cytological Evaluation of Fine Needle Aspiration Cytology in Lymph node lesion. *JMSCR Volume 05 issue 08 August 2017: 26869-26876.*
- [21]. Kumar H, Chandanwale SS, Gore CR, Buch AC, Satav VH, Pagaro PM. Role of fine needle aspiration cytology in assessment of cervical lymphadenopathy. *Med J DY Patil Univ*2013;6:400-4.
- [22]. Sharma P, Rana S, Gill MK, Singh P, Satarkar RN,Kalhan S. Spectrum of lymph node lesions on cytology in rural Haryana: a retrospective analysis. *Int J Res Med Sci* 2015 May;3(5):1125-30.
- [23]. Duraiswami R, Margam S, Chandran P, Prakash A. Spectrum of pathologies on FNAC evaluation of peripheral lymph nodes at a tertiary care center in hyderabad: a retrospective study. *Int J Adv Med* 2017 Feb; 4(1): 27-33.
- [24]. Neha Singh, Abhishek Singh, Rashmi Chauhan, Preeti Singh, NidhiVerma. Fine needle aspiration cytology in evaluation of lymphadenopathy in pediatric age group: our experience at tertiary care centre. *International Journal of Contemporary Medical Research* 2016;3(5):1347-1351.
- [25]. Uma P. Lymph Node Lesions in Underserved Population of Andhra Pradesh: A Prospective Study. *Int J Sci Stud* 2015; 3(7):172-175.
- [26]. Pavithra P, Geetha JP. Role of fine needle aspiration cytology in the evaluation of the spectrum of lymph node lesions. *Int J Pharm Bio Sci.* 2014;5(4):377-84.
- [27]. Mohanty R, Wilkinson A. Utility of fine needle aspiration of lymph nodes. *IOSR J Dent Med Sci.* 2013 Jul-Aug;8(5):13-8.
- [28]. Attaullah M, Shah W, Pervez SN, Khan S, Jehan S, Rahim S. cytomorphological pattern of superficial lymphadenopathy. *Gomal J Med Sci* 2012; 12:197-200.
- [29]. Maria Christine Joy B. Tanteo, MD\*, Robert Dennis Garcia, md clinical profile and histopathologic diagnoses of childhoodperipheral lymphadenopathy: an mmc experience pidsp journal 2011 vol 12 no.2
- [30]. Neha Singh, Abhishek Singh, Rashmi Chauhan, Preeti Singh, NidhiVerma. Fine needle aspiration cytology in evaluation of lymphadenopathy in pediatric age group: our experience at tertiary care centre. *International Journal of Contemporary Medical Research* 2016;3(5):1347-1351.
- [31]. Vimal S, Dharwadkar A, Chandanwale SS, Vishwanathan V, Kumar H. Cytomorphological study of lymph node lesions: A study of 187 cases. *Med J DY Patil Univ* 2016;9:43-50.
- [32]. Gayathri MN, Chaurasia S, Bharathi M, Shashidhar HB. Pattern of lymphadenopathy in fine needle aspiration cytology: a retrospective study. *Int J Res Med Sci*2015;3:1416-9
- [33]. Chand P, Dogra R, Chauhan N, et al. Cytopathological Pattern of Tubercular Lymphadenopathy on FNAC: Analysis of 550 Consecutive Cases. *J Clin Diagn Res.* 2014 Sep;8(9):FC16-9. doi: 10.7860/JCDR/2014/9956.4910. Epub 2014 Sep 20.
- [34]. Narang RK, Pradhan S, Singh RP, Chaturvedi S. Place of fine needle aspiration cytology in the diagnosis of lymphadenopathy. *Indian J Tuberc* 1990;37:29-31.
- [35]. Verenkar MP, Kavita K, Pinto WM, Rodrigues S, Pinto RG. Mycobacterial study of fine needle aspirates in cervical lymphadenitis. *Indian J Tuberc* 1996;43:187-9.
- [36]. Finfer M, Perchick A, Burstein DE. Fine needle aspiration biopsy diagnosis of tuberculous lymphadenitis in patients with and without the acquired immune deficiency syndrome. *Acta Cytol* 1991;35:325-32.
- [37]. Sharma RI, Dharaiya CM. Study of fine needle aspiration cytology of lymphadenopathy in tertiary care centre of Ahmedabad, Gujarat. *Trop J Path Micro.* 2018; 4 (3):258-264. doi:10.17511/jopm.2018.i3.04
- [38]. Patil R. K, Anubrolu I. P, Kittur S. K, Haravi R. M, Aruna S, Jadhav M. N. Cytological spectrum of lymph node lesions-our institute experience. *Trop J Path Micro* 2017;3(3):354 361.doi:10.17511/jopm.2017.i3.22.
- [39]. Shilpa G, Nataraju G. Pattern of Lymph Node Diseases in a Tertiary Level Referral Center: a cytological study of 943 cases. *International Journal of Biological and Medical Research.* 2013;4(3):3448-52.
- [40]. Hirachand S, Lakhey M, Akhter J, et al. Evaluation of fine needle aspiration cytology of lymph nodes in Kathmandu Medical College, Teaching hospital. *Kathmandu Univ Med J (KUMJ).* 2009 Apr-Jun;7(26):139-42.
- [41]. Singh A, Bhambani P, Nema SK. Diagnostic accuracy of FNAC in diagnosis for causes of lymphadenopathy: a hospital based analysis. *Int J Res Med Sci* 2013 Aug;1(3):271-7.
- [42]. A Kochhar, G Duggal, K Singh, S Kochhar. Spectrum Of Cytological Findings In Patients With Lymphadenopathy In Rural Population Of Southern Haryana, India - Experience In A Tertiary Care Hospital. *The Internet Journal of Pathology.* 2012; 13(2) : 1-6.
- [43]. Gayathri MN, Chaurasia S, Bharathi M, Shashidhar HB. Pattern of lymphadenopathy in fine needle aspiration cytology: a retrospective study. *Int J Res Med Sci.*2015 Jun;3(6):1416-9.
- [44]. Khajuria R, Goswami KC, Singh K, Dubey VK. Pattern of lymphadenopathy on fine needle aspiration cytology in Jammu. *JK Sci.* 2006 Jul-Sep;8(3):157-9.
- [45]. Patel A.S, Rathod G.B, Shah K.J. Cytomorphological study of lymph node lesions: a study of 250 cases. *Trop J Path Micro* 2019;5(3):163-170.doi:10.17511/jopm.2019.i03.09.