



Research Paper

Ectopic mesenteric right kidney: An unusual and rare differential for mesenteric mass with literature review.

Mukoro Duke George¹, Lawan Suleiman²

1. Department of Surgery, Biu General Hospital, Borno State.

2. Division of Peri-operative Nursing care, Biu General Hospital, Borno State.

Authors contribution; Both are Authors of the manuscript, design, write-up and the surgical management.

Abstract;

Background

A few ectopic locations of the kidneys have been reported and some were even noted only in cadavers during autopsy. The etiology of ectopic positions still remains unclear although genetics, intrauterine infections, chemicals and substance abuse in pregnancy have been implicated in the arrest of the kidneys at ectopic locations. Our surgical finding was an unusual location of the ectopic right kidney in a living adult female. This Unique location would be the first to be reported in the literature for a living being.

Method;

Presentation of case report demonstrating surgically detected ectopic right kidney.

Case Report:

The index case was a very slim woman, who had a palpable abdominal mobile mass with recurrent non-specific symptoms and indeterminable ultrasonographic findings. An elective exploratory mini-laparotomy revealed the mesentery of the small intestine, incidentally, found to house the right kidney connected to its ureter and pedicles of blood supply, no further surgical manipulation was done. Further evaluation confirmed a functional right kidney through an intravenous pyelogram. The patient was prescribed antibiotics and analgesics.

Conclusion:

The case report calls for careful observation of ectopic organs during surgical sessions in order to prevent adverse surgical events due to poorly thought-out decisions.

Keywords: ectopic right mesenteric kidney, small intestinal mesentery, intravenous pyelogram

Received 06 Jan., 2022; Revised 17 Jan., 2023; Accepted 19 Jan., 2023 © The author(s) 2023.

Published with open access at www.questjournals.org

I. Introduction:

An ectopic kidney is a congenital defect in which a kidney or both are located in an abnormal position except its natural anatomical position. The occurrences of ectopic kidney depend on the location, with a range from 1:500 to 1:22,000; Some reports include ectopic thoracic kidney at 1:13000; solitary kidney at 1:1000; solitary pelvic kidney at 1:22000; one normal and one pelvic kidney at 1:3000; and crossed renal ectopia at 1:7000 [1].

People with an ectopic kidney usually have no complaints, however, a few cases may present with urinary problems, such as urine blockage, infection, or urinary stones. Anatomic reports of congenital Kidney includes horseshoe shape kidney[2], and un-ascended kidneys located at different level of the body beginning from the sacral region up to the upper lumbar region, sometimes, both may be on the same side often the right, sometimes both may be fused as well.

Arterial bands have been implicated in some un-ascended kidneys, others include environmental and genetic Factor[3]. The index case presents us with the first reported right functional kidney located within the wall of the mesentery of the small intestine.

CASE PRESENTATION;

Mrs UA, a 32-year-old housewife in North-eastern Nigeria, presented with an mobile localized which she had observed since childhood, with occasional right flank pain which was migratory. She had regular menstruation with post-flow dysmenorrhea. There was 3 months history of some abdominal fullness after meals, especially during menstruation periods. There was no history of recent hematuria or dysuria. On examination,

abdomen was scaphoid with a visible palpable mass measuring 10x6 cm, firm in consistency and mobile, not attached to overlying skin.

Investigations and Findings.

Ultrasound scan showed a 6x3 cm size mass in horizontal dimensions[FIGURE 1], Anechoic with no fluid collection, liver, and spleen were normal for age as well as no fluid in Pouch of Douglas with a non-gravid uterus. Widal test showed Salmonella

typhi D antigenemia with significant Sero-dilution titer at 1/160, while other antigens were 1/40 but Salmonella O Paratyphoid B antigen titer was 1/80.

The soft and brown Stool Microscopy showed Cyst of E.histolytica. She was seronegative to Hepatitis C, B Surface antigens, HIV 1 and 11 antigens. Urinalysis showed no significant finding but pH was 6 and specific gravity was 1.010. Her red blood cell volume was 38%. A provisional diagnosis of Intra-abdominal mass with unknown origin.

Figure 1; Ultrasonographic feature of a suspected right ectopic mesenteric kidney



Surgical Procedure and Findings.

She was booked for Mini-exploratory laparotomy with interval Appendectomy under total intravenous anesthesia with consent. The peritoneal cavity was approached through an infra-umbilical midline incision. The mass was located in the mesentery of the small intestine. There was no hematoma or fluid collection. The mass was exposed after a fairly loose sheet of the mesentery over the mass was opened[figure II]. There was a thin sheet of fat layer over a small portion of the surface of the mass. The multi-lobulated organ had tributaries of its main vessels diverging into the mass on its medial border(hilum)[fig II&III] and there was a tube-like structure (Ureter) running from the inferior-medial border to the root of the mesentery[figII]. A closer look showed that it was the right kidney while the renal gutter above was empty while the left kidney was located in the left renal gutter overlying the 12th rib[Fig V]. An interval Appendectomy was carried out after observing inflammation of the end of the vermiform appendix. The segment of the ileum where the mesentery sheet was incised was healthy and well vascularized, its wall physical architecture appears the same as other segments of the small intestine[fig IV]. The identified mass was termed ectopic right mesenteric Kidney, it was relocated into the infra-mesenteric space and the sheet closed. The abdominal wall was also closed, while a urethral catheter was secured for observation of the urine. Her post-operative period was uneventful. She produced light amber and clear urine at a rate of >30mls per day.

FIGURE II; Right kidney with bowel mesentery.

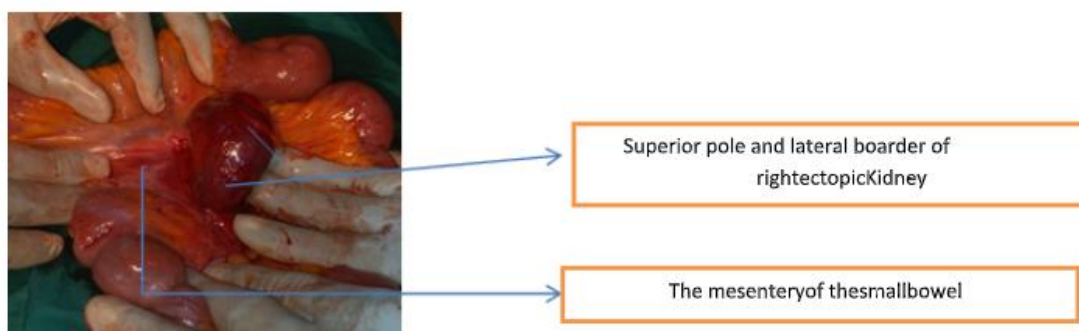


Figure III; Collecting Ureter of Ectopicright Kidney

Hilum of the right kidney with vascular bundles and branches entering the kidney mesenchyma.

Healthy small bowel and its mesentery.

Post-Operative care

Oral sips were commenced 6 hours after the operation and placed on doxycycline, Ofloxacin, Celecoxib, and Flagyl. An Intravenous Urogram was carried out by the radiographer; Results showed a non-dilated pelvicalyceal system of the right kidney located in the right lower quadrant of the abdomen, signifying that it was a functional right ectopic kidney [Fig VI]. Her post-operative period was uneventful; her blood pressure was 120/70 mmHg and her pulse rate was 96 beats per minute and was discharged after 6 days with counseling concerning the findings and report back if any symptom of concern appears.

Figure V; Renography of left side

Figure VI; Renography of the right side

II. Discussion:

An ectopic kidney is known as a birth defect where the kidney is located in an abnormal position, it may be one or both. During embryological development, both kidneys typically ascend to the lumbar region due to the differential growth of the abdominal wall. An ectopic location results from arrest during migration [3].

The development of the Kidney begins by 4th week of intrauterine life [2] and receives blood supply from the upper segment of the trunk aorta as it ascends up while the lower vascular supply degenerates [2]. The kidneys are known to pass through a fork formed by the umbilical arteries superiorly [4]. At the start of the ascent, the renal hilum faces anteriorly but with rotation of the kidney, the hilum becomes medial. The process of renal ascent must have been accomplished around the 10th week of intra-uterine life [5]. The cause of Ectopic kidneys includes genetic defects which may be associated with other defects in organ and process development, other causes may include intrauterine infection, illness, or substance and drug abuse during pregnancy [6]. A Thorough search of available articles showed that a mesenteric ectopic right kidney had not been reported. The surgical finding was incidental and fortunately functional as confirmed with the intravenous pyelogram [Fig V & VI]. Another report support contrast renogram as one investigative tool for ectopic kidneys [7].

Therefore surgeons have to be extra careful in identifying ectopic organs in theatre sessions and differentiate them adequately before making the decision to excise any undiagnosed intra-abdominal mass which may be unusual in structure or location as shown in our reported case. Congenital intra-abdominal masses may become visible as the patient becomes aware of his or her body while associating it with specific or non-specific signs and symptoms. A sound clinical history and examination are advised for a better diagnosis. Ultrasonography (Fig I) still remains one of the first lines of investigative tools for intra-abdominal mass such as ectopic kidney before Intravenous pyelogram (IVP), a media contrast CT [8] scan, Technetium-99 scintigraphy [9] or Radionuclide scan may also be advised. The tool that was helpful and diagnostic in our case was an intravenous pyelogram (renogram) [Fig V & VI]; which gave us a clue about the right kidney's function as well as the urine collecting system (pelvicalyceal system). Adjunct laboratory tests may include urinalysis, urine microscopy, and serum electrolyte urea and creatinine levels as a baseline. Thoughtful and careful return of the organ back to its' location was the decision due to the lack of super specialty services and resource-constrained setting, located in the insurgency-ravaged region of the country. The patient has been counseled adequately peradventure symptoms resurface so as visit a Renal Surgeon. The case report showed that investigative and diagnostic elective laparotomy was helpful in extremely unclear cases or in centers with limited pre-surgical diagnostic tools. The types of congenital presentation of the kidney and its collecting system that have been reported include; Absence of both kidneys, solitary kidney, supernumerary kidney, Hypoplastic kidney, True renal hypoplasia, Renal aplasia, Hypertrophic kidney, Long kidney, Short kidney, Broad kidney, Cystic kidney or Polycystic kidney which may be unilateral or bilateral Unilateral, Fused kidney, L-shaped kidney, Sigmoid kidney, Ring-shaped kidney ("engallette"), Symmetrical (Horseshoe kidney) with concavity above or below attached to a fibrous isthmus with or without some renal parenchyma [10]. The reported case is a unilateral right mesenteric kidney which was unique and had never been reported before. This report, therefore, is an addition to the knowledge of locations for an ectopic kidney. There could also be one to four renal pelvis and ureters. The location of the kidney may vary such as movable or floating kidney; or present

in lumbar, Iliac, Pelvic or Median positions. Rotation of the kidney may be excessive, or deficient, unilateral, or bilateral. The Excretory Apparatus of the Kidney (Calices, Pelvis, and Ureter): may be absent, aberrant, unusual in numbers, size, or position, in-perforated, diverticuled or magalated[10] . The single ureter seen in our case was short of its natural anatomical location and emanated from a pelvicalyceal that is tilted inferiorly and medially. According to Gutierrez[3], 40% of pathologic conditions of the urinary system are due to variations such as symptomatic posterior urethral valves in male infants and stones in ureter anomalies in adults. Urologic variations are found in 10% of vertebral variations, in 15% of meningocele or myelomeningocele, in 25% of the double anus, in 42% of duplication of the colon, 90% of duplication of genitalia.[11]. Our case showed some symptoms such as right flank pain which was specific to the urinary system and a clear mobile palpable mass was observed by the patient herself. The flank pain was due to inflammation possibly from infection. The Kidney's location in the mesentery is a very delicate position for overwhelming infections, therefore a location such as an ectopic right mesenteric kidney call for close monitoring, and preventive and prompt treatment of urinary and gastrointestinal infections. Ectopic or congenital un-ascended kidney has to be carefully differentiated from (acquired) nephroptosis where the length of the ureter is normal. The Ureter of our case was short even from the mesentery root. Symptoms due to the ectopic kidney may vary from none to pain; hydronephrosis, pyelonephritis, Reno-sigmoid fistulae or lithiasis[12] and In the case of females, the pelvic kidney may result in obstetric complications.[13]

Our patient was prompted to seek medical intervention due to the recurrent reported symptoms y. After treatment, post-operatively, she was advised not to hand-pick her organ as she had been doing prior to the presentation in our center. Treatment is mainly based on the functional capacity of the kidney; nephrectomy may be done on non-functional symptomatic kidney tissue or diseased kidney while corrective procedures should be the treatment of choice for the functional Symptomatic ectopic kidneys that are resistant to medical intervention. It is imperative to leave a functional non-symptomatic ectopic kidney alone without any intervention as observed in the reported case.

CONCLUSION

Ectopic kidneys are not so common and ectopic right mesenteric kidney is unusual, it was an incidental surgical finding in living person in contrast to many cadaveric reports.

References;

- [1]. Bergman R. A., Afifi A. K. and Miyauchi R. In: Illustrated Encyclopedia of human anatomic variation. opus IV: Organs system: Urinary system: Kidneys, ureters, bladders and urethra @ www/virtualhospital.com.
- [2]. Babu CSR, Sharma V, Gupta OP (2015) Renal Fusion Anomalies: A Review of Surgical Anatomy. *Anat Physiol* S5:001. doi:10.4172/2161-0940.S5-001
- [3]. Diaz G: Renal ectopy, report of a case of crossed ectopy without fusion, with fixation of the kidney in normal position by the extraperitoneal route. *J Int Coll Surg*, 1953; 19: 158–692.
- [4]. Hunziker M, Kutasy B, D' Asta F, Puri P: Urinary tract anomalies associated with high grade primary vesicoureteral reflux. *Pediatr Surg Int*, 2012; 28: 201–4
- [5]. Lin VC, Weng HC, Kian-Lim E et al: An atrophic crossed fused kidney with an ectopic vaginal ureter causing urine incontinence. *Urology*, 2010; 76: 55–56
- [6]. NIDDK, (June 2012) Ectopic Kidney, National Kidney and Urologic Diseases Information Clearinghouse, access 20/4/2018 <https://www.niddk.nih.gov/health-information/kidney-disease/children/ectopic-kidney>
- [7]. Haber, M. H. (1973) Bifid ureter with blind-ending branch diagnosed by excretory urography: Report of a case. *J. Urol.* 110: 38-39.
- [8]. Mittal MK, Sureka B, Mittal A, Sinha M, Thukral BB, et al. (2015) Congenital Anomalies of Kidney and Ureter. *Anat Physiol* 6: 190. doi:10.4172/2161-0940.1000190
- [9]. Prvulovich EM, Bomanji JB, Waddington WA, Rudrasingham P, Verbruggen AM, ElIPJ. (1997) Clinical evaluation of technetium-99m-L, L-ethylenedicysteine in patients with chronic renal failure. *J Nucl Med*. 1997 May; 38(5): 809-14. PMID: 9170451
- [10]. Gutierrez, R. (1936) Role of anomalies of kidney and ureter in causation of surgical conditions. *JAMA* 106: 183-189.

- [11]. Voigt HR, Wentzel SW. Completed duplication of the bladder, urethra and external genitalia in a male neonate with an imperforate anus. *Int J Urol*. 2005 Jul; 12(7):702-4. PMID: 16045569.
- [12]. Gray S.E. and Skandalakis J.E. *Embryology for surgeons - The embryological basis for the treatment of congenital defects*. W.B. Saunders Co. Philadelphia. London. Toronto. pp.472-474 (1972)
- [13]. Banner E.A. (1965): The ectopic kidney in obstetrics and gynaecology. *Surgery, Gynaecology and Obstetrics*. 121:32-36.