



Research Paper

## Epidermolytic Ichthyosis in a Female Child

Nurdini Wilda Salsabila\*<sup>1</sup>, Trisniartami Setyaningrum<sup>2</sup>, Iskandar Zulkarnain<sup>2</sup>,  
Sawitri<sup>2</sup>, Irmadita Citrashanty<sup>2</sup>, Yuri Widia<sup>2</sup>, Putri Hendria Wardhani<sup>2</sup>

<sup>1</sup> Resident of Dermatology and Venereology Department, Faculty of Medicine, Universitas Airlangga,  
Surabaya, Indonesia

<sup>2</sup> Lecture of Dermatology and Venereology Department, Faculty of Medicine, Universitas Airlangga,  
Surabaya, Indonesia

**Corresponding author:** Nurdini Wilda Salsabila, dr.

Resident of Department of Dermatology and Venereology, Faculty of Medicine, Universitas Airlangga  
Surabaya, Indonesia

### ABSTRACT

Epidermolytic ichthyosis (EI) is a rare keratinization disorder that is most commonly inherited in an autosomal dominant pattern. The prevalence of EI is reported to be about 1:100,000 to 400,000. EI presents at birth with generalized erythema, blisters, and erosions. In the months after birth, erythema and blistering decrease, while hyperkeratotic scaling that is especially prominent over the joints, neck, and dorsum of hands and feet increases. The diagnosis of EI is made clinically and can be confirmed by histopathology. A 10 year old female child with chief complain of thick scaling skin on almost all over her body since age of 3 years old. Scaly skin on face, palm, and sole were denied. Complain of thick scaly skin was also accompanied by multiple small erosions on her knee and instep. Initial lesions presence since birth. Lesions were said to be thin scaly skin and multiple saggy blisters that would easily break into multiple erosions. Foul odor complain since the scale become prominent and thicker. Dermatological examination showed brown corrugated and cobblestone hyperkeratotic plaques with multiple erosion on some areas. On her palmar manus and plantar pedis region showed normal skin. Histopathology examination showed extensive hyperkeratosis, some epidermal cells appear necrotic, accompanied by spongiosis on the epidermis and foci of lymphocytic cell infiltrate on the dermis. Patient was diagnosed with EI based on the clinical and histopathological examinations. Clinical improvement was observed after a one-month treatment with fucidic acid cream, urea 10% cream, vaselin album, and levertran ointment.

**Keywords:** Epidermolytic ichthyosis - Rare - Hyperkeratosis

Received 05 May, 2023; Revised 14May, 2023; Accepted 16 May, 2023 © The author(s) 2023.

Published with open access at [www.questjournals.org](http://www.questjournals.org)

### I. INTRODUCTION

Epidermolytic ichthyosis (EI, OMIM 113800) formerly known as epidermolytic hyperkeratosis is a rare keratinization disorder that is most commonly inherited in an autosomal dominant pattern, although spontaneous mutation represents about half of all cases with no family history (Putra, 2021). EI has many names, including bullous congenital ichthyosiform erythroderma, bullous congenital erythroderma ichthyosiformis of Brocq, bullous ichthyosiform erythroderma, and epidermolytic hyperkeratosis (Avril and Riley, 2016; Bygum et al., 2013). The prevalence of EI is reported to be about 1:100,000- 400,000 which affects both sexes equally (Achar et al., 2019).

Epidermolytic ichthyosis is caused by mutations in keratin (KRT) 1 or 10 genes. The defective KRT gene leads to skin fragility and blistering with erythrodermic clinical manifestations at birth. Hyperkeratosis and scaling will form as the severity decreases with age. Disease manifestations begin at or shortly after birth, with multiple erosions and blisters that decrease in occurrence and severity with age to give way to scaling and hyperkeratosis (Raddadi et al., 2018; Nellen, 2022)

Epidermolytic ichthyosis can be classified clinically based on the involvement of palmoplantar hyperkeratosis into either palm sole (PS) or no palm sole (NPS) subtypes. Another clinical classification is based on extent of skin involvement which divides EI into localized/linear (nevroid) and generalized forms. The

diagnosis of EI is usually made clinically and can be confirmed by the presence of typical histopathology (Putra et al., 2021; Alshami, 2016).

As there is no cure for epidermolytic ichthyosis, management involves symptom reduction (Lacz et al., 2005). Management of EI consists of emollients, hydration, and infection control in addition to keratolytics for hyperkeratotic skin. Family history and consanguinity screening should be done to clarify the diagnosis (Putra et al., 2021). Here we report a rare case of epidermolytic ichthyosis in a 10 years old female child, whose diagnosis was confirmed both clinically and by means of a biopsy. This case describes the clinical manifestation, diagnosis, and treatment of epidermolytic ichthyosis.

## **II. CASE REPORT**

A 10 year old female child came to Dermatology and Venereology Outpatient Clinic Dr. Soetomo General Hospital on August 9<sup>th</sup> 2022 with complain of thick scaling skin on almost all over her body which was felt since age of 3 years old. The scale is felt thicker on both elbow and knees. Scaly skin on face, palm, and sole were denied. Complain of thick scaly skin was also accompanied by multiple small erosions on her knee and instep.

According to her parents, the initial lesions before thick scaling was present since birth. Lesions were erythematous skin and one flaccid blister on her stomach which easily break and became erosion. Complaint of blister was only felt when the patient was born and since the age of 3 years old her skin became thickened. Complain of itchy, burning sensation, and pain were denied. Her parent also complaint of foul odor since the scale become prominent and thicker.

History of smearing with coconut and olive oil but the complains still persist. Patient went to dermatologist in Soewandhi Hospital for 6 years ago. Patient had x-ray and laboratory examination with normal result. Patient received moisturizer, mometasone cream, desoxsimetasone cream, fusidic acid cream, and loratadine as treatment.

History of drug and food allergy were denied. History of same complain in the family were denied. Patient is an only child and was born with the help of midwife with aterm pregnancy and immediately started crying. The birth body weight was 3000 grams and immunizations were complete for her age. Her mother was 25 years old and healthy during her pregnancy. There was no history of taking traditional medicine. The growth and development of the patient was normal.

Dermatological examination on her facialis region showed multiple hyperpigmented macules unsharply margined with thin scale on top of the macules. On thoracalis anterior, abdomen, and superior and inferior extremities region showed brown corrugated and cobblestone hyperkeratotic plaques with multiple erosion on some areas. On palmar manus and plantar pedis region showed normal skin (Figure 1).

We performed histopathology examination from a hyperkeratotic lesion on her right arm was performed using hematoxylin and eosin staining. The epidermis showed extensive hyperkeratosis, some epidermal cells appear necrotic, accompanied by spongiosis. The dermis showed foci of lymphocytic cell infiltrate. Conclusion from the histopathology is epidermolytic ichthyosis (Figure 2).

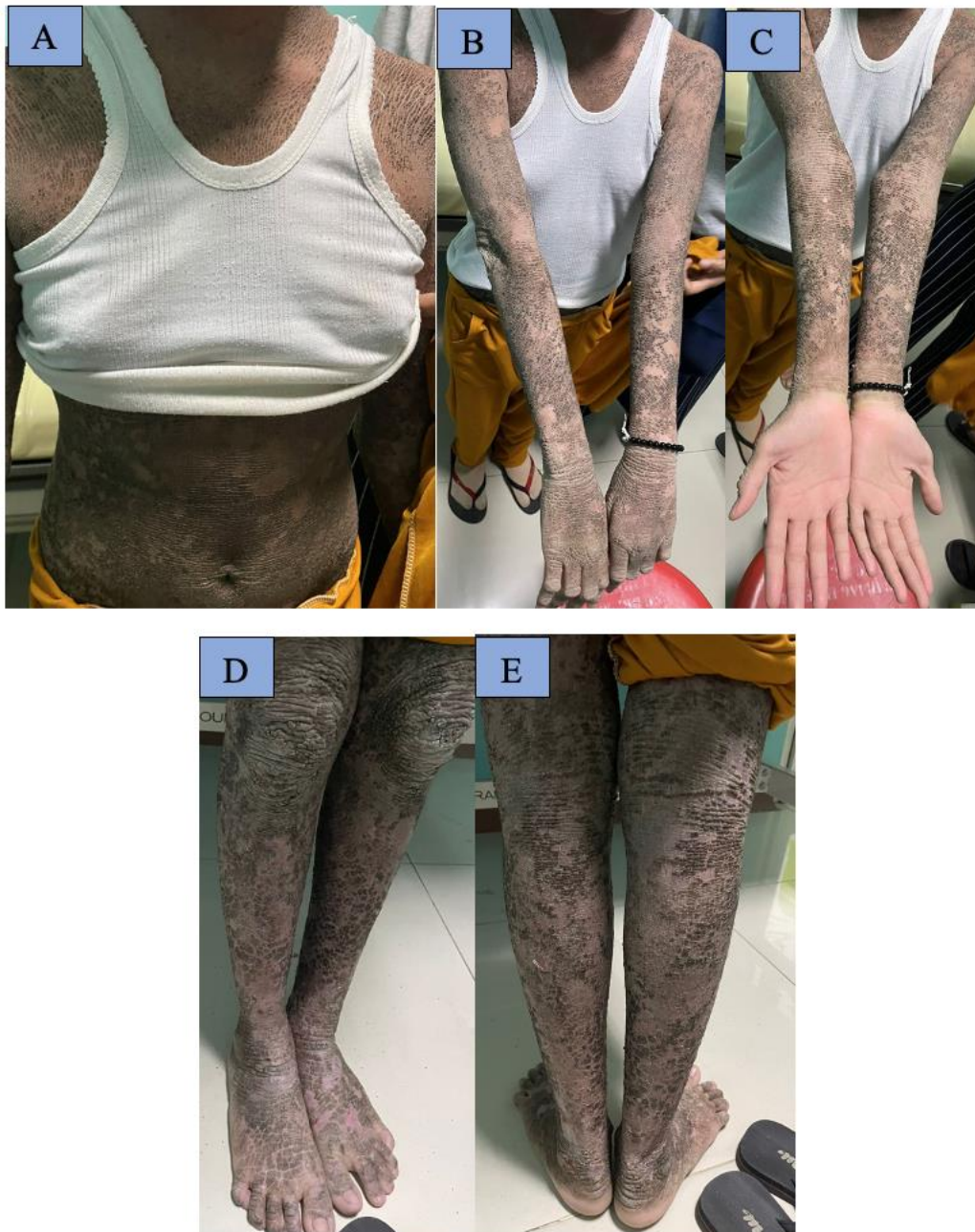

Figure 1. Dermatological examination. **A.** Brown corrugated and cobblestone hyperkeratotic plaques on thoracalis anterior region. **B, C.** Brown corrugated and cobblestone hyperkeratotic plaques on superior extremity, palmar manus region showed normal skin. **D, E.** Brown corrugated and cobblestone hyperkeratotic plaques on inferior extremity.

Patient was diagnosed with epidermolytic ichthyosis. Patient was treated with fusidic acid cream applied twice daily on the erosions, vaselin album applied twice daily on all over the body, urea 10% cream applied twice daily on all over the body, and levertrans ointment on patient's elbows and knees twice daily. We educate the patient about the cause of the disease, planning therapy and prognosis of the disease, and to not manipulate the lesion.

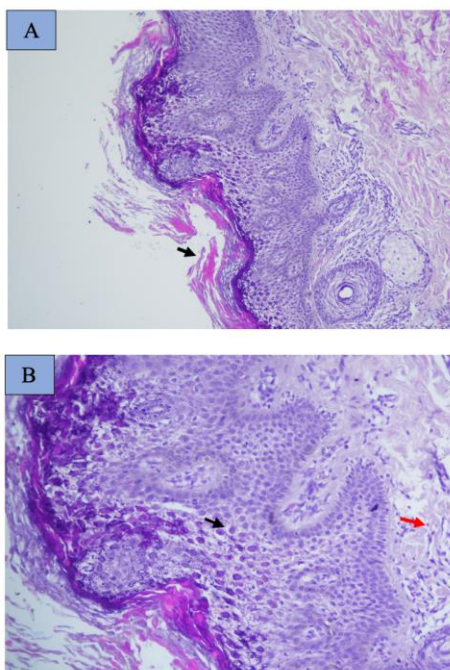


Figure 2. **Histopathology examination.** **A.** Epidermis showed extensive hyperkeratosis (↘) (Hematoxylin eosin 40X) **B.** Epidermal cells appear necrotic, accompanied by spongiosis (↘). The dermis showed foci of lymphocytic cell infiltrate (↘). Conclusion from the histopathology is epidermolytic ichthyosis (Hematoxylin eosin 100X).

### III. DISCUSSION

Epidermolytic ichthyosis (EI, OMIM 113800) is a rare keratinization disorder that is most commonly inherited in an autosomal dominant pattern, although spontaneous mutation represents about half of all cases with no family history. EI is caused by keratin 1 or keratin 10 gene mutation (Putra *et al.*, 2021). EI has many names, including bullous congenital ichthyosiform erythroderma, bullous congenital erythroderma ichthyosiformis of Brocq, bullous ichthyosiform erythroderma, and epidermolytic hyperkeratosis (Avril & Riley, 2016). The prevalence of EI is reported to be about 1:100,000- 400,000 which affects both sexes equally (Achar *et al.*, 2009). Epidermolytic ichthyosis can be classified clinically based on the involvement of palmoplantar hyperkeratosis into either palm sole (PS) or no palm sole (NPS) subtypes. Another clinical classification is based on extent of skin involvement which divides EI into localized and generalized forms (Putra *et al.*, 2021).

This dominant genodermatosis is characterized early in life by superficial bullae and erosions (Bergman *et al.*, 2008). At birth, the dominant manifestations are erythroderma, desquamation and superficial fragile blisters (Raddadi *et al.*, 2018). Newborns are at a high risk of developing electrolytic diseases which may be fatal, but as the age progresses the blistering and redness reduces and are, over time, replaced by a progressive hyperkeratosis in the stratum corneum; the uppermost layer of skin starts to thicken and shows blistering (Rout *et al.*, 2008). As the child grows, the erythroderma and blisters decrease, and the hyperkeratosis increase, presenting as dirty brown, verrucous, corrugated hyperkeratotic plaques more prominent on the joint flexures, but can be seen anywhere on the body. Hyperkeratosis characteristically resembles “corrugated cardboard” when overlying flexural areas or “cobblestoning” when overlying the extensor surfaces of joints. Occasionally, severe scalp and neck involvement occur, leading to encasement of hair shafts and alopecia. The distinct foul odor is caused by the bacterial colonization of the macerated scales and can be treated with topical antimicrobial cleansers (Alshami, 2016).

In this case, patient was a 10 year old female child who had no family history of the same complain. Based on the history, we suspected a spontaneous mutation pattern because there was no similar condition found within her family. According to her parents, the initial lesions before thick scaling was present since birth. Lesions were erythematous skin and one flaccid blister on her stomach which easily break and became erosion. Complaint of blister was only felt when the patient was born and since the age of 3 years old her skin became thickened. Her parent also complaint of foul odor since the scale become prominent and thicker. The distinct foul odor is caused by the bacterial colonization of the macerated scales, and can be treated with topical antimicrobia (Alshami, 2016).

Diagnosis of EI is usually made clinically and can be confirmed by the presence of typical histopathology. The characteristic EI histopathology shows a thickened stratum corneum and vacuolar



degeneration of the upper epidermis, leading to the histologic term epidermolytic hyperkeratosis. Vacuolar degeneration usually involves the upper epidermis and occasionally all of the suprabasilar keratinocytes. Granular cells exhibit dense, enlarged, irregularly shaped masses that appear to be keratohyalin granules (Ross et al., 2008). We performed punch biopsy on hyperkeratotic lesion on patient's right arm. The epidermis showed extensive hyperkeratosis, some epidermal cells appear necrotic, accompanied by spongiosis. The dermis showed foci of lymphocytic cell infiltrate. Conclusion from the histopathology is epidermolytic ichthyosis.

The differential diagnosis of epidermolytic ichthyosis can be made with other forms of ichthyosis, such as superficial epidermolytic ichthyosis (Mendes et al., 2013). As the clinical features of EI become more apparent with age, a wide spectrum of other genodermatoses should be considered as differentials at different stages of the disease process. In neonates, blisters and erosions can clearly differentiate EI from non-bullous congenital ichthyosis. It can be difficult to distinguish EHK from the different variants of epidermolysis bullosa, staphylococcal scalded skin syndrome, and toxic epidermal necrolysis. Nonetheless, thorough clinical and family history, full examination, and light and electron microscopic examinations of skin biopsies as well as bacterial culture can help in making a diagnosis. During childhood, EI can be differentiated from congenital recessive X-linked ichthyosis on the basis of the history of blistering and histological findings. Epidermolytic palmoplantar keratoderma is limited to the palms and soles, whereas ichthyosis bullosa of Siemens lacks erythroderma. Ichthyosis hystrix Curth-Macklin type patients may look like EHK patients, but there is no clinical or histological evidence of blister formation (Alshami, 2016).

The primary aims in EHK therapy is to evacuate scales and to diminish uncomfortable dryness of the skin (xerosis) without causing excessively irritation Treatment is predominantly symptomatic and depends on the patient's age and presentation. Infants should be monitored in the intensive care setting to manage dehydration, electrolyte imbalance, and cutaneous superinfection. Sepsis treatment should be with broad-spectrum intravenous antibiotics. Topical emollients and protective padding should be used for skin protection and to heal denuded areas (Rout et al., 2019).

The goal of therapy in children and adults is a reduction in hyperkeratosis. The first line of therapy includes the use of wide assortments of emollients and topical keratolytic that aim to expedite desquamation and enhance the appearance of the skin. These include urea, lactic acid, glycolic acid, glycerol, paraffin, propylene glycol, ammonium lactate, salicylic acid, tazarotene, N-acetyl-cysteine and a diversity of fatty creams. Topical emollients and keratolytic agents have demonstrated improvement in hyperkeratosis but are often not well tolerated due to burning and stinging. Clinicians should avoid widespread use of higher concentration salicylic acid topical preparations because of the risk of systemic salicylism. Topical retinoids, N-acetylcysteine, liarozole, and calcipotriol have been shown to affect corneocyte function and decrease epidermal hyperproliferation. However, these agents may also cause skin irritation (Rout et al., 2019).

In severe cases of epidermolytic ichthyosis, oral retinoids may dramatically improve hyperkeratosis and frequency of superinfection but can paradoxically increase skin fragility and exacerbate blistering. Thus, it is recommended to use low initial doses and then gradually increase with careful monitoring. Retinoids have a keratolytic impact that encourages the slivering of scales from the surface and counteracts unreasonable hyperkeratosis, prompting a more typical density and enhanced functioning of the horny layer. While the range of viability and toxicity of various retinoids are comparative and congruent, they are not indistinguishable. The aromatic retinoids generally have a more prominent impact on volar skin prompting advantage in the treatment of palmoplantar hyperkeratosis. One of the side effects of consumption of retinoids is the increased case of skin fragility. When the skin is prone to blistering in the case of EI, the consumption of retinoids enhances the condition at a more intense level (Rout et al., 2019).

Antibacterial soaps, chlorhexidine, and dilute sodium hypochlorite baths can decrease bacterial colonization. Topical or systemic antibiotics are needed when bacterial skin infection occurs (Foster et al., 2021). In this case, patient was treated with fusidic acid cream twice daily on the erosions, vaselin album twice daily, urea 10% cream twice daily, and levertrans ointment on patient's elbows and knees twice daily. Thick scaling on some areas and erosions improved after one month treatment.

As the clinical features of EI become more apparent with age, a wide spectrum of other genodermatoses should be considered as differentials at different stages of the disease process. In neonates, blisters and erosions can clearly differentiate EI from non-bullous congenital ichthyosis. It can be difficult to distinguish EHK from the different variants of epidermolysis bullosa, staphylococcal scalded skin syndrome, and toxic epidermal necrolysis. Nonetheless, thorough clinical and family history, full examination, and light and electron microscopic examinations of skin biopsies as well as bacterial culture can help in making a diagnosis. During childhood, EI can be differentiated from congenital recessive X-linked ichthyosis on the basis of the history of blistering and histological findings. Epidermolytic palmoplantar keratoderma is limited to the palms and soles,

whereas ichthyosis bullosa of Siemens lacks erythroderma. Ichthyosis hystrix Curth-Macklin type patients may look like EI patients, but there is no clinical or histological evidence of blister formation (Alshami, 2016).

The severity of epidermolytic hyperkeratosis is variable. Neonates with this disorder are at increased risk of sepsis, dehydration and ultimately, death. Due to the rarity of this disorder, statistics on mortality rate are lacking. For those that survive the neonatal period, episodes of blistering and skin infections occur intermittently throughout life (Foster et al., 2021). Quality-of-life studies in adults with ichthyosis have shown that their skin disease has affected them negatively, with the most problematic period being their childhood. Social stigmas can be created because of the unpleasant appearance of the skin, the possible unpleasant odor, and its fragile characteristic. For those who have ichthyosis such as EI, feelings of depression, isolation, and sadness can be an issue. Recognizing this and providing referrals to counseling services will be important in both childhood and adulthood (Avril and Riley, 2016)

#### **IV. CONCLUSIONS**

We diagnosed this patient based on clinical and histopathological examination. The goal of therapy of EI in children and adults is a reduction in hyperkeratosis. Oral retinoids were not given due to availability and drug licensing. Thick scaling on some areas and erosions improved after one month treatment with only topical antibiotic and emollients.

#### **REFERENCES**

- [1]. Avril M. & Riley C. (2016). Management of epidermolytic ichthyosis in the newborn. *Neonatal Netw.*35(1):19–28.
- [2]. Bygum A. Virtanen M. Brandrup F. Gänemo A. Sommerlund M. Strauss G. et al. (2013). Generalized and naevoid epidermolytic ichthyosis in denmark: clinical and mutational findings. *Acta Derm Venereol.* 93(3):309–13.
- [3]. Achar A. Naskar B. Rabindranath L. Ray S. (2009) Epidermolytic hyperkeratosis: a case report. *J Indian Med Assoc.*107(3):171–2.
- [4]. Al Raddadi A. Habibullah T. Abdelaal A. Felimban A. Al Raddadi H. Satti M. (2018). Epidermolytic ichthyosis without keratin 1 or 10 mutations: a case report. *Saudi J Med Med Sci.* 6(1):36.
- [5]. Nellen, R. G. L. (2017). Studies on mendelian disorders of cornification. [Doctoral Thesis, Maastricht University]. Maastricht University. <https://doi.org/10.26481/dis.20170119rn>
- [6]. Putra P.B. Radiono S. Danarti R. (2021) Generalized epidermolytic ichthyosis with palmoplantar hyperkeratosis. *Dermatol Online J.* 27(2).
- [7]. Alshami M. A. (2016) Epidermolytic hyperkeratosis: a case report from yemen. *Investig Dermatology Venereol Res.* 2(2):1–3.
- [8]. Lacz N. L. Schwartz R.A. Kihiczak G. (2005). Epidermolytic hyperkeratosis: a keratin 1 or 10 mutational event. *Int J Dermatol.* 44(1):1–6.
- [9]. Bergman R. Khamaysi Z. Sprecher E. (2008). A unique pattern of dyskeratosis characterizes epidermolytic hyperkeratosis and epidermolytic palmoplantar keratoderma. *Am J Dermatopathol.* 30(2):101–5.
- [10]. Rout D.P. Nair A. Gupta A. Kumar P. (2019). Epidermolytic hyperkeratosis: clinical update. *Clin Cosmet Investig Dermatol.* 12:333–44.
- [11]. Ross R. DiGiovanna J.J. Capaldi L. Argenyi Z. Fleckman P. Robinson-Bostom L. (2008). Histopathologic characterization of epidermolytic hyperkeratosis: a systematic review of histology from the National Registry for Ichthyosis and Related Skin Disorders. *J Am Acad Dermatol.* 59(1):86–90.
- [12]. Mendes M.S.T. Kouzak S.S. Aquino T.A. Takano G.H.S. Lima A. de P. (2013). Mosaic epidermolytic ichthyosis - case report. *An Bras Dermatol.* 88(6 suppl 1):116–9.
- [13]. Foster M.L. Jones J.M. Schadt C.R. (2021). Epidermolytic hyperkeratosis. *JAMA Dermatology.* 157(9):1114.