

Laparoscopic Mitrofanoff technique in children : A case report

N. Boumahdi ; M.Mouhim ; O. Alaoui ; A. Mahmoudi ; K. Khattala ; Y. Bouabdallah

Department of pediatric surgery, Hassan II University Hospital – Fez ; Morocco

Received 14 May, 2023; Revised 24 May, 2023; Accepted 26 May, 2023 © The author(s) 2023.
Published with open access at www.questjournals.org

I. INTRODUCTION :

The Mitrofanoff principle was originally described as a method to provide an alternative means to access the bladder.

The adoption of a purely laparoscopic or robot-assisted approach to lower urinary tract surgery in pediatric patients has been slow, given the steep learning curve and relative paucity of cases.

II. OBSERVATION :

A 07 years old child, with congenital hypothyroidism, with notion of repeated urinary infections since his young age, a biological check-up was carried out in particular renal objectifying a chronic renal insufficiency.

A radiological check-up made of renal ultrasound and retrograde ureterocystography were carried out showing the presence of a posterior urethral valve with diverticular bladder.

After discussion with the family, a laparoscopic continent urinary diversion of Mitrofanoff was scheduled and performed as shown in the images.

Laparoscopic steps :

- Positioning the patient in the supine position.
- Introduction of the 10 mm trocar supra umbilically and gas insufflation.
- Introduction of the 3 trocars, and visualisation of the appendix and the posterior surface of the bladder.
- Creation of a window between the appendix and the cecum. Fig 01
- Release of the appendix without ligation of its vascularization. Fig 02
- Approach of the bladder to the mucosa, incision of the bladder wall 4 to 5 cm and creation of an anti-reflux path. Fig 03
- Opening of 10 cm in the mucosa and realization of the anastomosis between the appendix and the mucosa. Fig 04
- The detrusor is closed on the appendix by U-stitches with Vicryl 4.0.
- Making an umbilical stoma.

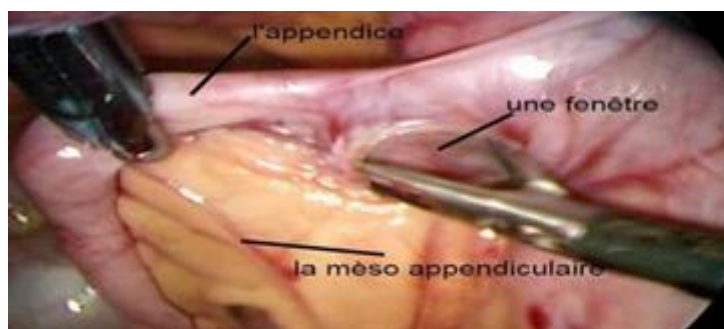


Fig 01 : Creation of a window between the appendix and the cecum

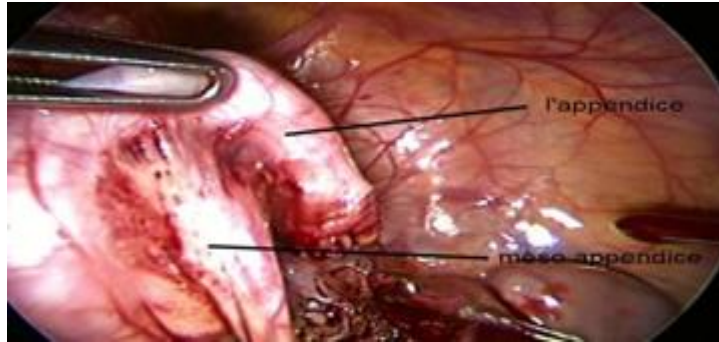

Fig 02 : Appendix resection

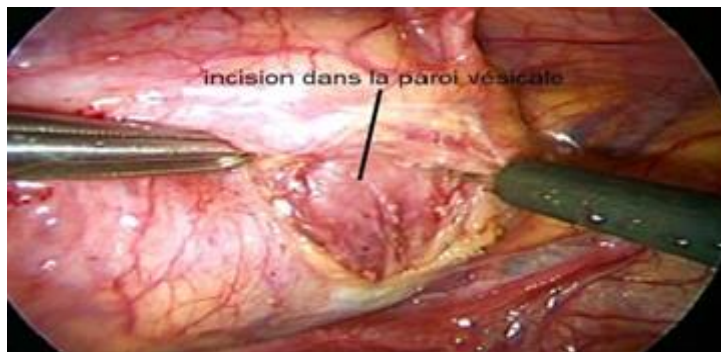

Fig 03 : Incision in the detrusor muscle

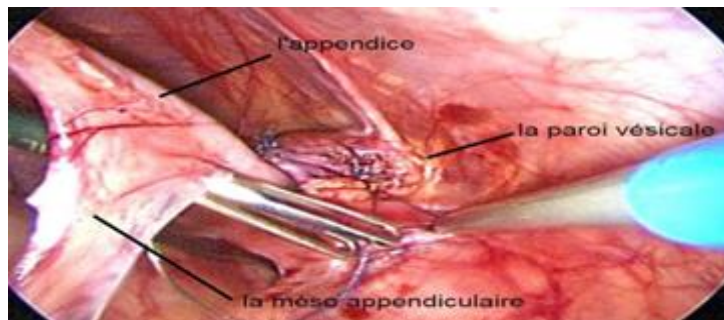


Fig 04 : Appendico-abdominal anastomosis

III. DISCUSSION :

The use of laparoscopic approach to reconstruct the lower urinary tract has been slowly introduced in the past several years. Individual cases of laparoscopic and robot-assisted Mitrofanoff appendicovesicostomy have appeared in the literature.

Congruent with the limited published experience, the surgical outcomes have compared favorably with those of an open approach in these selected patients, with a low risk of complications such as infection, bleeding, and catheter obstruction. Parents were satisfied with the short-term outcomes and postoperative recovery, particularly early resumption of physical activity and the avoidance of a prolonged absence from school.

IV. CONCLUSION :

Pure laparoscopic Mitrofanoff appendicovesicostomy is feasible and is associated with reasonable outcome with early recovery, resumption of normal activities, and excellent cosmesis.

REFERENCES

- [1]. Nerli RB, Reddy M, Devraju S, Prabha V, Hiremath MB, Jali S. Laparoscopic mitrofanoff appendicovesicostomy: Our experience in children. *Indian J Urol.* 1 janv 2012
- [2]. Gundeti MS, Petravick ME, Pariser JJ, Pearce SM, Anderson BB, Grimsby GM, et al. A multi-institutional study of perioperative and functional outcomes for pediatric robotic-assisted laparoscopic Mitrofanoff appendicovesicostomy. *J Pediatr Urol.* déc 2016
- [3]. Nguyen HT, Passerotti CC, Penna FJ, Retik AB, Peters CA. Robotic assisted laparoscopic Mitrofanoff appendicovesicostomy: preliminary experience in a pediatric population. *J Urol.* oct 2009

- [4]. l'Urologie M de. Traitement endoscopique des reflux vésico-urétéraux (RVU) de l'enfant: résultats de 9 ans d'utilisation du Macroplastique® (polydiméthylsiloxane) [Internet]. 2018 [cité 27 févr 2020]. Disponible sur: <https://www.urofrance.org/base-bibliographique/traitement-endoscopique-des-reflux-vesico-ureteraux-rvu-de-lenfant-resultats>