

## Supernumerary Teeth – Literature Review

Hanali Abu Shilbayih\*

\*Department Of Orthodontics and Pediatric Dentistry, Al-Quds University, Jerusalem, Palestine

### Abstract;

*Hyperdontia is a developmental anomaly characterised by an increased number of dental buds. It is condition with a prevalence of 0.3 -1.8% in primary dentition and 1.5–3.9% in permanent dentition. The abnormality occurs more often in the jaw, in anterior region and in permanent dentition. This study aimed to review current literature and present the aetiology, prevalence, diagnosis, treatment options and complications of supernumerary teeth.*

**Key words** ;hyperdontia, supernumerary teeth, treatment, permanent teeth, complications.

Corresponding Author;

Received 01 June, 2023; Revised 08 June, 2023; Accepted 10 June, 2023 © The author(s) 2023.

Published with open access at [www.questjournals.org](http://www.questjournals.org)

### I. INTRODUCTION;

Tooth development starts from placodes, local thickenings of the dental lamina forming as a stripe of oral epithelium at the sites of future dental arches. The placodes bud to the underlying mesenchyme which condenses around the bud. Rapid growth and folding morphogenesis of the epithelium leads to the cap stage of development.[1] The shape of the tooth crown becomes established during the bell stage when the locations and heights of tooth cusps are set by additional foldings and growth of the epithelium. The odontoblasts and ameloblasts differentiate during the bell stage, and deposit the extracellular matrices of dentin and enamel, respectively. Differentiation, matrix deposition, and mineralization start from the tips of the cusps and proceed cervically, and after they reach the future cemento-enamel junction, root development starts .[1,2]

Permanent (secondary) teeth develop from the successional dental lamina associated with the primary (deciduous) tooth germs, and their budding starts during the cap stage of primary tooth development. Also posterior molars form in succession from the dental lamina at the distal aspect of the previous molar. Both the primary and successional dental laminae contain stem cells which have the capacity to form teeth. Sox2, a known marker gene of stem cells, is expressed in the primary as well as successional dental lamina .[3,4]

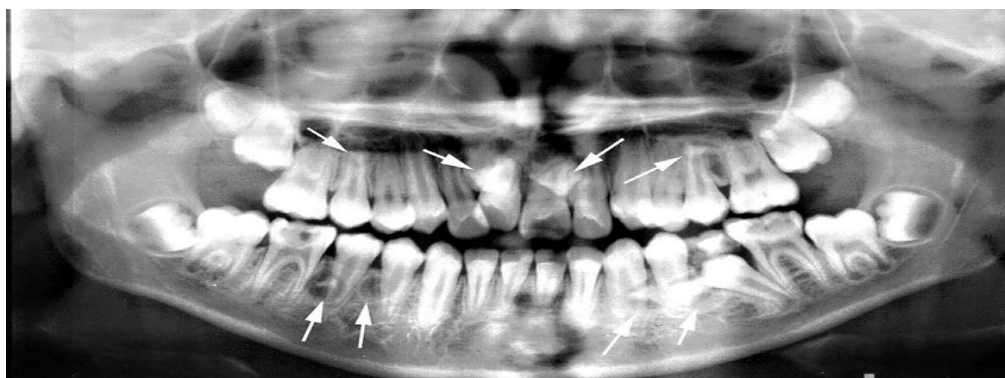


Fig.1;Panoramic view of nonsyndromic multiple supernumerary teeth:

Bone formation is initiated in the maxilla and mandible only after the initiation and budding of primary teeth, but the subsequent development of alveolar bone from the mesenchyme surrounding the tooth germs is tightly coordinated with tooth morphogenesis. At the time of eruption, the teeth are surrounded by bone, and their eruption depends on precisely regulated bone remodeling, i.e., bone resorption between crown and the oral cavity and bone apposition at the base of the roots.[3,5,6]

The most important mechanism regulating tooth development is the interaction between the epithelial and mesenchymal cells. During the initiation of tooth development, the epithelium has an instructive role and determines the type of the tooth to be formed as well as the odontogenic fate of the mesenchymal cells.[4] The capacity to regulate tooth development shifts to the mesenchyme during budding and, subsequently, mesenchymal signals regulate the morphogenesis of the epithelium and the shape of the tooth. The differentiation of the odontoblasts, ameloblasts, and cementoblasts, as well as their matrix deposition, is also regulated by interactions between the different tissues. Hence, tooth development is controlled by a series of reciprocal tissue interactions. It is noteworthy that similar sequential and reciprocal cell interactions govern the development of all organs in the embryo.[3-7]

Hyperdontia and supernumerary teeth (ST )are terms describing an excess in tooth number that can occur in both the primary and permanent dentitions. Reports on the incidence of hyperdontia include values as high as 3%, with males being affected twice as frequently as females. Ninety percent to 98% of supernumerary teeth occur in the maxilla, with the permanent dentition being more frequently affected than the primary dentition. The most common supernumerary tooth is the mesiodens, which occurs in the palatal midline and can assume a number of shapes and positions relative to the adjacent teeth. The majority tend to be located palatal to the central incisors.[4-9]Fig.1

Supernumerary teeth may be present in any area of the dental arches but usually, are seen in the maxillary anterior region. The exact etiology of supernumerary teeth is not completely known, but various theories have been put forward which include dental lamina hyperactivity theory, the dichotomy of tooth bud, atavism theory, heredity, and environmental factors. According to dental lamina hyperactivity theory development of supernumerary teeth is the result of local, independent and conditioned hyperactivity of dental lamina. This is the most accepted theory.[4,9,10]

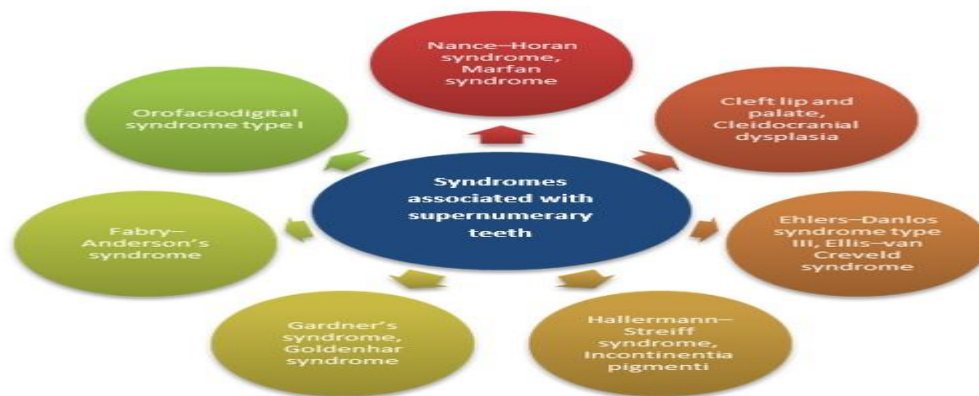

Table.1;Syndromes associated with hyperdontia

Supernumerary teeth may be diagnosed either clinically when a spontaneous eruption has occurred or radiographically as a chance finding or as the cause of displaced or impacted permanent teeth. They may remain in position in jaws without disturbing adjacent teeth or may cause complications such as non-eruption or delayed eruption of permanent teeth, malocclusion like crowding or midline diastema and formation of cysts with bone destruction and root resorption of adjacent teeth.[5,4,7,9]Table.1

This papers aimes to review current literature and present the aetioly, prevalence, diagnosis, treatment options and complications of supernumerary teeth.

Etiology;

The etiology of supernumerary teeth is not well understood, but ethnic and racial background may play a role in the occurrence of supernumerary teeth. A previous epidemiological study done in Hispanic race has showed a higher prevalence rates in this group of population. Several theories have been advanced by investigators to explain its etiology[1-4]:

1. Theory of the Prague school.
2. The godo theory.
3. Theory of histochemical disruption.[1]
4. The progress zone theory – suggests that these teeth result from the progress zone of the dental lamina in the end of every tooth series or class.[4]
5. Unified etiological explanation – It is based on a multifactorial model that has a continuous scale, with thresholds related to tooth number and size. The anomaly’s position on this scale is determined by a combination of the genetic and environmental factors.[6]

6. Supernumerary teeth result from the mutant genes. This is supported by the observation of greater frequency of supernumerary teeth in patients with maxillofacial anomalies and syndromes.[1,4,8]

7. Theory of epithelial remnants - Remnants of dental lamina can persist, as “rests of Serres”, which on induction lead to a supernumerary tooth.[9]

8. Theory of supernumerary tooth germ - Supernumerary tooth may also arise separately (as an offshoot) from the continued activity of the dental lamina after the formation of the normal number of tooth buds. [4]

9. Theory of duplication -Complete division (schizodontia, dichotomy) of an early developing bud was suggested by Taylor.[1,7]

10. Atavism (phylogentic reversion or evolution thrown back) may cause the occurrence of distomolar.[7,8]

It has been postulated by researchers that these supernumerary teeth form due to continuation of growth in the progress zones of a specific proliferating tooth class, attributed to the morphogenetic field theory, or occur due to decrease in the size of the enamel organ below a certain threshold limit which signals the dental lamina to generate additional enamel organs. Three possible mechanisms that can give rise to supernumerary teeth in the premolar region are put forward.[1,4,11]

1. An abnormal proliferation from dental lamina can give to predeciduous premolars.[2]

2. The lingual extension of the dental lamina can give rise to an additional follicle before the development of the permanent teeth [1]

3. An extra tooth can develop from the extension of the dental lamina after the deciduous and permanent follicles have formed.[4]

Heredity is believed to be an important etiological factor in the occurrence of supernumerary teeth by a number of researchers. These teeth could be inherited either as autosomal trait with the lack of penetrance in some generations or as sex-linked inheritance that explain the existence of a sex predominance of males over females. A combination of genetic and environmental factors is also proposed to explain the occurrence of supernumerary teeth by some investigators.[10]

Few authors regard genetics to contribute to the development of mesiodens, as these teeth are often seen in twins, siblings and sequential generations of a single family.[11]

According to one theory, mutant genes give rise to supernumerary teeth and this is supported by the finding of increased supernumeraries in patients with facial & dental anomalies such as cleft lip & palate. The development of bilateral supernumeraries also suggests that they may be controlled by a mutant gene. The importance of heredity is emphasized by the increased number of supernumerary teeth found in relatives of those affected.[11-15]



Fig.2;Supernumary tooth in the palatal of the root tooth

Despite advances in the knowledge of tooth morphogenesis and differentiation, relatively little is known about the etiology and molecular mechanisms underlying supernumerary tooth formation. [14,16]Genetic studies mapped Cleidocranial dysplasia to chromosomal 6p21, and heterozygous mutations (haplo insufficiency) in RUNX2 (CBFA1) gene have been identified to be responsible for the development of CCD. Gardner syndrome is caused by germ line mutations in the APC gene. [14,15]APC is located on chromosome 5q21-q22 and it can be alternatively spliced in multiple coding and noncoding regions. It has also been suggested that inactivation of APC or forced activation of Wnt/ü(catenin signaling results in multiple supernumerary tooth formation in both humans and in mice, but the key genes in these pathways are not very clear. [15,16]Notably, adult oral tissues, especially young adult tissues, are still responsive to loss of APC or activation of Wnt/ü(catenin signaling, and are able to form new teeth. Better understanding of the role of Wnt/ü-catenin, APC, and RUNX2 in the formation of supernumerary teeth, together with detailed analysis of successional tooth formation in various model systems will allow us to identify the exact genes responsible for supernumerary tooth formation.[14-16]

Consanguinity is a known factor in the etiology of many diseases.[13,16] Arab countries have some of the highest rates of consanguineous marriages in the world, and specifically, first cousin marriages, which may

reach (25-30%) of all marriages.[13-16] A large Lebanese consanguineous family has been reported to have four individuals who exhibited five incisors in the anterior mandible.[14] The prevalence of hyperdontia varies significantly among ethnic groups and different ages.[15,16]

Arab countries have some of the highest rates of consanguineous marriages in the world, and specifically first cousin marriages, which may reach (25-30%) of all marriages.[13,15] Moreover, according to Tadmouri, et al.,[17] the Arab populations have a long tradition of consanguinity due to socio-cultural factors. Regarding Saudi Arabia, El-Hazmi, et al.,[18] found that the overall rate of consanguinity reached (57.7%). These results place Saudi Arabia among the countries of the world with a high rate of the consanguinity.

From the genetic point of view, there is evidence from animal studies that genetic factors do play a role in ST formation.[19] However, the interplay of these factors and the targets of their pathways remain largely unknown. These types of studies guide the selection of candidate genes for evaluation in human as the prevailing mechanisms hypothesized to cause ST include hyperactivity of the dental lamina, resulting in the formation of additional, or dichotomy of the dental tooth germs that result in more than one tooth.[16,20,22]

#### Prevalence;

The incidence of ST for males is higher than females [23,24]. Contrarily, Clayton [25] and Bäckman and Wahlin [26] reported more female predilection. Higher prevalence figures for ST were reported in Mongoloid groups than in other racial groups [13,26,27]. The conical ST in anterior region is the most common type of ST. The incidence, location, and morphology may vary depending on gender. Mitchell [28] reported that females are more commonly affected than males with a 2:1 ratio in permanent, while no significant difference was found in primary dentition. It has also been reported that subtypes of ST also presented gender, where males are commonly affected in midline and premolar regions and incisor and canine regions were in females [17,28]. Fig.2

Several studies have reported that there is a racial difference in the incidence of ST. In primary dentition, the reported incidence was between 0.1% and 1.8% for Caucasians, where in Mongolian origin, 0.1% was reported for Japanese while the prevalence of ST for Chinese children in Taiwan was 7.8% [29] and 2.8% in southern Chinese [30]. In permanent dentition, the prevalence ranges from 0.4% to 2.1% for Caucasians while 2.4%, 3.4%, and 6% for southern Chinese [31], Japanese [22], and American Blacks [32]. van der Merwe and Steyn [33] reported a higher incidence of ST (7%) in a South African mining community of the skeletal remains. These different prevalence figures are reported on ST, probably due to the different populations investigated and whether the reported prevalence of ST is just a reflection of the variation in the diagnostic tools, assessment process, and sampling methods [29-33]. Most recently,

Anthony and co-workers [34] reported that the prevalence of ST ranges from approximately 3 to 6% or even higher which is higher than previously reported prevalence in literature. [34,35]

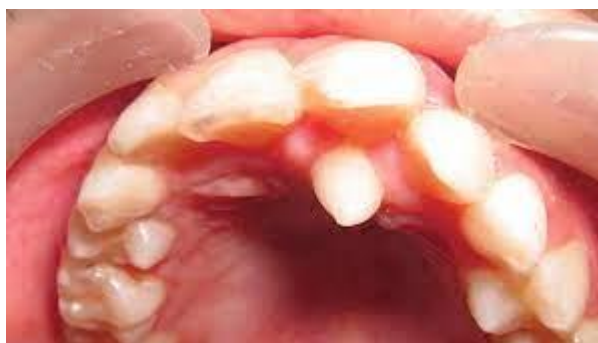

Fig.3;Supranumerary maxillary tooth

#### Classification;

Supernumerary teeth are classified according to morphology and location (Table 1). In the primary dentition, morphology is usually normal or conical. There is a greater variety of forms presenting in the permanent dentition. Table.2 Four different morphological types of supernumerary teeth have been described: [1,2,4]

- conical
- tuberculate
- supplemental
- odontome.

#### Conical ;

This small peg-shaped conical tooth is the supernumerary most commonly found in the permanent dentition. It develops with root formation ahead of or at an equivalent stage to that of permanent incisors and usually presents as a mesiodens. It may occasionally be found high and inverted into the palate or in a horizontal



position. In most cases, however, the long axis of the tooth is normally inclined. The conical supernumerary can result in rotation or displacement of the permanent incisor, but rarely delays eruption. [1,4,7]Fig.3

**Tuberculate;**

The tuberculate type of supernumerary possesses more than one cusp or tubercle. It is frequently described as barrel-shaped and may be invaginated. Root formation is delayed compared to that of the permanent incisors. Tuberculate supernumeraries are often paired and are commonly located on the palatal aspect of the central incisors. They rarely erupt and are frequently associated with delayed eruption of the incisors .[[4,10,22]

Morphology	Appearance	Occurrence (%)
Conical	Small/peg shaped tooth with normal root	70–80
Tuberculate	Barrel shaped crown with rudimentary root, often paired	10–12
Supplemental	Duplication of tooth in the normal series (mostly in deciduous dentition and in permanent maxillary lateral incisor and mandibular premolar)	6–8
Odontome	No regular shape, disorganized diffuse mass of dental tissue	3–4

Table.2; Morphological types of supernumerary teeth

**Supplemental**

The supplemental supernumerary refers to a duplication of teeth in the normal series and is found at the end of a tooth series (Fig. 5). The most common supplemental tooth is the permanent maxillary lateral incisor, but supplemental premolars and molars also occur. The majority of supernumeraries found in the primary dentition are of the supplemental type and seldom remain impacted.[1,4]

**Odontoma**

Howard lists odontoma as the fourth category of supernumerary tooth. However, this category is not universally accepted. The term “odontoma” refers to any tumor of odontogenic origin. Most authorities, however, accept the view that the odontoma represents a hamartomatous malformation rather than a neoplasm. The lesion is composed of more than one type of tissue and consequently has been called a composite odontoma. Two separate types have been described: the diffuse mass of dental tissue which is totally disorganized is known as a complex composite odontoma, whereas the malformation which bears some superficial anatomical similarity to a normal tooth is referred to as a compound composite odontoma. [1,22,28]

**Management of Supernumeraries teeth;**

The first step in management is the localization and identification of complications associated with supernumeraries. Teeth can be localized using the vertical or horizontal parallax technique. [2]A periapical radiograph taken using the paralleling technique gives the most detailed assessment compared to other radiographic views. If teeth are causing no complications and are not likely to interfere with orthodontic tooth movement (i.e. if they lie beyond the dental apices) they can be monitored with yearly radiographic review. [4]The patient should be warned of complications, such as cystic change and migration with damage to nearby roots. If the patient does not wish to risk such complications, it is acceptable to remove supernumerary teeth. If they are associated with the roots of permanent teeth, it may be sensible to await full root development before surgical extraction to minimize the chances of root damage. Root development of the maxillary incisors should be complete by the age of ten years. If supernumerary teeth are associated with complications, it is usual to extract such teeth, which usually involves a surgical procedure.[4,5] Early extraction of supernumeraries, causing incisor impaction, may have the benefit of minimizing loss of eruptive potential, space loss and centerline displacement. Even in cases where the unerupted incisors are severely rotated, early removal of the causative supernumerary tooth can result in self-correction and correct alignment.[7,8] The greatest concern with early removal is the risk of affecting the formation of adjacent roots. Additionally, a young child may be unable to tolerate such a procedure and may develop a dental phobia. However, delayed eruption of maxillary central incisors can result in mesial movement of the lateral incisors, space loss and diminished development .[1,2,12,13] Table.3

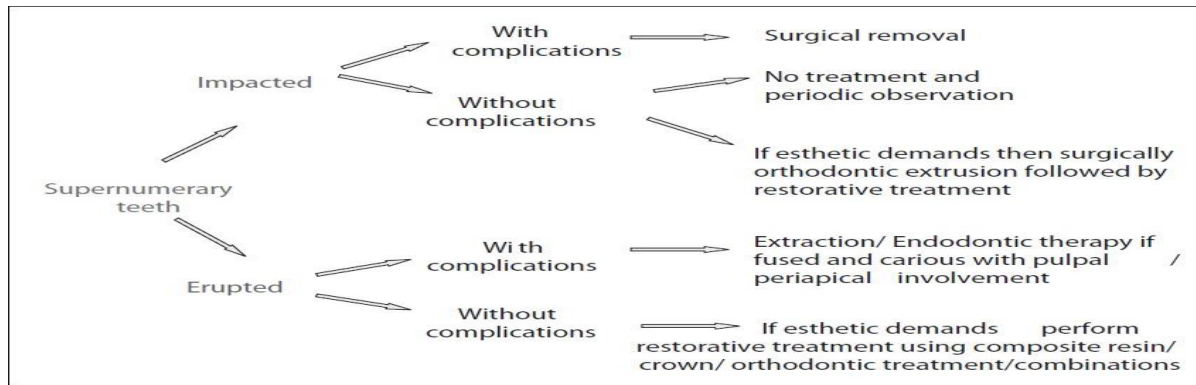


Table.3; Mangement of supernumerary teeth

The presence of a supernumerary tooth may have no effect on the developing dentition and can be a chance finding when a patient first presents for orthodontic treatment. However, in other instances, a variety of effects may be seen including displacement, crowding, dilaceration, root resorption, cystic change and nasal cavity eruption. However, pathology is rare and the complication seen most frequently is delayed eruption of an incisor.[1,4]

#### **Indications for Supernumerary Removal** Removal of the supernumerary tooth is recommended where alveolar height;

- central incisor eruption has been delayed or inhibited;
- altered eruption or displacement of central incisors is evident;
- there is associated pathology;
- active orthodontic alignment of an incisor in close proximity to the supernumerary is envisaged;
- its presence would compromise secondary alveolar bone grafting in cleft lip and palate patients;
- the tooth is present in bone designated for implant placement;
- spontaneous eruption of the supernumerary has occurred.

#### **Indications for Monitoring Without Supernumerary Removal**

##### **Extraction is not always the treatment of choice for supernumerary teeth.**

They may be monitored without removal where:

- satisfactory eruption of related teeth has occurred;
- no active orthodontic treatment is envisaged;
- there is no associated pathology;
- removal would prejudice the vitality of the related teeth.

Furthermore, in situations where a supernumerary tooth is preventing the eruption of an incisor, the eruptive potential of the incisor may be lost if intervention is delayed. Following removal of supernumerary teeth, the time taken for the unerupted tooth to erupt can vary between six months and three years. Up to 91% of impacted permanent incisors erupt within 18 months following removal.[7-9]

Factors affecting the time taken include the distance the unerupted tooth was displaced, the space available in the dental arch and the stage of root development of the permanent tooth.[10] The patient's age and the availability of space in the dental arch are the two critical factors in determining whether spontaneous eruption occurs following removal of supernumerary teeth.[4-7] At the initial operation to remove the supernumerary, attachment of a gold chain to the unerupted tooth gives the option of applying orthodontic traction to the tooth if it does not erupt spontaneously. However, in order to expose the unerupted tooth sufficiently for an attachment to be bonded, a greater amount of supporting bone needs to be removed. Exposure of the unerupted tooth (with or without a bonded attachment) may result in poor gingival aesthetics, with less attached gingivae between the exposed tooth and neighboring teeth[7,22,28]. Table.3

If supernumerary teeth are likely to interfere with orthodontic tooth movement, they should be removed prior to the commencement of treatment. If a supplemental tooth is present and erupted, it may be difficult to determine which is the supplemental and which is the tooth of the normal dental series. In these circumstances, assuming both teeth are healthy, it is logical to extract the tooth most displaced from the line of the arch for the relief of crowding.[4,7]

Finally, the presence of a supernumerary tooth should alert the clinician to the possibility of the development of late forming supernumerary teeth, especially in the lower premolar region. It has been reported that up to 24% of patients with an anterior maxillary supernumerary may later develop supplemental premolars.[7,22,28]

### Complications;

Various complications may occur as the result of the presence of ST including crowding, delayed eruption, spacing, impaction of permanent incisors, abnormal root formation, alteration in the path of eruption of permanent incisors, mediandiastema, cystic lesions, intraoral infection, rotation, root resorption of the adjacent teeth, or even eruption of incisors in the nasal cavity and retained deciduous teeth [1,4,36].

**Midline Diastema;** Presence of erupted and unerupted mesiodens may cause midline diastema. A retrospective analysis showed 10% of cases with SNT cases exhibited midline diastema [36].

**Delayed or Failure of Eruption;** Supernumerary tooth is the common reason for the delayed or failure of eruption in premaxillary region [2,37]. Prevention or delayed eruption of associated permanent teeth [10, 36] and tuberculate ST are the possible reasons for failure of eruption of maxillary permanent incisors [36]. Supernumerary teeth in other locations may also cause failure of eruption of adjacent teeth. [4]

**Displacement;** Displacement of the crowns of the adjacent teeth is a common feature in cases that associated with ST [65]. The amount of displacement varies from a mild rotation to complete displacement [9]. Supernumerary teeth cause severely rotated incisors and sometimes remain unerupted. Self-correction and correct alignment may result in early removal of the causative ST [37].

**Crowding ;** Any form of ST can cause this complication; erupted or unerupted supplemental ST most often leads to crowding [1,4,39].

**Root Resorption ;** Root resorption of adjacent teeth some times leads to loss of tooth vitality [63]. Alveolar Bone Grafting. Secondary alveolar bone grafting may be compromised due to ST in patients with cleft lip and palate. Unerupted ST in the cleft site is normally removed at the time of bone grafting. [1,4,7]

**Implant Site Preparation;** The presence of an unerupted ST in a potential implant site may compromise implant placement.

**Ectopic Position;** Ectopic eruption of ST has been reported, among the frequently reported in the nasal cavity. Clinically, a white mass may be seen in the nasal area, radiographically appearing as a tooth-like radiopacity [38,39,40,41].

**Late Forming Supernumerary Teeth;** Patients with a history of anterior conical or tuberculate supernumerary teeth at an early age have a 24% possibility of developing single or multiple supernumerary premolar satellite teeth [2,43].

**Root Abnormalities.** Dilaceration is a developmental anomaly in the tooth shape and its structure, which may happen as sharp bending of the tooth in either the crown or the root portion. Loss of tooth vitality has been reported in rare conditions. [1,4]

**Cyst Formation;** It has been reported that cyst formation due to ST was observed in 11% of the cases where dentigerous cysts are common type [42,43].

## II. Conclusion

Supernumerary teeth may cause aesthetic deformities and functional impediments, therefore early diagnosis and interdisciplinary intervention are important to minimize consequences to the developing dentition. The clinicians should be mindful of such signs as delayed eruption, alterations in the eruptive pattern, shift in the midline, or dental crowding.

### Conflict of Interests

The author declares that there is no conflict of interests regarding the publication of this paper.

## References

- [1]. C. Schulze. Developmental anomalies of the teeth and jaw. In Thoma's Oral Pathology, R. J. Gorlin and H. M. Goldman. 6th edition. St Louis: Mosby Elsevier. 1970
- [2]. Yassin OM, Hamori E. (2009); Characteristics, clinical features and treatment of supernumerary teeth. J. Clin. Pediatr. Dent. ; 33:247-250.
- [3]. Hattab FN, Yassin OM, Rawashdeh MA. (1994); Supernumerary teeth: Report of three cases and review of literature. ASDC. J. Dent. Child.; 61:382-393.
- [4]. Watted N, Abdulgani Azz, Abu-Hussein M. (2014); Supernumerary teeth in permanent dentition in patients with cleft lip and palate. Int J Dent Health Sci.; 1(3): 410-418
- [5]. M. T. Garvey, H. J. Barry, and M. Blake, (1999); "Supernumerary teeth: an overview of classification, diagnosis and management," Journal of Canadian Dental Association, vol.65, no.11. 612-616.
- [6]. Proffit W. Contemporary Orthodontics. St. Louis: CV Mosby Co; 1986:99
- [7]. Andlaw RJ, Rock WP. A Manual of Paediatric Dentistry. 4th ed. New York: Churchill Livingstone; 1996,156
- [8]. Bhussry BR, Sharawy M. Orban's Oral Histology and Embryology. 11th Edn. Mosby; 2003: 45
- [9]. Pindborg JJ. Pathology of Dental hard tissues. 1st edition. Philadelphia: W. B. Saunders Co. 1970; 18: 4: 144-148
- [10]. Gorlin RJ, Cohen MM, Levis LS. Syndromes of the head and neck. 3rd edition. New York: Oxford University Press. 1990: 249-52
- [11]. Lubinsky M, Kantaputra PN. (2016); Syndromes with supernumerary teeth. Am J Med Genet A. ;170(10):2611-2616
- [12]. T.D. Foster and G.S. Taylor (1969); "Characteristics of supernumerary teeth in the upper central incisor region," The Dental Practitioner and Dental Record, vol.20, no.1. 8-12.

- [13]. P. Proff, J. Fanghanel, S. Allegrini Jr., T. Bayerlein, and T. Gedrange,(2006); “Problems of supernumerary teeth, hyperdontia or dentes supernumerarii,” *Annals of Anatomy*,vol.188,no.2,pp. 163–169.
- [14]. Abu-Hussein M, Watted N, Yehia M, Proff P, Iraqi F (2015) ;Clinical Genetic Basis of Tooth Agenesis, *Journal of Dental and Medical Sciences* ,14(12): 68-77. DOI: 10.9790/0853-141236877
- [15]. Abdulgani Azzaldeen, Nezar Watted, Abdulgani Mai, Péter Borbély, Muhamad Abu- Hussein (2017) ; Tooth Agenesis; Aetiological Factors. *Journal of Dental and Medical Sciences* ,16(1): 75-85
- [16]. Muhamad AH, Azzaldeen A ; Genetic of Nonsyndromic Cleft Lip and Palate, 2012. 1:510.doi:10.4172/ scientificreports.510
- [17]. Tadmouri GO, Nair P, Obeid T, Al Ali MT, Al Khaja N, Hamamy HA. (2009);Consanguinity and reproductive health among Arabs. *Reprod Health* ;6:17.
- [18]. El-Hazmi MA, al-Swailem AR, Warsy AS, al-Swailem AM, Sulaimani R, al-Meshari AA. (1995);Consanguinity among the Saudi Arabian population. *J Med Genet* ;32:623-6.
- [19]. Khan MI, Ahmed N, Neela PK, Unnisa N.,(2022); The Human Genetics of Dental Anomalies.*Glob Med Genet*. Feb 25;9(2):76-81. doi: 10.1055/s-0042-1743572
- [20]. Sartaj R, Sharpe P.(2006); Biological tooth replacement. *Journal of Anatomy* .:209(4): 503-509.
- [21]. Bei M. (2009);Molecular genetics of tooth development. *Current Opinion in Genetics & Development* .:19(5):504-510.
- [22]. Andlaw RJ, Rock WP. *A Manual of Paediatric Dentistry*.4th ed. New York: Churchill Livingstone; 1996, 156.
- [23]. A. H. Brook,(1974); “Dental anomalies of number, form and size: their prevalence in British school children,” *Journal of the International Association of Dentistry for Children*,vol.5,no.2, pp.37–53
- [24]. E. C. Kuchler, A. G. Costa, C. Costa Mde, A. R. Vieira, and J. M. Granjeiro,(2011); “Supernumerary vary depending on gender,” *Brazilian Oral Research*,vol.25,76–79.
- [25]. J.M.Clayton,(1956);“Congenital dental anomalies occurring in3,557 children,”*Journal of Dentistry for Children*,vol.23,pp.206–208.
- [26]. B.B’ackmanandY.B.Wahlin,(2001);“Variations in number and morphology of permanent teeth in 7-year-old Swedish children,” *International Journal of Paediatric Dentistry*, vol. 11, no. 1, pp. 11–17,
- [27]. J.D.NiswanderandC.Sujaku,(1963);“Congenital anomalies of teeth in Japanese children,” *American Journal of Physical Anthropology*,vol.21,no.4,pp.569–574.
- [28]. L. Mitchell,(1989); “Supernumerary teeth,” *Dental update*, vol. 16, no. 2,65–68.
- [29]. W.H.Huang,T.P.Tsai,andH.L.Su,(1992);“Mesiodens in the primary dentition stage: a radiographic study,” *Journal of Dentistry for Children*,vol.59,no.3,pp.186–189.
- [30]. N. M. King, S. Tongkoom, A. Itthagarun, H. M. Wong, and C. K. Lee,(2007) “A catalogue of anomalies and traits of the primary dentition of southern Chinese,” *Journal of Clinical Pediatric Dentistry*,vol.32,no.2,pp.139–146.
- [31]. S.J.J.TsaiandN.M.King,(1998)“Acatalogue of anomalies andtraits of the permanent dentition of southern Chinese,” *Journal of Clinical Pediatric Dentistry*,vol.22,no.3,pp.185–194.
- [32]. E.F.HarrisandL.L.Clark,(2008);“An epidemiological study of hyperdontia in American blacks and whites,”*AngleOrthodontist*,vol. 78,no.3,pp.460–465.
- [33]. A. E. van der Merwe and M. Steyn, (2009);“A report on the high incidence of supernumerary teeth in skeletal remains from a 19th century mining community from Kimberley, South Africa.”*South African Dental Journal*,vol.64,no.4,pp.162–166.
- [34]. R.P.Anthonappa,N.M.King,andA.B.M.Rabie,(2012);“Diagnostic tools used to predict the prevalence of supernumerary teeth:a meta-analysis,”*Dentomaxillofacial Radiology*,vol.41,no.6,444–449.
- [35]. R.P.Anthonappa,N.M.King,andA.B.M.Rabie,(2013)“Prevalence of supernumerary teeth based on panoramic radiographs revisited,”*Pediatric Dentistry*,vol.35,no.3 ,257–261.
- [36]. Mason C, Rule DC, Hopper C. (1996)Multiple supernumeraries: the importance of clinical and radiographic follow up. *Dentomaxillofac. Radiol.* ; 25:109-113.
- [37]. Houston WJB, Stephens CD, Tulley WJ. *A Textbook of Orthodontics*. 2nd ed. Wright Publications; 1992. 174-5
- [38]. Hogstrom A, Andersson L. (1987);Complications related to surgical removal of anterior supernumerary teeth in children.*ASDC J Dent Child* ; 54:341-3
- [39]. Singh G (2012); Supernumerary teeth (hyperdontia): A report of three cases. *JIDA* 6(1): 45- 47.
- [40]. Watted A, Awadi O, Watted N & Abu-Hussein M. (2021) Impacted Maxillary Central Incisors: Surgical Exposure and Orthodontic Treatment: A Case Report. *J Oral Health Dent Res*, 1(1): 1-6.
- [41]. Abu-Hussein M, Watted N, Proff P, Watted A (2017) ;Clinical Management of Bilateral Impacted Maxillary Canines. *Sci J Res Dent* 1(1): 1-7.
- [42]. Ata-Ali F, Ata-Ali J, Peñarrocha-Oltra D, Peñarrocha-Diogo M. (2014);Prevalence, etiology, diagnosis, treatment and complications of supernumerary teeth. *J Clin Exp Dent*. M;6(4):e414-8.
- [43]. Abu-Hussein M, Watted N, Abdulgani A (2015); The Curve of Dental Arch in Normal Occlusion. *Open Sci J Clin Med* 3(2): 47-54.