



Research Paper

## Retrospective Evaluation of the Results of Locking Titanium Plate in Anterior Cervical Fusion.

Dr. Tushar Jibhau Deore. D. N. B.<sup>1</sup>, Dr. Yogesh R. Gaikwad. M. S.<sup>2</sup>,  
Dr. Nikhil Malewar. M.S.<sup>3</sup>, Dr. Vijay Vasant Nemade. D. N. B.<sup>4</sup>

<sup>1</sup>Assistant Professor, Department of Orthopaedics Smt. Kashibai Navale Medical College and General Hospital, Narhe, Of Sinhagad Road, Pune, (M. S.) India.

<sup>2</sup>Associate Professor. Department of Orthopaedics Smt. Kashibai Navale Medical College and General Hospital, Narhe, of Sinhagad Road, Pune, (M. S.) India.

<sup>3</sup>Assistant Professor. Department of Orthopaedics. Smt. Kashibai Navale Medical College and General Hospital, of Sinhagad Road, Narhe, Pune, (M. S.) India.

<sup>4</sup>Assistant Professor. Department of Orthopaedics. Smt. Kashibai Navale Medical College and General Hospital, of Sinhagad Road, Narhe, Pune, (M. S.) India.

Received 28 October, 2016; Accepted 12 November, 2016 © The author(s) 2016. Published with open access at [www.questjournals.org](http://www.questjournals.org)

### ABSTRACT:

**Introduction:** Cervical radiculopathy is the condition leading to radicular pain along the course of the involved cervical nerve root. The condition may be associated with spinal cord compression leading to myelo-radiculopathy. Cervical radiculopathy leading to radicular symptoms and not getting better with conservative trail of about 6-8 weeks need surgical treatment. The most commonly done surgical procedure for such condition is anterior cervical discectomy and fusion.

**Material and Methods:** In this study we have retrospectively evaluated 59 patients who underwent anterior cervical discectomy and fusion using tri-cortical iliac crest bone graft with locking titanium plates for symptomatic cervical myelo-radiculopathy. All patients were evaluated clinically pre operatively by VAS(visual analogue scale) score, NDI (neck disability index). Post operatively patients were evaluated by VAS score, NDI and Odom's criteria for surgical outcome. At each follow up X rays were done to assess the adequacy of fusion, to assess Saggital Segmental Alignment (SSA) at operated level and Saggital Alignment of Cervical Spine (SACS) for whole cervical spine.

**Results:** There were 37 males and 22 females in our study with mean age was 46 years (range 31-75 years). The mean surgical time was 86.98 minutes, with mean blood loss of 118 ml. The mean hospital stay was 5.82 days. All patients were followed up for a minimum period of 18 months. Maximum period of follow up was 45 month with average follow up 27.92 months. The mean NDI score, VAS score, SSA and SACS was reduced significantly post surgery. The Odom's criteria post-operatively at final follow up was Excellent in 45 patients, Good in 10 and Fair in 4 cases.

**Conclusion:** Anterior cervical discectomy and fusion using tri cortical iliac crest bone graft and locked titanium plating is an effective surgical intervention which avoids graft related complications associated with ACDF (anterior cervical decompression and fusion) without plating. It gives good clinical and radiological outcome with minimal complications, good fusion rate for symptomatic cervical myelo-radiculopathy.

**Keywords:** Anterior Cervical Fusion, Cervical radiculopathy, myelo- radiculopathy, cervical locking plates.

### I. INTRODUCTION

Cervical spondylosis is the most common cause leading to radiculopathy, myelopathy and myelo-radiculopathy. Cervical spondylosis leads to disc herniation, formation of osteophytes, facet hypertrophy. The condition can be asymptomatic or symptomatic depending upon the compression on the nerve root and the cervical spinal cord (1,2). Symptomatic myelo-radiculopathy occurs in only 10-15% patients(3).

The most common treatment modality for cervical spondylosis is conservative management which consists of anti-inflammatory medication, rest, immobilization and physiotherapy (4,5). However patients

\*Corresponding Author: Dr. Tushar Jibhau Deore. D. N. B.<sup>1</sup>

<sup>1</sup>Assistant Professor, Department of Orthopaedics Smt. Kashibai Navale Medical College and General Hospital, Narhe, Of Sinhagad Road, Pune, (M. S.) India.

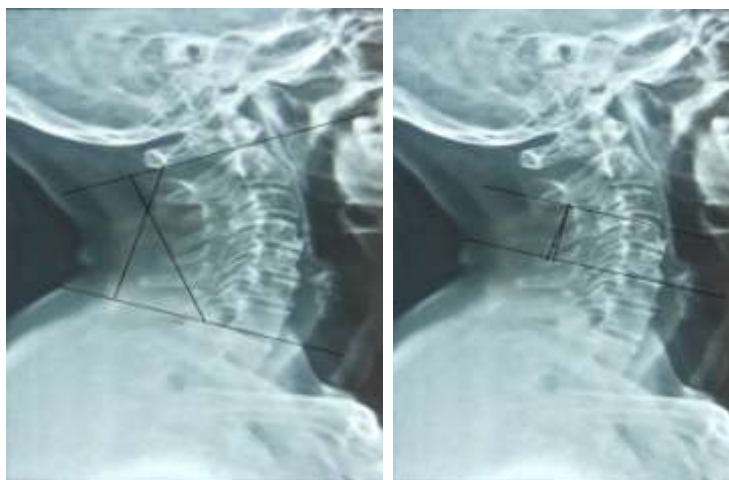
presenting with radicular pain which is not getting relieved by conservative method for a period of 6-8 weeks, the management is essentially surgical (2,3). Surgery is also required for patients presenting with myelopathy or myelo-radiculopathy.

Anterior cervical discectomy and fusion with tri cortical bone graft and plating is the gold standard for patient with single level cervical radiculopathy or myelo-radiculopathy (6,7) . In this study we have evaluated the clinico-radiological results of anterior cervical discectomy and fusion with tricortical iliac crest bone graft using locking titanium plate in patients with symptomatic cervical radiculopathy or cervical myelo-radiculopathy.

## II. MATERIAL AND METHODS

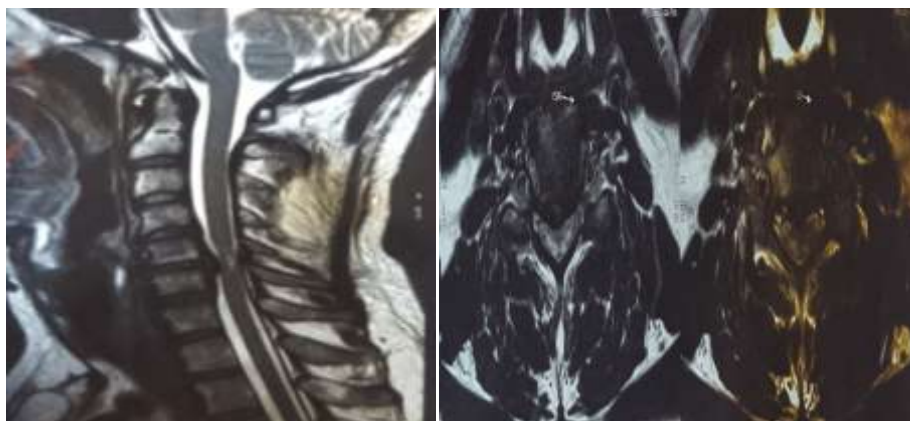In this study we included 59 patients underwent surgery for symptomatic single level cervical radiculopathy or myelo-radiculopathy leading to intractable pain and/or myelopathy. Inclusion criteria consisted of patient with single level disc herniation leading to radiculopathy or myelopathy with or without neurodeficit. All the surgery were carried out by single surgeon team in the period January 2012 to June 2014. Exclusion criteria were 2 or more level disc herniation, patients with history of trauma, infection or malignancy and patients with history of previous surgery.

All patients were assessed clinically and radiologically including x ray ,CT scan and MRI preoperative and post operatively. The follow up were done monthly for first three month then at every 3 months for 1 year, then yearly upto 5 years. Clinical evaluation consisted of detailed history followed by complete neurological examination, VAS score and Neck Disability Index (NDI) (8,9). Odom's criteria was also used post operatively to evaluate the clinical outcome post operatively (10). Cervical spine X ray were done in antero posterior and lateral views pre operatively and post operatively at every follow up to evaluate the fusion, and to assess sagittal segmental alignment (SSA) and sagittal alignment of cervical spine (SACS) on lateral radiographs. SSA (focal angulation) is calculated by drawing perpendicular lines from upper border of superior vertebrae and lower border of inferior vertebrae of the involved disc space and calculating angle of deviation between these intersecting lines. Similarly, SACS (Global angulation) is measured between upper border of C2 and lower border of C7 (11,12).

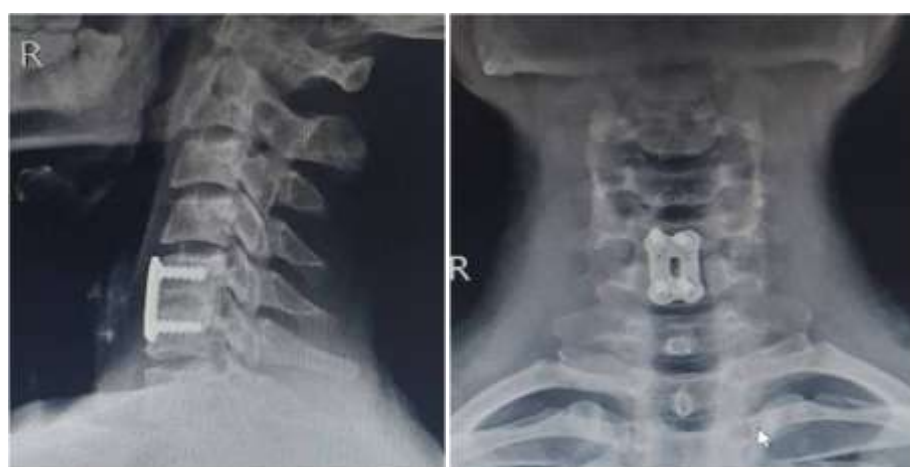

**Fig. 1:** Showing measurement of SACS and SSA

All patients underwent surgery in form of anterior cervical discectomy and fusion with tri cortical iliac crest bone graft and plating with titanium locking plate. Surgery was done in supine position under general anaesthesia. Gardner-Wells tongs were applied to provide traction to the cervical spine in slightly hyper-extended position as and when required. Surgical approach to the cervical spine consisted of an oblique incision on left side of the skin which is standard Southweck Robinson's approach (13). After skin incision, platysma was incised and medial border of sternocleidomastoid muscle was identified. After this the deep cervical fascia was divided. Trachea and esophagus are retracted medially and sternocleidomastoid with neurovascular bundle retracted laterally to expose the cervical spine. The level is confirmed with the help of fluoroscopy. Complete discectomy along with removal of osteophyte was done at the desired level. Cervical pin distractor was used to achieve interbody distraction to excise posterior osteophytes and posterior longitudinal ligament. Tri-cortical iliac crest bone graft is harvested from the same sided iliac crest. The harvested iliac crest bone graft is trimmed to appropriate size and inserted between the vertebral bodies in extension to maintain cervical lordosis. A locking titanium plate was fixed to provide stability. Post operatively soft cervical collar is used for 3 months.



**FIG. 2A:** Pre-operative MRI showing PIVD C5-C6 with cord compression.



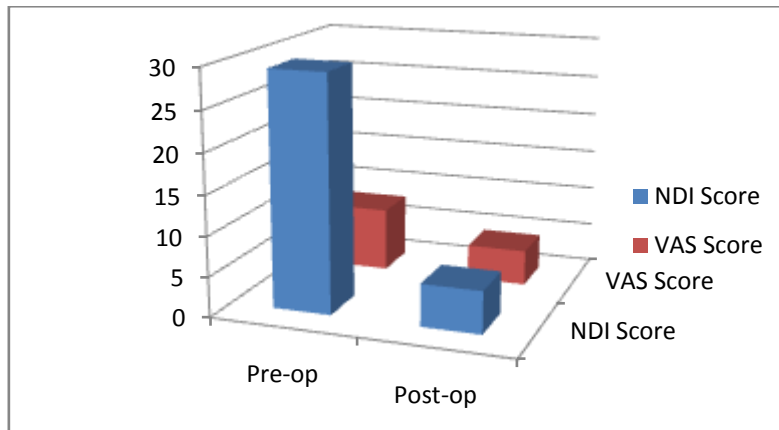
**Fig. 2B:** Post-operative plain radiograph at 2 years follow up showing good fusion.

### **III. Results**

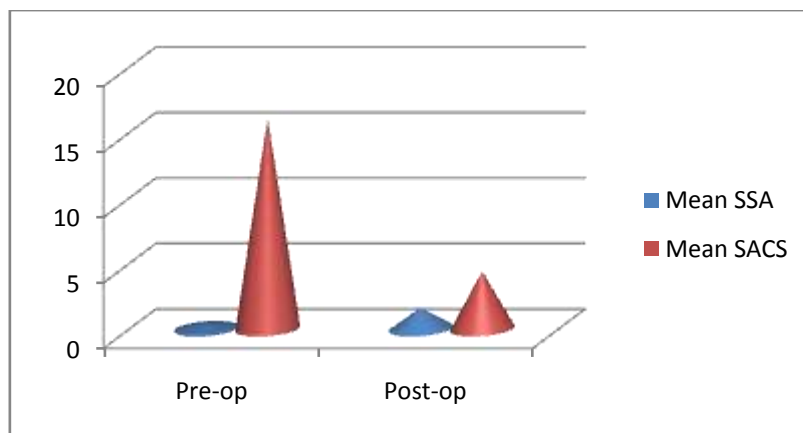
59 patients underwent surgical intervention in the form of anterior cervical discectomy and fusion with tri-cortical iliac crest bone graft and locking titanium plate including 37 males and 22 females with mean age of presentation was 46 years (range 31- 75years). The mean surgical time was 86.98 minutes with the mean blood loss 118 ml. The mean hospital stay was 5.82 days. 6 patients (10.20%) were operated at C3-4 level, 10 patients (17.10%) at C4-5, 32 patients at C5-6 (54%) and 11 patients at C6-7 (18.70%). The mean follow up duration was 27.98 months, maximum was 45 months with minimum follow up duration of 18 months.

The NDI score was 29.28 pre-operatively which reduced significantly to 5.28. There was significant reduction in VAS score post-operatively as compared to pre-operatively . The mean VAS pre-operatively was 7.96 and 1.96 post operatively. The mean SSA was  $0.4^{\circ}$  pre-operatively. 6 months post-operatively the mean SSA was  $1.5^{\circ}$  and at final follow up it was  $1.6^{\circ}$ . The mean SACS was  $16.1^{\circ}$  pre-operatively. The mean SACS was  $20.9^{\circ}$  at 6 months follow up post operatively and  $21.9^{\circ}$  at final follow up. There was increase in SSA and SACS post operatively as compared to pre-operative values in all the patients indicating that there was restoration of cervical lordosis post-operatively. Odom's criteria post-operatively at final follow up was Excellent in 45 patients, Good in 10 and Fair in 4 cases. 12 (20%) patients had adjacent segment degeneration, but none had clinical symptoms pertaining to the same.

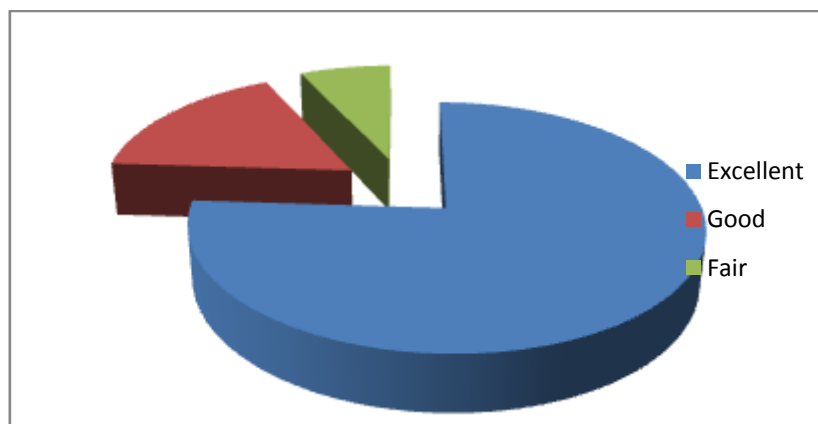
There were few complications in our study. There was transient dysphagia in 10 cases in immediate post operative period which settled down in 3-4 days postoperatively. Radiological signs of fusion were seen in all patients after a mean duration of 3 months .In 2 pts fusion occurs at 5 month .One patient showed delayed fusion, which showed complete fusion after a period of 8 months. One patient also had non union but didn't have any clinical signs and symptoms for same.



**Chart 1:** Pre-operative and Post-operative Mean NDI score and Mean VAS score.



**Chart 2:** Comparison of mean SSA and mean SACS on Pre-operative and post-operative plain Radiographs.



**Chart 3:** Final outcome of operated patients according to Odom's criteria.

#### IV. Discussion

Failure of conservative management for 6-8 weeks in patients with symptomatic cervical radiculopathy and /or myelo-radiculopathy needs surgical intervention in form of anterior cervical discectomy and fusion. The aim of the surgery is to provide pain relief, prevent further deterioration of neurological symptoms and maintenance of cervical lordosis. (14) In our series all the three aims were achieved.

In our series all patients had significant reduction in VAS score and NDI score post operatively, indicating that there was significant reduction in pain which helps to improve the overall lifestyle. The improvement in VAS score and NDI score is because of good decompression, good fusion and well placed implants. Odom's criteria also indicates that patient in our study had significant improvement in lifestyle post operatively.

In our series, in all patients the SSA and SACS were maintained in early post operative period and at final follow up. There was change in SSA and SACS at 6 months and at final follow up, but the change was not

significant. SSA and SACS are good indicators to evaluate the alignment of cervical spine as well as the adequacy of fusion post operatively (12). There was no graft dislodgement, graft resorption, graft collapse and implant loosening which also indicates good fusion.

In 12 (20%) patients, post-operatively there was adjacent segment degeneration adjacent to the operated level. However, the degenerative changes are due to normal aging process and not particularly because of surgery with locking cervical plates. The degenerative changes in adjacent segment were noted more in patients who already had degenerative changes at that segment pre-operatively as compared patients with normal adjacent segment. Adjacent segment degeneration as evident on X rays didn't required any further surgical intervention and all patients having it settled down with conservative trial.

## V. CONCLUSION

Anterior cervical discectomy and fusion with tri-cortical iliac crest bone graft using titanium locking plate is a good and effective method for patients with single level disc herniation and cervical spondylosis leading to cervical radiculopathy and/or myelo-radiculopathy. The good outcome in our series was because of good decompression, good fusion and maintenance of cervical lordosis as shown by Segmental Sagittal Alignment and Sagittal Alignment of Cervical Spine.

**ACKNOWLEDGEMENTS:** Nil.

## REFERENCES

- [1]. Donald R M, Christopher M C, Jonathan K G Cervical spondylosis with spinal cord encroachment: should preventive surgery be recommended? *Chiropr Osteopat.* 2009; 17: 8.
- [2]. Mohamad B, Dimitrios M, Mohamed M, Rafael de la GR, Daniel M S, Timothy F W, Jean P W, Ziya L G, Ali B. Long-term patient outcomes after posterior cervical foraminotomy: an analysis of 151 cases.
- [3]. Mayur M K, Arjun B, Vikram S, H. Ravindranath R, Deepak H: A Prospective Study of the Functional Outcome of Anterior Cervical Discectomy With Fusion in Single Level Degenerative Cervical Disc Prolapse. *J Clin Diagn Res.* 2016 May; 10(5): RC01–RC04.
- [4]. Coskun Y, Nuriye G O,<sup>1</sup> Hilmi O O, Ayhan K, Mehmet S, Ibrahim B A, Hakan Y,<sup>3</sup> Mustafa K C, Mmet O Y, Umit K. Cervical disc hernia operations through posterior laminoforaminotomy. *J Craniovertebr Junction Spine.* 2016 Apr-Jun; 7(2): 91–95.
- [5]. Haley E M, W. Jeffrey C, Carter S G, John E O. Single-level anterior cervical discectomy and fusion versus minimally invasive posterior cervical foraminotomy for patients with cervical radiculopathy: a cost analysis. *Neurosurg Focus* 37 (5):E9, 2014.
- [6]. Kyung J S, Byeong Y C. Current Concepts of Anterior Cervical Discectomy and Fusion: A Review of Literature. *Asian Spine J* 2014;8 (4):531-539.
- [7]. S. Litrico, N. Lonjon, G. Riouallon, A. Cogniet, O. Launay, J. Beaurain, A. Blamoutier, H. Pascal-Mousselard.. Adjacent segment disease after anterior cervical interbody fusion. A multicenter retrospective study of 288 patients with long-term follow-up. *Orthopaedics & Traumatology: Surgery & Research* 100 (2014) 305–309.
- [8]. Bodian CA, Freedman G, Hossain S, Eisenkraft JB, Beilin Y. The Visual Analog Scale for Pain: Clinical Significance in Postoperative Patients. *Anesthesiology* 2001; 95:1356-61.
- [9]. Vernon, H. & Mior, S. The Neck Disability Index: A study of reliability and validity. *Journal of Manipulative and Physiological Therapeutics* 1991; 14:409-15.
- [10]. Cesare F, Danilo L, Matteo N, Alberto D M, Luca D, Vincenzo D, Sandro G. Cervical disc herniation and cervical spondylosis surgically treated by Cloward procedure: a 10-year-minimum follow-up study. *J Orthopaed Traumatol* (2010) 11:99–103.
- [11]. Mustafa G, Murat C, Bahadir A, Adem B, Tarik A, Ozbey S, Oznur K, Davut C, Mehmet T. Comparison of Anterior Cervical Discectomy Fusion Techniques: Bladed and Non Bladed PEEK Cages. *Turk Neurosurg* 26(3):404-410, 2016.
- [12]. C Faldini, M Chehrassan, M T Miscione, F Acri, M d'Amato, C Pungetti, D Luciani, S Giannini. Single-level anterior cervical discectomy and interbody fusion using PEEK anatomical cervical cage and allograft bone. *J Orthopaed Traumatol* (2011) 12:201–205.
- [13]. Soo-An Park, Je-Hun Lee, Yong-Seok Nam, Xiaochun An, Seung-Ho Han, and Kee-Yong Ha. Topographical anatomy of the anterior cervical approach for c2-3 level. *Eur Spine J.* 2013 Jul; 22(7): 1497–1503.
- [14]. Lei X, Ming X L, Jun Z, Jin Z, Ning N D, Massimiliano V. Anterior cervical discectomy and fusion with a compressive staple of C-JAWS. *Br J Neurosurg.* 2016 Jun 22:1-5.