



Research Paper

MANAGEMENT OF A LARGE PERIRADICULAR LESION: COMBINATION OF SURGICAL AND NONSURGICAL METHODS AND 4 YEARS FOLLOW-UP.

Abidin Talha Mutluay¹, Merve Safa Mutluay²

¹Dr, Kirikkale University, Faculty of Dentistry, Department of Restorative Dentistry

²Dr, Kirikkale University, Faculty of Dentistry, Department of Pediatric Dentistry

Received 28 October, 2016; Accepted 12 November, 2016 © The author(s) 2016. Published with open access at www.questjournals.org

ABSTRACT: Inflammatory periapical lesions are one of the major complications of dental injuries. Here we report a case of large cyst-like periradicular lesion from the apices of 31, 41, 42 in an 18-yr-old boy that was managed by using nonsurgical and surgical endodontic methods. During endodontic procedure, 2.5 % sodium hypochlorite solution was used for irrigation and calcium hydroxide paste was used for the intracanal dressing. Because of presence of large periapical lesion a combined approach was planned. The lesion was curetted surgically and the canal treatment was completed in the same session using canal paste with gutta-percha and AH-plus. Considerable radiographic resolution of the periapical lesion was observed 12 months after the root canal filling and no symptoms were recorded at 48 months review.

Keywords: Dental trauma, endodontic surgery, endodontic treatment, root canal therapy.

I. INTRODUCTION

Traumatic dental injuries are frequently seen in children and young adults. Depending on the severity and the subsequent of trauma, dental pulp may lose vitality and irritants from necrotic pulp tissue initiate inflammatory events in the apical region.^[1] Once the decision has been made to retain the tooth, there are several choices for treatment. These can be grouped together into either nonsurgical or surgical endodontic treatments. The surgical options include; periradicular curettage, apical root resection (with or without root filling), root amputation or hemisection, and intentional replantation.^[2-3]

It is reported that all inflammatory periapical lesions should be initially treated with conservative nonsurgical procedures.^[4] Surgical intervention is recommended only after nonsurgical treatment.^[5] Non-surgical management of large periapical lesion may fail to respond if infection has not been controlled. In this instance, a situation arises that will require both nonsurgical and surgical types of treatment to provide healing.^[6,7]

The following case report describes the favorable clinical outcome of a large periapical cystic lesion in the mandibular incisor region induced by trauma, treated with a combination of nonsurgical and surgical endodontic methods.

II. CASE REPORT

A healthy 18-years-old male patient admitted to our clinic with complaints of severe pain and intraoral swelling in the anterior region. Dental history indicated that the lower anterior region was exposed to a trauma about a year ago. Clinical and radiologic examination revealed complicated crown fractured teeth and a large lesion in the periapical region of teeth 31, 41, 42 (Figure 1a) and mobility and sensitivity on vertical percussion in teeth 31. Intraoral examination revealed a minor firm swelling of the vestibule above the teeth. Electric pulp test and cavity test exhibited negative results. All information about the treatment procedure was given and written consent was obtained from the patient.

2.1. Endodontic treatment

Initial investigation of the root canal system in all incisors was performed with a size 10 K-file (Dentsply, Maillefer) and working lengths verified. Extirpation was performed in all three teeth in order to relieve pain and symptoms. Instrumentation was performed by Flexo-File (Dentsply, Maillefer, Switzerland) #15-40, using step-back technique, accompanying with copious irrigation with 2.5% sodium hypochlorite and

*Corresponding Author: Abidin Talha Mutluay¹

¹Dr, Kirikkale University, Faculty Of Dentistry, Department Of Restorative Dentistry

sterile saline solution between instruments. Root canals were dried with sterile paper points and the teeth were restored temporarily. At second session, calcium hydroxide (Ca(OH)₂) dressing was used to achieve antibacterial effect in the root canal (Figure 1b). To our regret, the patient admitted to our clinic with drastic pain two weeks later. Therewith, due to presence of cyst-like large periapical lesion, the treatment procedure was changed and a surgical endodontic approach was planned.

2.2.Surgical Management

The lesion was curetted surgically and root canal treatment was completed in the same session using Gutta-Percha (SPI Dental Mfg, Inc, Korea) and AH-plus sealer (Dentsply, Weybridge, UK) (Figure 1c). Root edges of the affected teeth were resected and the teeth had been permanently restored with composite resin systems (Single Bond Universal /Filtek Supreme-3M ESPE, USA). The patient was reminded about the necessity of oral hygiene procedures and recalled for a control visit 2 weeks later. At 6-, 12-, 24-, 48- months follow up, the affected teeth were evaluated clinically, it was found that all three teeth were asymptomatic, non-sensitive to percussion and clinical appearance was acceptable. Radiologic evaluation revealed a complete recovery in periapical lesion (Figure 2a-d).

III. DISCUSSION

After dental trauma, treatment planning should be based on biologic considerations.^[6] The clinician should evaluate clinical findings such as changes in tooth color, absence of swelling, sensitivity to thermal or electrical stimuli and radiographic periapical inflammatory changes.^[7,8] In the present case, because of clinical symptoms and large radiolucent lesion beyond the apex, we concluded that traumatized mandibular incisors pulp tissue was nonvital. Severity of the patient's symptoms is another important consideration. If the patient has drastic pain and acute symptoms, infection should be controlled with intracanal drainage and antimicrobial dressing.^[9] Proper biomechanical preparation followed by calcium hydroxide medication renewed periodically represents a nonsurgical approach to resolve extensive inflammatory periapical lesions.^[10] Sjögren et al.^[11] found that the use of calcium hydroxide as a dressing for 1 week efficiently eliminates bacteria in the root canals. It has also been reported that treatment with calcium hydroxide resulted in a high frequency of periapical healing.

Necrotic pulp tissue provides nutrients for pathogenic bacteria to grow and form a periapical lesion.^[6] There are times when the clinician may not be able to achieve the complete elimination of microorganisms from the canal space endodontically, and complete obturation may not be possible. Endodontic surgery is indicated in cases of failure in nonsurgical therapy (presence of clinical signs and symptoms combined with persistent radiolucency).^[6,12] In the present case, nonsurgical and surgical therapy's combination was planned to enhance the success of treatment and lesion size.

Numerous studies have examined the outcome of apical surgery and the results vary considerably.^[6,13,14] This variability may reflect actual outcome differences or reflect variations in case selection techniques, recall periods, and methodology. The reported healing rates of nonsurgical retreatment range between 74% and 98%,^[15] but with apical surgery alone, only 59% heal completely.^[16] When apical surgery is preceded by nonsurgical endodontic treatment, the incidence of complete healing rises to 80%.^[5,16] To achieve satisfactory periapical wound healing, surgical removal of an apical true cyst must include elimination of root canal infection.^[3,7] In the present case because of large size of the periapical lesion, radiographic appearance suggesting a cystic lesion and long standing nature of the infection, surgical intervention was made. Considerable radiographic resolution of the periapical lesion was observed 12- months after the treatment and no symptoms were recorded at 48 months review (Figure 2 a-d). Radiographic signs, such as density change within the lesion and trabecular reformation, confirmed healing, particularly when associated with the clinical finding that the teeth were asymptomatic and the soft tissues were healthy.

CONCLUSION

The present clinical report demonstrates the need of a multidisciplinary intervention during the treatment of traumatized teeth. Root canal therapy with intracanal medicament followed by surgical removal of debris and apicectomies proved favorable clinical and radiographic response of cyst-like large periapical lesion. Furthermore, the present case also implicated that long follow-up visits are critically important for all traumatic injuries.

ACKNOWLEDGEMENTS

There are no acknowledgements. All procedures performed in this article involving human participant was in accordance with the ethical standards. This case report was presented at The International Symposium of YJU Faculty of Dentistry, September 2014.

REFERENCES

*Corresponding Author: Abidin Talha Mutluay¹

- [1]. Ivancic JN, Bakarcic D, Fugosic V, Majstorovic M, Skrinjaric I. Dental trauma in children and young adults visiting a University Dental Clinic. *Dent. Traumatol.* 2009; 25: 84–7.
- [2]. Niemczyk SP. Re-inventing intentional replantation: a modification of the technique. *Pract. Proced. Aesthet. Dent.* 2001; 13: 433–9.
- [3]. Lin LM, Huang GT, Rosenberg PA. Proliferation of epithelial cell rests, formation of apical cysts, and regression of apical cysts after periapical wound healing. *J. Endod.* 2007; 33: 908–16.
- [4]. Gutmann JL, Harrison JW. *Surgical endodontics*, 2nd ed. St. Louis: Ishiyaku EuroAmerica; 1994.
- [5]. Nicholls E. *Endodontics*. 3rd ed. Bristol: John Wright Sons Ltd; 1984.
- [6]. Hargreaves KM, Cohen S. *Cohen's pathways of the pulp*. 10th ed. St. Louis: Mosby; 2011.
- [7]. Shah MB, Parmar P. Non Surgical Management of Chronic Periapical Lesion with Calcium Hydroxide Paste - A Case Series. *JIDA* 2011; 5: 8.
- [8]. Çalışkan M, Türkün M. Periapical repair and apical closure of a pulpless tooth using calcium hydroxide. *Oral Surg Oral Med Oral Pathol Oral Radiol Endod* 1997; 84: 683–7
- [9]. Torabinejad M, Kettering JD, McGraw JC, Cummings RR, Dwyer TG, Tobias TS. Factors associated with endodontic inter appointment emergencies of teeth with necrotic pulps. *J. Endod.* 1988; 14: 261–6.
- [10]. Soares J, Santos S, Silveira F, Nunes E. Nonsurgical treatment of extensive cystlike periapical lesion of endodontic origin. *Int. Endod. J.* 2006; 39: 566–75.
- [11]. Sjögren U, Figdor D, Persson S, Sundqvist G. Influence of infection at the time of root filling on the outcome of endodontic treatment of teeth with apical periodontitis. *Int. Endod. J.* 1997; 30: 297–306.
- [12]. Maalouf EM, Gutmann JL. Biological perspectives on the non-surgical endodontic management of periradicular pathosis. *Int. Endod. J.* 1994; 27: 154–62.
- [13]. Zuolo ML, Ferreira MO, Gutmann JL. Prognosis in periradicular surgery: a clinical prospective study. *Int. Endod. J.* 2000; 33: 91–8.
- [14]. Wang N, Knight K, Dao T, Friedman S. Treatment outcome in endodontics - The Toronto Study. Phases I and II: apical surgery. *J. Endod.* 2004; 30: 751–61.
- [15]. Orstavik D, Pitt-Ford TR. *Essential Endodontology: Prevention and treatment of apical periodontitis*. 2nd ed. New York: Wiley-Blackwell; 2008.
- [16]. Friedman S, Mor C. The success of endodontic therapy – healing and functionality. *Calif. Dent. Assoc. J* 2004; 32: 493–503.

Figure Legends

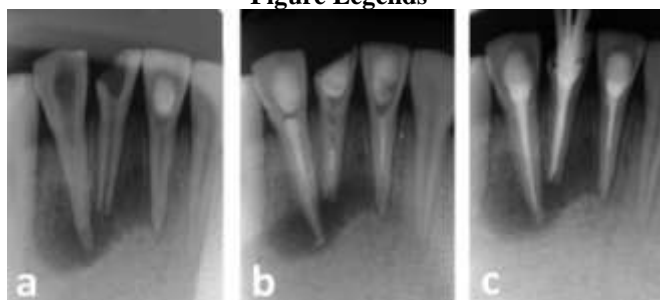


Figure 1: Preoperative periapical radiograph (a). Radiograph after placement of with calcium hydroxide dressing (b). Periapical radiograph after completion of root canal treatment (c).

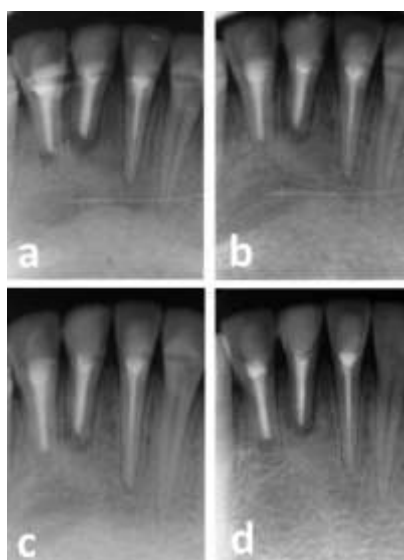


Figure 2: 6 months control radiograph showing healing of the apical lesion. Note a remarkable decrease of the lesion radiolucency (a). Periapical radiograph 12 months after surgery (b). Periapical recall radiograph 24 months after surgery (c). Periapical control radiograph at 48 months control (d).