



MERMAID SYNDROME

Deepali Raina¹, Nivedita Prashar^{2*}, Indu kaul³, Gopal Sharma⁴

¹Senior Resident, Fortis research Hospital, Gurgaon

²Medical Officer, SMGS HOSPITAL GMC Jammu

³Professor and HOU, Department of obs and gynae, SMGS Hospital

⁴Senior Resident, Department of Surgery, GMC Jammu

Department of obstetrics and gynaecology, SMGS Hospital, GMC JAMMU

Received 29 March, 2016; Accepted 20 April, 2016 © The author(s) 2015. Published with open access at www.questjournals.org

ABSTRACT:- Congenital anomalies have emerged as an important cause of perinatal mortality as well as infant morbidity and mortality. The existence of such an anomaly evokes an emotional parental response and parents often feel guilty as it is a state of mental shock for them. Mermaid syndrome is one of the rarest anomaly associated with fused limbs and many other associated other system anomalies. Prognosis of such a baby is very poor. Only few cases have been reported till date.

KEYWORDS:- anomaly, Congenital, Limbs, Fetus

I. INTRODUCTION

Sirenomelia, alternatively known as Mermaid Syndrome, is a very rare [congenital deformity](#) in which the legs are fused together, giving them the appearance of a [mermaid's](#) tail. This syndrome was originally stated by Rocheasand Palfyain in 16th century. It occurs in about 1 in 100,000 livebirths¹. It is also associated with multiple anomalies like renal agenesis, ambiguous external genitalia, imperforate anus, blind intestinal loop and single umbilical artery. Occasionally, double inferior venacava, dextrocardia and angiomatous lumbosacral myelocystocele are reported as well. Most of the Sirenomelia come to an end as stillbirth². Only a few are born alive and survival beyond few hours after delivery is extremely rare. About 300 cases have been reported in the world literature so far³.

CASE

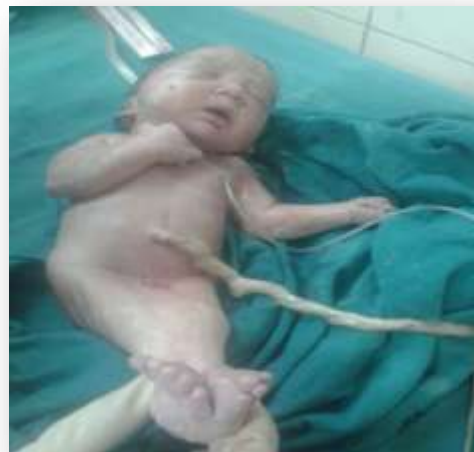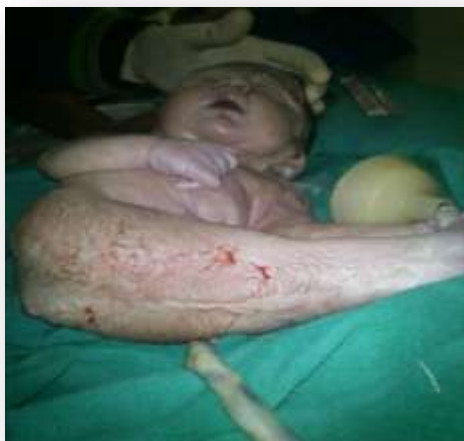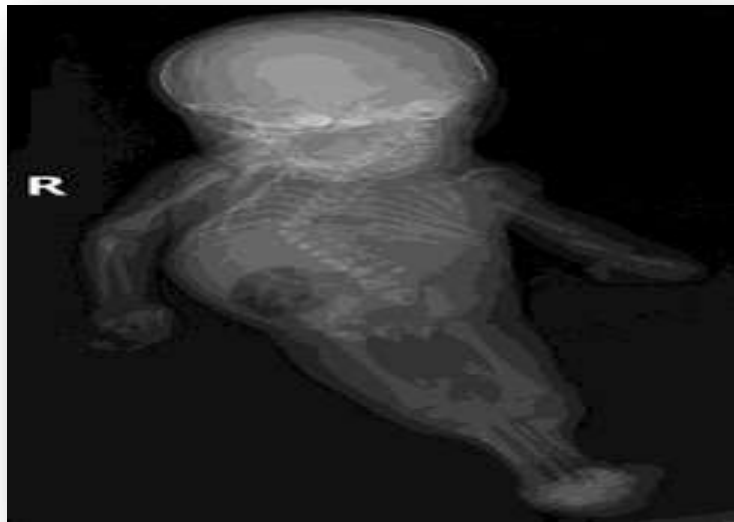
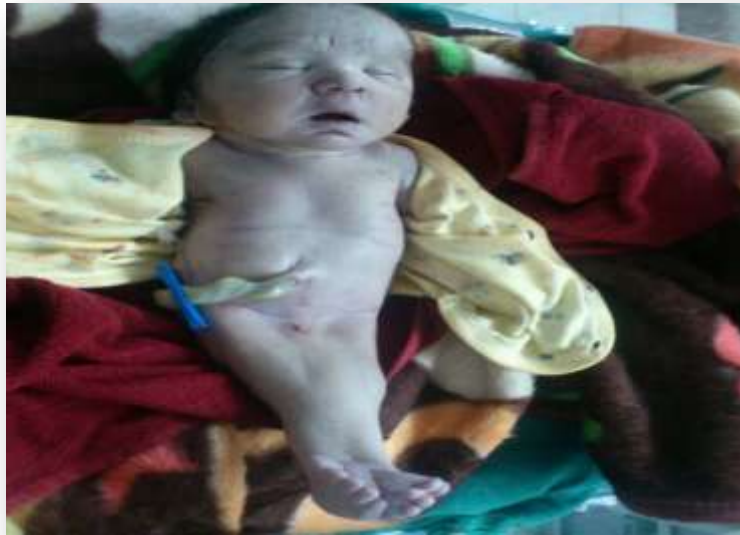A 24 year old primigravida reported to the outpatient department with complaints of decreased perception of fetal movements. She was at 36 weeks of gestation, Rh +ve, normotensive, euglycemic (blood sugar fasting 87 mg/dl) with mild anemia (Hb 9.5 gm%). Hers was a consanguineous marriage with a first cousin (maternal). There was no personal or family history of Diabetes Mellitus or congenital anomalies in relatives. No medications except occasional supplemental iron and calcium were taken by the patient. There was no history of substance abuse. No history of fever or rash during pregnancy. Patient underwent erratic antenatal checkups. No mid-trimester anomaly scan was available.

On examination, fundal height was corresponding to gestational age of 34 weeks, breech presentation with clinically decreased liquor. She was subjected to sonography which confirmed the clinical findings of breech presentation and severe Oligohydramnios(no single measurable pocket of amniotic fluid); moreover, fetal kidneys, urinary bladder and stomach were not visualized. Since there was severe oligohydramnios, the sonographer was not able to precisely assess both lower limbs and lumber spines. USG also revealed hepatomegaly.

An elective LSCS was performed on her in view of breech presentation. Intra-operatively liquor was grossly reduced but clear. Placenta weighted 370 gms. Both the lower limbs of the baby were fused, feet were separate (sirenomeliadipus). It had 'Potter facies'. There was no anal opening. External genitalia were replaced by a small tag. The umbilical stump revealed just one artery and one vein. Apgar score at birth was 6/10 and 8/10 at 5 minutes. The baby weighted 2.25 kg and was shifted to Neonatal intensive care unit where the baby died after a few hours.

*Corresponding Author: ²Nivedita Prashar
²Medical Officer, SMGS HOSPITAL GMC Jammu

Unfortunately the parents did not give consent for autopsy or any other investigation of the mermaid baby due to religious and socio-cultural constrains.



II. DISCUSSION

The precise etiology of sirenomelia is not known. Many theories have been proposed but none of these is conclusive.

Possible association with maternal diabetes, vitamin A toxicity and lead or cadmium exposure has been proposed³. Our patient had no personal or family history of diabetes; neither there was any known teratogenic drug or radiation exposure.

Some describe it as a part of caudal regression and VACTERL syndrome⁴.

Neural tube distension, cloacal malformation, and caudal somite destruction have also been suggested as possible pathologic events.

Stevenson et al³ proposed the role of the persistent vitelline artery, which diverts blood from the abdominal aorta and caudal structures to the placenta, causing all distal visceral anomalies because of a vascular stealing phenomenon.

Langer et al⁴ have suggested a defect of the blastogenesis after the observation of a case of sirenomelia associated with "situsinversus."

The poor prognosis is usually forecasted depending on the kind of visceral anomalies present. Death usually results from renal agenesis or dysgenesis, as happened in our case.

In general also it is known that consanguinity increases the prevalence of rare genetic congenital anomalies and nearly doubles the risk for neonatal and childhood death, intellectual disability and serious birth anomalies in first cousin unions⁵. The parents of our Mermaid baby too were first cousins (maternal).

Prenatal diagnosis of sirenomelia is possible by demonstrating the fused femur, decreased distance between two femurs, decreased or absent mobility of the two lower limbs with respect to each other, structural and visceral abnormalities and oligohydramnios. It is almost a universally lethal entity and prenatal diagnosis on USG is desired so that termination of pregnancy can be offered at the earliest to save mothers from physical and emotional repercussions. This can be achieved by emphasizing the importance of regular antenatal checkups and Ultra-sonography scans around 20 weeks to rule out anomalies. Myths and reservations regarding such anomalous babies also need to be addressed by proper education and awareness among general public.

REFERENCES

- [1]. Martinez-Frias ML, Garcia A, Bermejo E. Cyclopia and sirenomelia in a liveborn infant. *J Med Genet.* 1998;35 :263– 4
- [2]. Nosrati A, NaghshvarF,Torabizade Z, Emadian O. Mermaid syndrome, Sirenomelia: A case report and review of literature. *J Pediatr Rev.* 2013;1(1)64-9
- [3]. Taori KB, Mitra K, Ghonga NP et al. Sirenomelia sequence (mermaid): Report of three cases. *Indian J Radiol Imaging* 2002;12:399-401
- [4]. Messineo A, Innocenti M., Gelli, R et al. Multidisciplinary surgical approach to a surviving infant with sirenomelia. *Pediatrics.* 2006; 118, e220–3
- [5]. WHO Fact sheet. Congenital anomalies. Updated Jan 2014. Available from <http://www.who.int/mediacentre/factsheets/fs370/en/>