



Non-Surgical Repair of A Perforation Defect-A Case Report

Dr.Pradnya V. Bansode¹, Dr. Seema D.Pathak², Dr.M.B Wavdhane³,
Dr.Shirish Khedgikar⁴, Dr.Shraddha Gite⁵

¹Professor & Head of Department of Conservative Dentistry and Endodontic,
²Associate Professor, Associate Professor³, Assistant Professor⁴, Post Graduate student⁵.

Received 31 Jan. 2017; Accepted 18 Feb. 2017 © The author(s) 2017. Published with open access at www.questjournals.org

ABSTRACT: Iatrogenic root perforations, which may have serious implications, occur in approximately 2-12% of endodontically treated teeth. Root perforation repair has historically been an unpredictable treatment modality, with an unacceptably high rate of clinical failure. Successful management of root perforations is dependent on early diagnosis of the defect, location of the perforation, choice of treatment, materials used, host response, and the experience of the practitioner. This case report presents the successful management of a nonsurgical iatrogenic perforation repair.

Keywords: host response, iatrogenic, root perforation,

I. INTRODUCTION

Root perforation is an artificial communication between root canal system and the supporting tissues of teeth or the oral cavity.[1] Perforation is defined as mechanical or pathological communications between the root canal system and the external tooth surface [2]. Once a perforation has been diagnosed, treatment must be rendered to seal the perforation site effectively to minimize injury and prevent contamination of the surrounding periodontal attachment apparatus. Although successful treatment and prognosis depend on many factors, the location of the perforation and the time lapse between exposure and repair are the two most important factors for determining the treatment and prognosis of the tooth. The injury to the periodontium results in the development of inflammation, destruction of periodontal fibers, bone resorption, formation of granulomatous tissue, proliferation of epithelium, ultimately in the development of a periodontal pocket, mobility and finally loss of tooth. Anatomical variations are not anticipated during access preparation and as a result of misalignment of the bur with the long axis of the root, crowns of many teeth are frequently perforated. [3] Inappropriate post space preparation for permanent restoration of endodontically treated teeth is another common iatrogenic cause of iatrogenic perforation.[4] Endodontic mishaps are not very uncommon and in that perforations are no exception. According to Kvinnsland et al [4] 53% of iatrogenic perforations occur during insertion of posts and the remaining 47% are induced during routine endodontic treatment.

Various materials have been used in managing perforations, including zinc oxide–eugenol, amalgam, calcium hydroxide, IRM, super EBA, composite resin, glass ionomer and resin modified glass ionomer. The ideal material for treating radicular perforations should be nontoxic, non-absorbable, radiopaque, and bacteriostatic or bactericidal; it should also provide a seal against microleakage from the perforation [5].

Mineral trioxide aggregate (MTA) has all of these characteristics and has been applied with good outcomes in root-end surgery, direct pulpal coverage, apexification, radicular resorption, repair of lateral radicular and furcal perforation. [6]

The present case report illustrates the successful management of an iatrogenic perforation at a cervical level on the labial aspect of an upper central incisor.

II. CASE REPORT

A 32yr old male patient with non-contributory medical history reported to the department with pain in upper front tooth region since 1month.He gave an history of fall from bike 1yr back and also gave history of root canal treatment (RCT) having been attempted elsewhere on that tooth, about one month prior which was unsuccessful . Clinical examination revealed an access preparation been attempted in tooth no#12 ,tenderness

*Corresponding Author: Dr.Pradnya V. Bansode

¹Professor & Head of Department of Conservative Dentistry and Endodontic,

on percussion and ulceration in attached gingiva at tooth no #11,#12 region was seen .Perforation was seen on cervical third of labial surface with tooth no #12 .(Fig-1)

Radiographic examination revealed a radiolucent periapical lesion with tooth no # 11,#12 and Perforation defect of 4-5 mm was seen extending above alveolar crest with tooth #12.(Fig-2) An iatrogenic root canal perforation in the labial aspect was suspected and was confirmed by intracanal exploration. After administration of the local anesthetic (2% Lignocaine with 1:100,000 epinephrine solution, root canal was renegotiated and proper biomechanical preparation and irrigation was done. Root canal treatment of both maxillary right central and lateral incisor was initiated.Working length was determined(Fig-3). Biomechanical preparation was done with both tooth no #11.#12. The access cavity and perforation defect were flushed thoroughly with normal saline and dried. Mineral trioxide aggregate (MTA – ANGELUS; Peterborough, UK) was mixed and carried to the perforation site with the help of a carrier and packed with an appropriately fitted plugger. 2% GP point, size 60 was placed in the canal as a template to maintain the patency of the canal, Repair of the perforation was carried out by progressive placement and packing of small increments of the Mineral Trioxide Aggregate. The gutta percha point was removed and moist cotton pellets were placed over the Mineral Trioxide Aggregate, and the perforation was sealed with white MTA.

After initial setting of MTA, the root canal was obturated by lateral condensation technique without disturbing the MTA(Fig-4) . At the 1 week follow-up, the patient was asymptomatic. Patient was kept on regular follow up.1yr follow up showed healing of periapical area associated with tooth no#11,12.(Fig-5)

III. DISCUSSION

In the present case, the perforation was present in the distolateral cervical area of the upper right lateral incisor, which might have been caused during access preparation while locating canal orifice and flaring coronal third of the root canal. Sudden appearance of blood from canal is first sign of perforation. To avoid such an occurrence, preparation of the access cavity should be carried out with regard to the anatomy of the tooth, and help of the microscope should be taken, to locate the canal orifice. Various factors affect the prognosis of perforation repair such as location, size, visibility, accessibility, time, associated periodontal condition and strategic importance of tooth and esthetics.

In present case the perforation is located coronal to alveolar crest, in such cases prognosis is poor because of communication with oral cavity, epithelial migration and periodontal pocket formation. The defect was around 4-5mm supracrestal as the perforation size was small less tissue destruction and inflammation was there, thus prognosis expected is better. Visibility and accessibility also affects the perforation repair. In present case perforation defect was quite visible without need of dental operating microscope or surgical intervention. Time also plays an important role in repair otherwise further loss of attachment and sulcular breakdown will occur. Associated periodontal condition and strategic importance of tooth also influence the treatment plan of perforation. In present case the attachment apparatus is intact without pocket formation, so non-surgical repair was done. Esthetics influences the perforation repair and material to be used for repair of the perforation.

MTA was selected as the material of choice in the present case because of its good sealing ability, biocompatibility, bactericidal effect, radio-opacity and its successful use as root-end filling material, in surgical repair, pulp capping, apexification, radicular resorption and perforations [6]. Two types of MTA are available, Grey and white. White MTA was preferred in this case since it is associated with the development of cementoblasts and keratinocytes [7], [8]; though both prove to be good in many perforation cases.

In the present case Incremental placement of restorative material like the Mineral Trioxide Aggregate was made over the perforation site. As the perforation was in the cervical third of the root and sufficient access was available through the pulp chamber,the perforation was repaired nonsurgically.[9]In the present case the perforation was in the cervical third, but yet prognosis was favorable even after one year.

IV. FIGURES

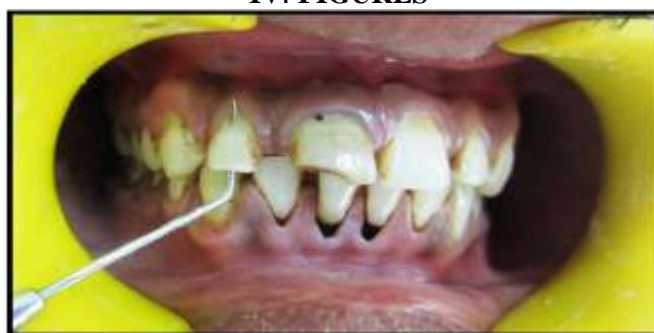

Fig-1 Perforation was seen on cervical third of labial surface with tooth no #12

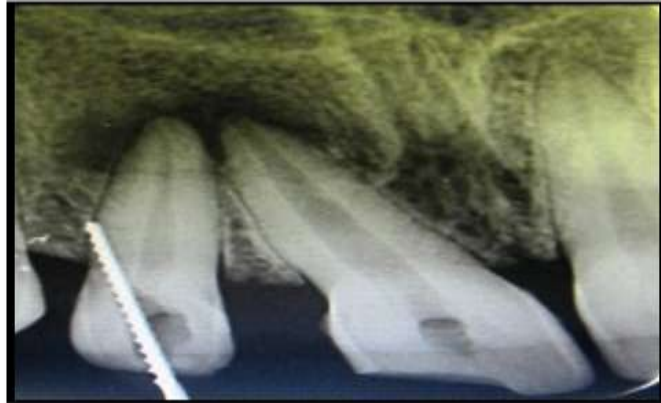

Fig-2 Perforation defect of 4-5 mm was seen extending above alveolar crest with tooth #12

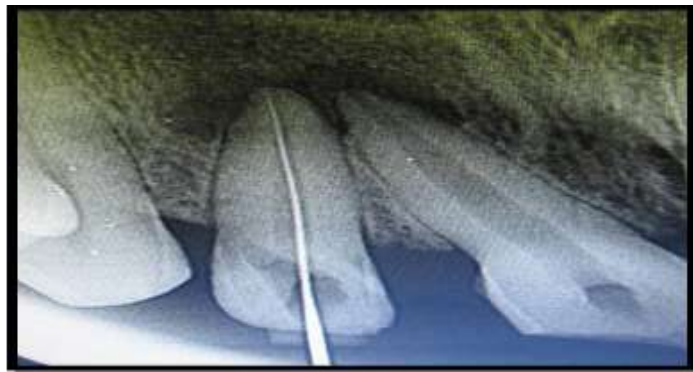


Fig-3 Working length was determined

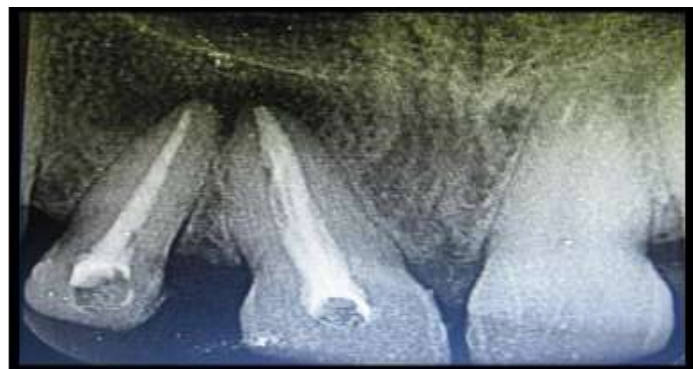


Fig-4 Sealing of perforation defect with MTA

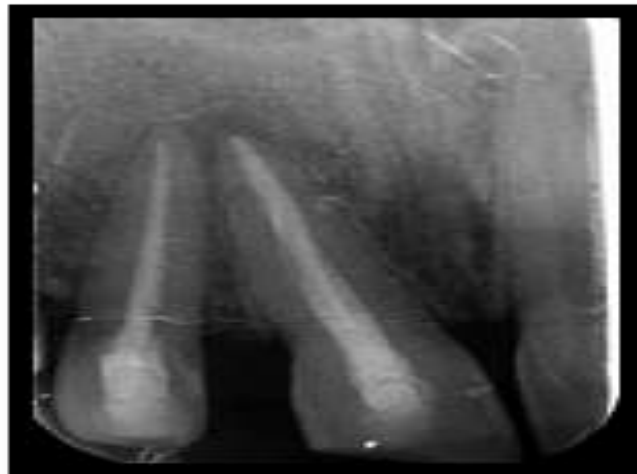

Fig 5-Follow up after 1yr showing healing of periapical area

IV.CONCLUSION

Training, practice, and technology allow clinicians to expand their abilities greatly in endodontic treatment. Correction of procedural errors can now be performed with a higher degree of clinical confidence by using a Dental Operating Microscope. Although the prognosis is generally better for smaller lesions, the location of perforation at critical area was a greater challenge, and successful use of MTA with the use of adjuvant periodontal dressing played key role in successful outcome of the treatment. MTA is a remarkable material in the hands of dentists to deal such endodontic mishaps successfully that are previously regarded as hopeless.

REFERENCES

- [1]. Fuss Z, Trope M. Root perforations: Classification and treatment choices based on prognostic factors. *Endod Dent Traumatol* 1996;12:255- 64
- [2]. Glossary of Endodontic Terms. American Association of Endodontists, (Chicago IL, 2003)
- [3]. Gutmann JL, Dumsha TC, Lovdahl PE. *Problem Solving in Endodontics*. (Mosby, 2006)
- [4]. Kvinnsland I, Oswald RJ, Halse A, Grønningsaeter AG. A clinical and roentgenological study of 55 cases of root perforation. *Int Endod J* 1989;22:75- 84
- [5]. De-Deus G, Reis C, Brandão C, Fidel S, Fidel RA. The ability of Portland cement, MTA, and MTA Bio to prevent through-and-through fluid movement in repaired furcal perforations. *J Endod*, 33(11), 2007, 1374–7.
- [6]. Torabinejad M, Chivian N. Clinical application of mineral trioxide aggregate. *J Endod*, 25(3), 1999, 197–205
- [7]. Oviir T, Pagoria D, Ibarra G, Geurtsen W. Effects of gray and white mineral trioxide aggregate on the proliferation of oral keratinocytes and cementoblasts. *J Endod*, 32(3), 2006, 210–3.
- [8]. Annamalai S, Mungara J. Efficacy of mineral trioxide aggregate as an apical plug in non-vital young permanent teeth: preliminary results. *J Clin Pediatr Dent*. 35(2), 2010, 149-55.
- [9]. Roda RS. Root perforation repair: Surgical and nonsurgical management. *Pract Proced Aesthet Dent*. 2001;13:467–72.