



MB2 In Maxillary Second Molar – Two Case Reports

Dr. Ankush Jasrotia¹, Dr. Nidhi Sharma²

Received 16 Mar, 2017; Accepted 08 Apr, 2017 © The author(s) 2017. Published with open access at www.questjournals.org

ABSTRACT: *The Presence Of A Second Canal In The Mesiobuccal Root (MB2) Of Maxillary Molars Is Well Documented In The Literature. Various Studies Have Shown That The Occurrence Of MB2 Root Canal Is Found To Be More In Maxillary First Molars Than Maxillary Second Molars. Failure To Locate These Extra Canals May Result In Endodontic Failure. This Article Presents Two Case Reports Of Maxillary Second Molar, In Which An Extra Canal In The Mesiobuccal Root Was Located Using Visual, Tactile And Magnifying Devices Followed By Endodontic Treatment.*

Keywords: *Maxillary Second Molar, MB2 Root Canal, Magnifying Loupes, Ultrasonic Tip.*

I. INTRODUCTION

Awareness and understanding of the presence of unusual external and internal root canal morphology contributes to the successful outcome of the root canal treatment. Maxillary second molars show considerable anatomic variation and abnormalities with respect to the number of roots and root canals. Traditionally, the maxillary second molar has been described to have 3 roots with 3 or 4 root canals, with the fourth canal commonly being found in the mesiobuccal root (MB2).[1] Pecora[2] studied the internal anatomy of 370 maxillary molars by clearing the roof of the pulp chamber and located a second canal in mesiobuccal root of maxillary second molars, with frequency of 42%. Stropko[3] in 1999 examined 611 maxillary second molars over a period of eight years. He found an incidence of MB2 canals present in 310 (50.7%) cases. It occurred as a separate canal in 119 (45.6%) cases and joined the MB1 in 142 (54.4%) cases. Schwarze[4], confirmed in his study that there was a high number of second canals in the mesiobuccal roots (i.e.) 48% of maxillary second molars. Endodontically retreated teeth were found to contain more undetected MB2 canals than first-time treated teeth suggesting that failure to treat existing MB2 canals leads to a poorer prognosis.[5] The purpose of this article is to present case report of two cases of maxillary second molars, in which an extra canal in the mesiobuccal root were located using visual and magnifying devices, followed by endodontic treatment.

II. Case Report

A 45-years- old male patient without any history of systemic disease was referred to my clinic with chief complaint of severe pain in the left upper molar tooth since one week. Clinical examination revealed a large carious lesion on the distal surface of left maxillary second molar. Vitality testing gave a lingering response and radiographic investigation revealed pulpal exposure in relation to the left maxillary second molar (Figure 1a). Hence a diagnosis of irreversible pulpitis was made. Root canal therapy was initiated under rubber dam isolation. Once the pulp chamber was deroofed, a trapezoidal shaped access opening was obtained. On careful visualization of the floor of the pulp chamber with magnifying loupes (Carl Zeiss, 3.5X magnification), the dentinal map showed a long groove between the palatal and the mesiobuccal orifices. Further removal of groove beginning from the orifice of the mesiobuccal canal (MB1) and moving toward the orifice of the palatal canal with ultrasonic micro endodontic tip ET 18D tip,(Satelec A Division of ACTEON North America) clearly unveiled the orifice of the additional canal, which was diagnosed as MB2 canal. Working length was established with the help of an apex locator (Root ZX, J.Morita Inc.:USA). The canals were cleaned and shaped with hand files and Revo S (Micro Mega, France) NiTi rotary files in a crown down manner upto final canal size #0.04/25 in MB1 and MB2, #0.06/25 in distobuccal canal and #0.06/35 in palatal canal. Canals were irrigated with 5.25% sodium hypochlorite, 17% EDTA and 2% chlorhexidine. Canals were dried using paper points and a master cone radiograph was taken (Figure 1b) to check the apical fit in all the four canals. Finally canals were obturated with gutta-percha and AH plus sealer (Dentsply, Detrey, Konstanz, Germany) using warm vertical compaction (Figure 1c). The access preparation was sealed and the post endodontic restoration was planned.

Figure 1. (a) Preoperative radiograph of maxillary second molar (b) Master cone radiograph (c) Post obturation radiograph.

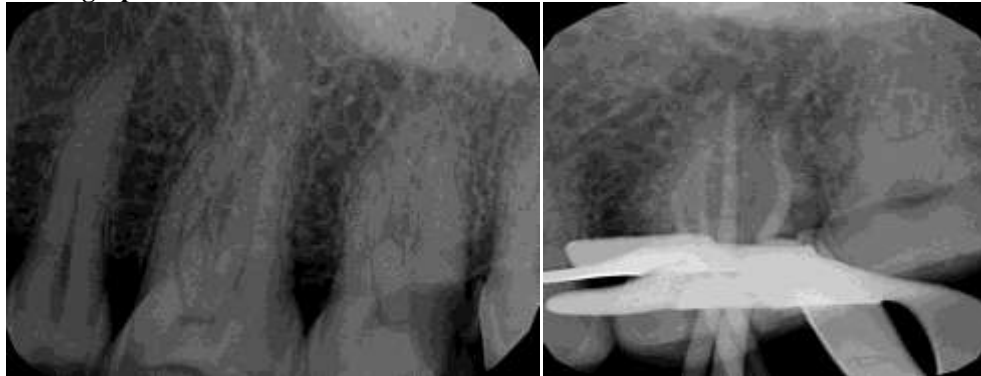

Figure 1a

Figure 1b

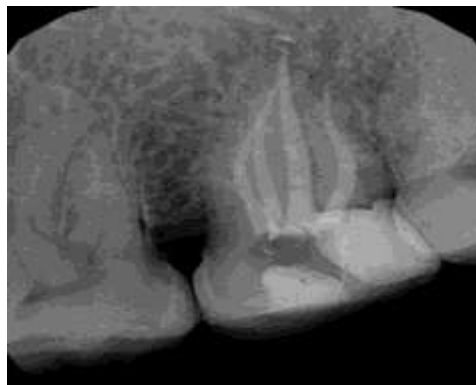


Figure 1c

III. CASE REPORT

Another 50-years-old male patient reported to my clinic without any history of systemic disease with chief complaint of severe pain in the left upper molar tooth since one week. The endodontic treatment had already been started, but the patient's symptoms did not relief. Vitality tests on tooth showed painful response to cold, heat and electrical pulp test. Radiographic examination revealed an incomplete access cavity with disto-occlusal cavity of left maxillary second molar which was restored with Glass ionomer cement (Figure 2a) The tooth was anesthetized, isolated and access cavity preparation was modified. On careful visualisation of the pulp chamber floor, it showed the presence of a long groove following the dentinal map. Further examination and exploration with DG 16 endodontic explorer disclosed an extra mesiobuccal canal around 2mm away, in the mesial and palatal direction. The canals were negotiated followed by biomechanical preparation and obturation (Figure 2b) same as in case1.

Figure 1. (a) Preoperative radiograph of maxillary second molar (b) Post obturation radiograph.

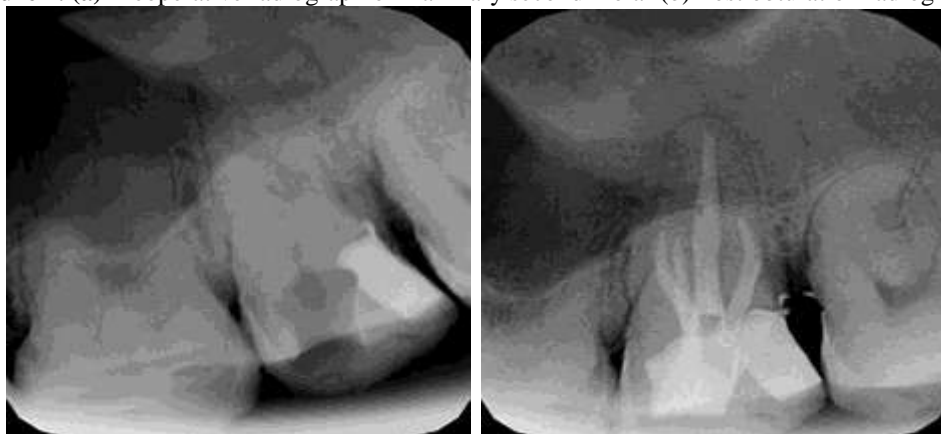


Figure 2a

Figure 2b

IV. Discussion

An inability to locate MB2 root canal in mesiobuccal root of maxillary molars may be a major cause of the failure of root canal treatment. The presence of patent furcal, lateral and accessory canals are the portals of entry and exit between the root canal space and periodontal ligament.[6] Maxillary 2nd molar usually contains 3 roots and three canals. Usual anatomical variation is presence of extra canal in mesiobuccal root. According to studies done by James Wolcott et al[5] 35% of maxillary 2nd molars had MB2 canal compared to 60% that of maxillary 1st molars. Moreover more incidence of finding this accessory canal in retreatment cases compared to initial treatment indicating main reason of endodontic treatment failure. According to Weine one of the causes of endodontic failures in maxillary second molars is the lack of locating the second mesiobuccal canal and the subsequent absence of its debridement and obturation.[7] The openings of MB2 canals are localized on an imaginary line between the MB1 and palatal orifice.[8] Beer and Baumann[9] suggested a geometric aid to locate an extra canal, which is adopted in this study to locate the extra canal. First a line 1 was drawn connecting the mesiobuccal and palatal canals, then a line 2 was drawn perpendicular to the line 1, at a point one third the intercanal distance from the palatal canal such that this line passes over the distobuccal canal. A fourth canal lies somewhere along line 3, which deviates approximately 10°.

The MB2 canal is challenging to negotiate. The canal has a marked incline immediately apical to its orifice in the coronal 1-3 mm. When an attempt is made to instrument MB2, the tip of the file tends to catch against the mesial wall of the canal, preventing apical progress. This is because MB2 canal is smaller and usually narrower than MB1. After locating the MB2 orifice, inclining the dental handpiece to the distal, as far as the access preparation permits us to enter the first few millimeters of this overlying “roof” of calcified tissue to be safely eliminated. After this “refinement” of the access preparation, a more desired straight line access can be achieved. Sometimes, the MB2 lies in the same orifice as MB1.[3]

Most of the MB2 canals, however, can be best identified by means of an operating microscope. It was found that 33.3% of cases with MB2 was identified using 3.5 X magnifying loupe, whereas 95.8% were identified using an operating microscope.[10]

Weine's[7] classification has been used to describe four common configurations of the maxillary MB root. Type I is a single canal from orifice to apex, Type II has two orifices that converge to one, Type III has separate and distinct canals from orifice to apex, and Type IV begins as one canal and diverges into two separate canals. In case 1 configuration of the MB root was of Type II and in case 2 it was type III.

V. CONCLUSION

It is imperative for a dentist to have adequate knowledge of endodontic anatomy and its possible variants to avoid retreatment. Thorough knowledge of these variations is essential prior to initiation of endodontic therapy. Hence the endodontist must have an open mind to accept the possibilities of extra canals for better management and a successful treatment outcome.

REFERENCES

- [1]. Prakash R, Bhargavi N, Jeyavel Rajan, Reuben Joseph, Velmurugan N, Kandaswamy D: MB2 in maxillary second molar. *Indian J Dent Res*, 18(1), 2007.
- [2]. Pecora JD, Woelfel JB, Sousa Neto MD, Issa EP. Morphologic study of the maxillary molars part II: Internal anatomy. *Braz Dent J* 3, 1992,53-7.
- [3]. Stropko JJ. Canal morphology of maxillary molars: Clinical observations of canal configurations. *J Endod* 25, 1999, 446-50.
- [4]. Schwarze T, Baethge C, Stecher T, Geurtsen W. Identification of second canals in the mesiobuccal root of maxillary first and second molars using magnifying loupes or an operating microscope. *Aust Endod J* 28,2002, 57-60.
- [5]. Wolcott J, Ishley D, Kennedy W, Johnson S, Minnich S, Meyers J. A 5 yr clinical investigation of second mesiobuccal canals in endodontically treated and retreated maxillary molars. *J Endod* 31, 2005, 262-4.
- [6]. Shetty Aditya, Hegde Mithra, Tahiliani Divya, Joshi Aum, Devadiga Darshana: Study on the efficacy of Iodine based contrast media for interpretation of root canal anatomy. *Int. Res. J. Pharm.* 4(3), 2013, 207-210.
- [7]. Weine FS. *Endodontic therapy*. 5th ed. 1996.
- [8]. Harry H. Peeters, Ketut Suardita and Darmawan Setijanto: Prevalence of a second canal in the mesiobuccal root of permanent maxillary first molars from an Indonesian population. *Journal of Oral Science*, Vol. 53, No. 4, 2011,489- 494,
- [9]. Rudolf B, Michael AB. *Color atlas of dental medicine*. Endodontology 2000. p. 51-2.
- [10]. Baratto-Filho F, Fariniuk LF, Ferreira EL, Pecora JD, Cruz-Filho M, Sousa-Neto MD. Clinical and macroscopic study of maxillary molars with two palatal roots. *Int Endod J* 35, 2002, 796-801.