



Research Paper

Analysis of Caries Lesions of two Groups of Children at 5 Years Through a Laser Fluorescence – Clinical Study

*Dr. Dobrinka Damyanova Phd¹, Assoc. Prof. Dr. Katerina Ivanova C.M.Sc.²

¹Assistant Professor, Medical University-Varna,Bulgaria, Faculty Of Dental Medicine, Department Of Pediatric Dental Medicine

²Associate Professor, Medical University-Varna,Bulgaria, Faculty Of Dental Medicine, Department Of Pediatric Dental Medicine

Corresponding author: *Dr. Dobrinka Damyanova Phd

Received 14 August, 2017; Accepted 19 August, 2017 © The author(s) 2017. Published with open access at www.questjournals.org

ABSTRACT

Background: There are only few in vivo clinical studies evaluating the laser fluorescence for monitoring changes in incipient caries lesions under preventive procedures.

Objective: Our study aims to evaluate the effect of mineralizing fluorine varnish on the progression of initial caries of enamel in temporary dentition by laser fluorescence.

Material and Methods: Object of observation. 1 group - 100 children aged 3, 4, 5 and 6 years treated with Clinpro™ White Varnish with TCP (Tri-Calcium phosphate) (3M) – CV. Two groups - 100 children aged 3, 4, 5 and 6 years without treatment with varnish CV. Location of the study - University Medical Dental Center Varna, Clinical Halls for Children's Dentistry, Faculty of Dental Medicine – Varna. Units of observation: Temporary teeth, Caries lesions at level d1 and d2. After processing the results and determination of the highlights was conducted by actual survey data processing package for mathematical and statistical analysis SPSS v 20.0.

Results: The comparative analysis of the results showed a significant difference in the five-year-old children in the control group (9,17) and those in the treatment group before treatment (6,42), with the latter being significantly lower ($t = 3.27, p < 0.01$). Results in temporary canines showed significant differences between the control group and the treated group after treatment ($t = 5.45, p < 0.001$) as well as the results before and after treatment with CV varnish ($t = 5.04, p < 0.001$). The trend was also observed in the results of the temporary first and second molar $t = 2.63, p < 0.05$ and $t = 4.76, p < 0.001$ for the control group and test group after treatment and $t = 4.04, p < 0.001$ and $t = 2.80, p < 0.05$ for values before and after treatment with Clinpro White Varnish with TCP.

Conclusion: 1. After the first week, DIAGNOdent pen scores improved from less than three steps for d1b and d2 lesions and improved by two steps for d1a lesions. 2. Increased therapeutic efficacy of dental agents for non-invasive treatment is achieved by enhancing them with fluorides.

Keywords: caries, lesions d1, d2, temporary teeth, DIAGNOdent Pen

I. INTRODUCTION

Only a few different methods are monitoring incipient carious lesions in smooth surfaces under fluoride varnish therapy [1]. The use of the 655-nm laser diode fluorescence is regarded as a promising option for caries diagnosis despite the risk of false positives for sealed surfaces and stained fissures [2]. The sensitivity and specificity of this device have been investigated in vitro in occlusal surfaces [5] and smooth surfaces [6,7]. There are only few in vivo clinical studies evaluating the laser fluorescence for monitoring changes in incipient caries lesions under preventive procedures [3,4]. Half-yearly applications have been proven to be efficient in preventing dental caries [8,10]. The current caries pattern of slow progression raises the chances to reverse a demineralization process of an incipient carious lesion [9,11,12].

Objective: Our study aims to evaluate the effect of mineralizing fluorine varnish on the progression of initial caries of enamel in temporary dentition by laser fluorescence.

II. MATERIAL AND METHODS

Two hundred children from 3 to 6 years of age attending clinical practice in Varna were included in two groups using Clinpro White Varnish (CV), mineralization fluoride varnish and a control group.

The examinations at the beginning and every three months up to the twelfth month inclusive were conducted by the pediatric dentist specialist. Results were scored on teeth and surfaces. Before we performed the clinical application of fluoride varnish, we applied diagnostics by laser fluorescence, with the measurements performed with DIAGNOdent Pen.

Diagnostic scale

d1a - white enamel lesion, visible with drying, d1b - white enamel lesion, visible without drying, d2 - white small enamel, cavity lesion, d3 - dentin caries, d4 - dentine caries with pulp involvement, A - active (d1a, d1b, d2), NA - inactive (d1a, d1b, d2)

Reversible caries lesions - (d1a, d1b, d2)

Irreversible caries lesions - d3 and d4

Differential diagnosis with Non-cariou lesions – dental fluorosis, hypo-mineralized spots, amelogenesis and enamel erosions.

Object of observation: 1 group - 100 children aged 3, 4, 5 and 6 years treated with Clinpro™ White Varnish with TCP (Tri-Calcium phosphate) (3M) – CV

2 group - 100 children aged 3, 4, 5 and 6 years without treatment with varnish CV

Units of observation: Temporary teeth, Caries lesions at level d1 and d2

Location of the study: University Medical Dental Center-Varna, Bulgaria;

• Clinical Halls for Children's Dentistry, Faculty of Dental Medicine – Varna. The study has been authorized by the Ethics Committee of the Scientific Research at the Medical University of Varna and informed consent of each parent, respectively, for each child-patient was made.

All patients examined and treated from the two study groups were given a comparative analysis of the results of the study using appropriate statistical methods. After processing the results and determination of the highlights was conducted by actual survey data processing package for mathematical and statistical analysis SPSS v 20.0.

III. RESULTS

The comparative analysis of the results showed a significant difference in the five-year-old children in the control group (9,17) and those in the treatment group before treatment (6,42), with the latter being significantly lower ($t = 3.27, p < 0.01$) Fig. 1. An even greater difference is seen between the control group and the children after treatment ($t = 8.69, p < 0.001$), which is approximately 3 times in favor of the first. In the treatment group, the difference before and after treatment is about 2 times lower for children after treatment, indicating good results with Clinpro White Varnish with TCP ($t = 8.69, p < 0.001$) Fig. 1.

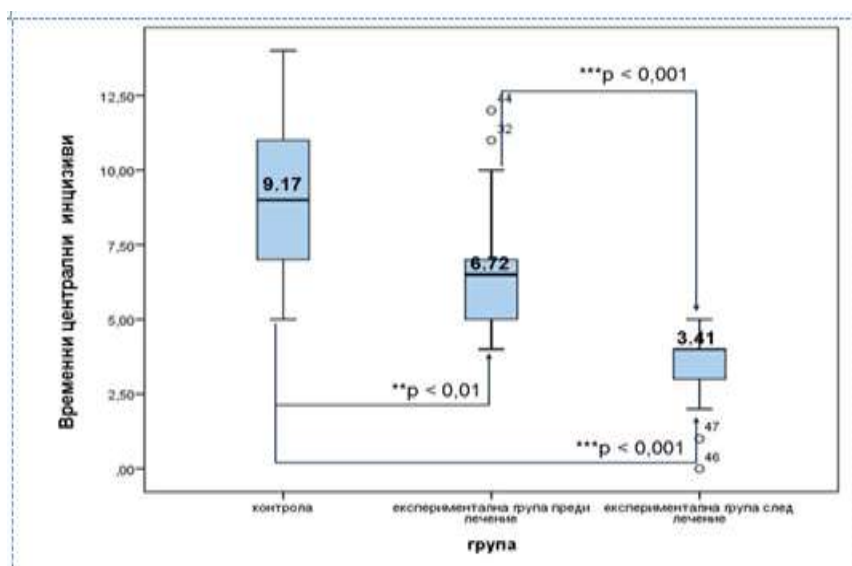


Fig.1. Boxplot Graphs Of A Comparative Analysis Of The Results Between The Experimental And Control Groups For The Temporary First Incisions Of 5 Year Old Children

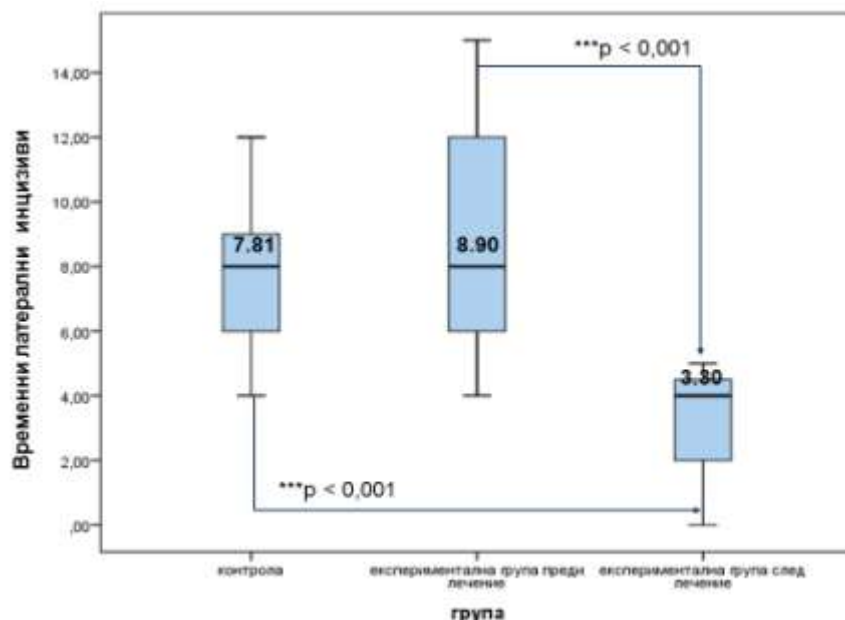


Fig.2. Boxplot Graphs Of A Comparative Analysis Of The Results Between Experimental And Control Groups For Temporary Lateral Incisors Of 5 Year Old Children

In temporary lateral incisors, a significant difference was observed only with respect to the values in the control group and those in treated after treatment with Clinpro White Varnish with TCP ($t = 7.47$, $p < 0.001$). A significant improvement was seen in the treatment with CV varnish ($t = 6.90$, $p < 0.001$) (Figure 2). Results in temporary canines showed significant differences between the control group and the treated group after treatment ($t = 5.45$, $p < 0.001$) as well as the results before and after treatment with CV varnish ($t = 5.04$, $p < 0.001$) (Figure 3).

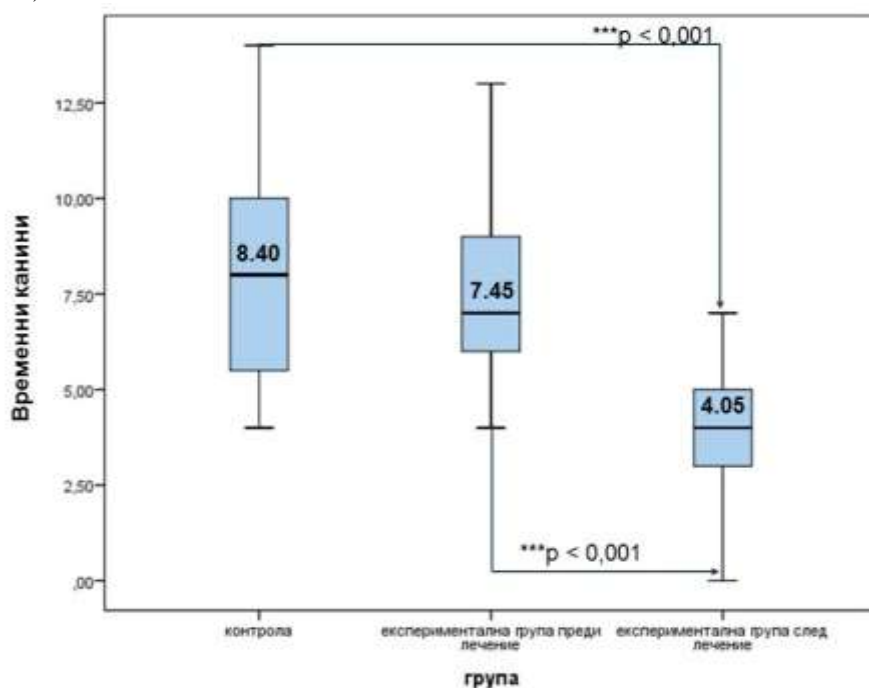


Fig.3. Boxplot graphs of a comparative analysis of the results between experimental and control groups for temporary canines of 5 year old children

The trend was also observed in the results of the temporary first and second molar $t=2.63$, $p < 0.05$ and $t = 4.76$, $p < 0.001$ for the control group and test group after treatment and $t = 4.04$, $p < 0.001$ and $t = 2.80$, $p < 0.05$ for values before and after treatment with Clinpro White Varnish with TCP /CV/ (Figures 4 and 5).

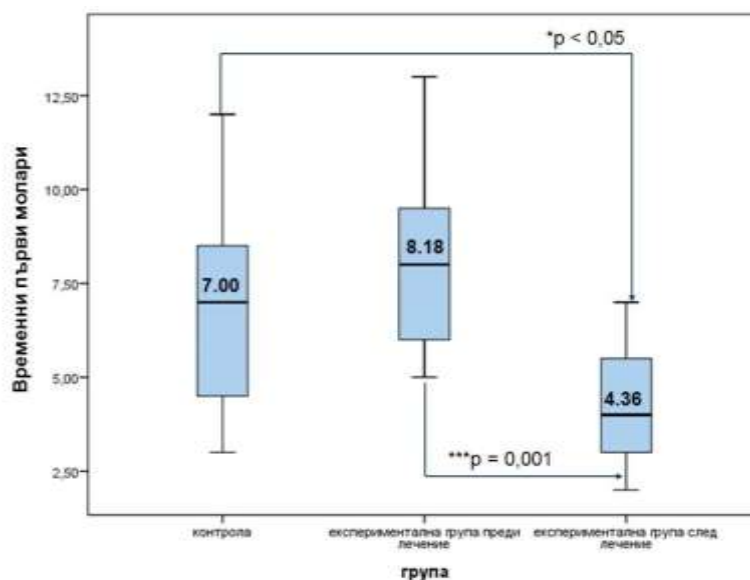


Fig.4. Boxplot graphs of a comparative analysis of the results between the experimental and control groups for the temporary first molar of 5 year old children

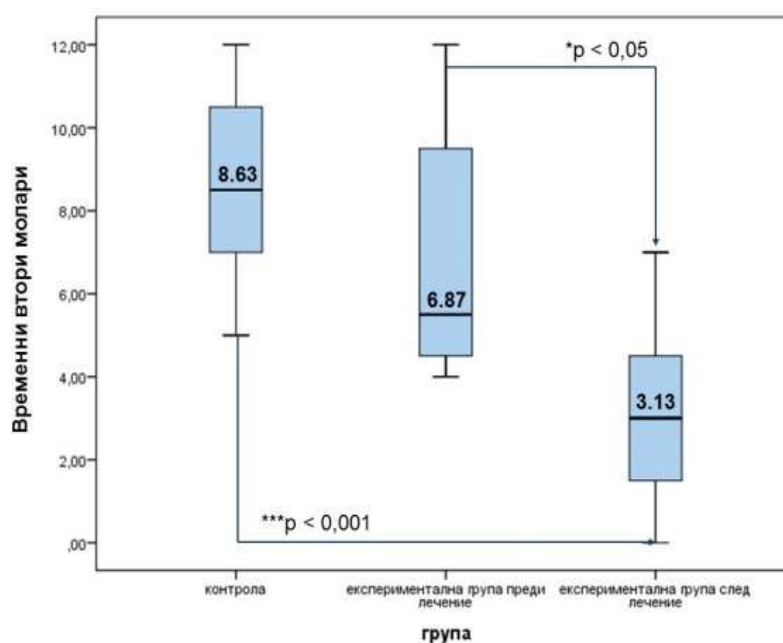


Fig. 5. Boxplot Graphs Of A Comparative Analysis Of The Results Between Experimental And Control Groups For Temporary Second Molars Of 5-Year-Olds

IV. CONCLUSIONS

1. After the first week, DIAGNOdent pen scores improved from less than three steps for d1b and d2 lesions and improved by two steps for d1a lesions.
2. Increased therapeutic efficacy of dental agents for non-invasive treatment is achieved by enhancing them with fluorides.
3. According to the clinical study, it can be concluded that changes in the degree of remineralization of the temporary teeth can be obtained with DIAGNOdent Pen.

REFERENCES

- [1]. Ferreira JMS, Milton FAS, Oliveira AFB, Sampalo FC. Evaluation of different methods for monitoring incipient carious lesions in smooth surfaces under fluoride varnish therapy. Int.Jour. of Paed.Dent. 2008;18:300-305.
- [2]. Shi X, Traneus S, Angmar-Manson B. Validation of DIAGNOdent for quantification of smooth-surfaces caries: an in vitro study. Acta Odontol Scand. 2001; 59:74-78.

- [3]. Anttonen V, Seppa L, Hausen H. A follow-up study of the use of DIAGNOdent for monitoring fissure caries in children. *Community Dent Oral Epidemiol.* 2004; 32:312-318.
- [4]. Aljehani A, Yousif MA, Angmar-Mansson B, Shi X-Q. Longitudinal quantification of incipient carious lesions in orthodontic patients using a fluorescence method. *Eur J Oral Sci.* 2006; 114:430-434.
- [5]. Lussi A, Hellwig E. Performance of a new laser fluorescence device for the detection of occlusal caries in vitro. *J Dent.* 2006;34:467-471.
- [6]. Aljehani A, Yang L, Shi XQ. In vitro quantification of smooth surface caries with DIAGNOdent and the DIAGNOdent pen. *Acta Odontol Scan.* 2007;65:60-63.
- [7]. Mendes FM, Siqueira WL, Mazitelli JF, Pinheiro SL, Bengtson AL. Performance of DIAGNOdent for detection and quantification of smooth-surface caries in primary teeth. *J Dent.* 2005;33:79-84.
- [8]. Bruyn H, Arends J. Fluoride varnishes – a review. *J Biol Buccale.* 1987;15:71-82.
- [9]. Featherstone JD. Prevention and reversal of dental caries: role of low level fluoride. *Community Dent Oral Epidemiol.* 1999;27(1):31-40.
- [10]. American Academy of Pediatric Dentistry. Guideline on Fluoride Therapy. Chicago IL: American Academy of Pediatric Dentistry; 2013. Available at: www.aapd.org/media/Policies_Guidelines/G_fluoridetherapy.pdf. Accessed January 28, 2014.
- [11]. Chou R, Cantor A, Zakher B, Mitchell J, Pappas M. Prevention of Dental Caries in Children Younger Than Age 5 Review to Update the U.S. Preventive Services Task Force Recommendation. Evidence Synthesis No.104. Rockville, MD: Agency for Healthcare Research and Quality; 2014. AHRQ Publication No. 13-05191-EF-1.
- [12]. Duangthip Duangporn. A randomized clinical trial on arresting dentin caries in preschool children by topical fluorides. Dissertation. 2015. Hong Kong.

*Dr. Dobrinka Damyanova Phd¹. “Analysis of Caries Lesions of two Groups of Children at 5 Years Through a Laser Fluorescence – Clinical Study.” *Quest Journals Journal of Medical and Dental Science Research* , vol. 04, no. 07, 2017, pp. 05–09.