



The Clinical Study of Surgical Management of Tibial Plateau Fractures.

¹Md. Abdullah Al Mamun, ²Mohammad Abdul Mazid, ³Md. Al Hasan Ibneh Fahad, ⁴Pengcheng Wang. Md,Phd.

¹Department of orthopedic surgery & trauma, The third hospital of hebei Medical University, China .

²Department of Hepatobiliary & Pancreatic Surgery, The First Affiliated Hospital of Dalian Medical University, China.

³The third hospital of hebei Medical University, China.

⁴Professor and HOD, Department of orthopedic surgery & trauma, The third hospital of hebei Medical University, China .

*Corresponding Author: Pengcheng Wang. Md,Phd. Department of orthopedic surgery & trauma, The third hospital of hebei Medical University, Hebei. 361 Zhongshan E Rd, Changan Qu, Shijiazhuang Shi, Hebei Sheng, China, 050017. Email: pengchengwang999@163.com Phone: 008618533112979

ABSTRACT

Background: advance in mechanization and acceleration of movement have been joined by the increase in number and severity of fractures and those of tibial plateau are no special case Being one of the significant weight-bearing joints of the body, fractures around it are of principal significance. The main investigation was expected to recognize the part of the surgical treatment of tibial plateau fractures, its useful result, and complications.

Methods: Sixty-four patients with tibial plateau fractures treated by different modalities were contemplated from Jan 2015 to Dec 2017 at The third hospital of Hebei medical university taken after at least time of a half year.

Results: The chose patients assessed completely: clinically and radiologically, were taken for surgery, after the applicable lab investigations. The indications fractures were treated with according to the SCHATZKER'S composes as needs be with CRIF, with percutaneous cannulated cancellous screws, ORIF with buttress plate with or without bone grafting, external fixator. The early extent of development started not long after the surgery. No weight bearing up to 6-8 weeks. The full weight bearing conceded until 12 weeks or finish fractures union. Immobilization in insecurity set fractures proceeded for 3-6 weeks by the POP cast. The knee scope of movement was good to great, gait and weight bearing after the total union was attractive. out of total patients, we found 5 complications is 10 patients. Knee stiffness in 3 cases, Malunion in 2 cases, Infection and wound dehiscences in 3 cases, External lag in 1 cases, depression in 1 cases.

Conclusion: Surgical management of tibial plateau fractures will give great anatomical reduction and inflexible fixation to reestablish articular congruity, facilitate early movement and reducing post-traumatic OA and therefore to accomplish optimal knee function.

KEYWORDS: Tibial plateau, , Bone graft, surgical approach, Buttress plate, Fracture.

Received 12 May, 2018; Accepted 28 May 2018 © The Author (S) 2018. Published With Open Access At www.Questjournals.Org

I INTRODUCTION

Surgical and Applied Anatomy:

Fracture patterns in the proximal tibia are dictated by the forces applied combined with the osseous anatomy of the proximal tibia[Fig.1] incidentally, muscle powers or ligament attachments have an influence on

the fracture pattern. The tibia continuously flares from the moderately narrow diaphysis to the proximal tibia. In the proximal quarter, the anterior proximal tibia extends to wind up plainly the tibial tubercle for attachment of the patellar tendon. The proximal lateral tibia unexpectedly flares from the smooth anterolateral surface to form the lateral tibial condyle, which fills in as the root of the anterior compartment muscles and all the more proximally has Gerdy tubercle for the insertion of the iliotibial band. Posteriorly on the lateral side, the fibular head fills in as a palpable landmark and as the site of attachment of the fibular collateral ligament and the biceps tendon. It characterizes the position of the peroneal nerve, which lays on the posterior neck of the fibula. The proximal fibula buttresses the lateral plateau, and associated fractures of the proximal fibula result in a more noteworthy level of valgus instability and show a more extreme lateral fracture. The proximal tibiofibular joint is a synovial joint that may communicate with the knee joint. On the medial side, the flare to the medial tibial condyle is more steady, outright medial, and more sudden and flared posteromedially. Angular forces to the knee and compression and axial loading lead to disappointment through these flared condyles on the lateral or medial sides or with straight axial loading on both sides. The medial plateau is more impervious to disappointment than the lateral plateau. The articular surface of the lateral tibial plateau is flat or somewhat raised in relation to the medial tibial plateau that is concave which give more prominent congruity with the medial femoral condyle than on the lateral side. This anatomy is imperative when utilizing radiographs and fluoroscopy during surgical treatment since it permits isolate appraisal of the two plateaus on the lateral radiographs. The lateral plateau is also higher than the medial plateau accounting for the few degrees of the virus of the tibial plateau in connection to the pole. The proximal articular surface slopes in connection to the pole from the front, which is high, to the back, which is low. Hashemi et al. in an investigation on MRIs found that the average values were around 5 degrees for sagittal slope and 3 degrees for coronal slope. However, these angular relationships of the tibial plateau had significant variation between individuals with the scope of varus coronal slope between -1 and 6 degrees and the sagittal slope was from 0 to 14 degrees on the lateral side and -3 to 10 degrees on the medial side[1]. These varieties of individuals are conceivably imperative for tibial plateau fracture surgery since little degrees of malalignment may be viewed as essential. Evaluating arrangement in contrast with the nonfractured side is sensible. Both the medial and lateral articular surfaces are secured by hyaline cartilage and are partly secured by the fibrocartilaginous menisci, both of which are attached to their respective plateaus by the menisci tibial ligaments (coronary ligaments). There is more prominent meniscal coverage of the lateral plateau than the medial plateau. The intercondylar eminence and medial and lateral tibial spines, which are nonarticular, isolate the two plateaus. They likewise fill in as an attachment for the anterior cruciate ligament (ACL) anterior to the medial spine and the posterior cruciate ligament (PCL) that reaches out down to the posterior surface of the proximal tibia. The proximal anterior 66% of the tibia is generally subcutaneous. The posterior tibia is far below the structures crossing the popliteal fossa making direct surgical exposures around there troublesome. The anterior tibia is more open however especially the medial surface is at risk for surgical incisions in high-vitality fractures. The pes tendons, gracilis, sartorius, and semitendinosus insert on the anteromedial portion of the proximal tibia distal to the insertion of the patellar tendon on the tibial tubercle. Prior to the insertion, these tendons give off developments to the fascia of the lower leg. The posterior part of the pes expansions must be chiseled to retract the pes tendons anteriorly by the posteromedial approach. The anterior compartment muscles, tibialis anterior, and extensor digitorum longus arise from the inferior surface of the lateral condyle of the tibia. The origin must be elevated to place an anterolateral tibial plate. The medial head of the gastrocnemius arises from the posterior femur just above the posterior medial femoral condyle. It can be retracted laterally or if necessary, the origin can be incised to enhance exposure of the posteromedial and posterior tibial plateau. The common peroneal nerve runs under the cover of the biceps femoris and is on the back of the neck of the fibula. It is not at risk during most surgery for tibial plateau fractures as long as the surgeon remains aware of the position of the fibula. Rarely, a posterolateral approach may be chosen in which case the peroneal nerve must be identified and mobilized. It is at risk from direct lateral impact mechanisms and with high-energy fractures of the tibial plateau, particularly medial plateau fractures which produce varus alignment. The tibial nerve in the popliteal fossa is rarely injured and rarely part of surgical approaches for tibial plateau fractures. The popliteal artery, which is at risk in knee dislocations, is rarely injured with tibial plateau fractures.

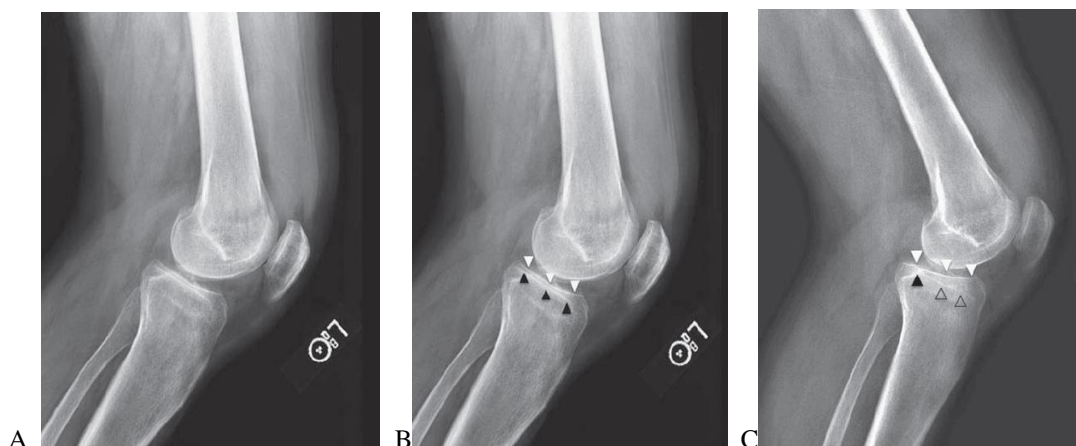


Figure 1. A: Represents a lateral knee x-ray. **B:** Denotes the subchondral arcs of both the medial tibial plateau (white triangles) and lateral tibial plateau (black triangles). Of particular interest is the relative concavity of the medial tibial plateau and slight convexity of the lateral plateau. **C:** It is a lateral of the same knee following an isolated local compression injury of the anterolateral tibia plateau; note the loss of congruity of the lateral subchondral density as denoted by the unfilled triangles. The concave medial plateau (white triangles) is still intact.

However, the trifurcation of the popliteal artery occurs in an area where plateau displacement is likely with certain fracture patterns and the anterior tibial artery is bound at the interosseous membrane and is at particular risk in shaft-dissociated patterns. Occult injury to the anterior tibial artery may account in part for the compartment syndromes frequently associated with these fracture patterns.

Tibial plateau and intra-articular fractures:

Tibial plateau fractures are one of the commonest intra-articular fractures because of circuitous coronal or direct pivotal compressive powers. Fractures of tibial plateau constitute 8% in the elderly and 1% of all fractures [1]. These fractures incorporate numerous and shifted fracture arrangements that include the medial condyle (10-23%), lateral condyle (55-70%) or both (11-30%) with varying degrees of articular depression and removal. If there should be an occurrence of ill-advised reclamation of the plateau surface and the pivot of the leg, these fractures could prompt advancement of untimely osteoarthritis, injury in ligaments, too long lasting pain and incapacity [2]. Tibial plateau fractures might be joined by meniscal and ligamentous injuries to the knee excessively [3]. For an appraisal of the initial injury, arranging management and expectation of visualization, orthopedic specialists generally utilize the Schatzker classification system, which separates tibial plateau fractures into six sorts. Each expanding numeric classification determines expanded level of vitality granted to a bone in this manner expanding seriousness of fracture [3]. Initial four are unicondylar and sort V and VI are bicondylar. Each fractures example in Schatzker classification guides orthopedic specialists to embrace suitable treatment modality [4]. The main point was to think about the surgical management of intra-articular fractures of proximal tibia to get a steady, pain-free, portable joint, to keep the development of osteoarthritis and to connect the radiological discoveries with the types of fractures and practical final result.

II METHODOLOGY

A retrospective study of 64 consecutive patients from the third hospital of Hebei medical university during the period of January 2015 to December 2017. In our total cases the oldest patients age 60 years old and youngest 24 years old and average age of patients 40 years old.

The Inclusion Criteria:

- a) Age: includes patients of age 18-60 years of both sexes
- b) The fractures with the classification of Radiological diagnosis based on Schatzker's classification.
- c) unstable tibial plateau fractures.
- d) comminuted and segmental fractures.

The Exclusion Criteria:

- a) Age: excludes patients with age less than 18 years.
- b) Patients who are medically unfit for the surgery.
- c) Compound tibial plateau fracture, pathological fractures,

- d) tibial plateau open fractures
- e) All patients are chosen based on history, clinical examination
- f) all surgical cases treated will be open reduction and internal fixation.

The following table shows:[Table 1]: various surgical treatment methods in 64 patients.

The patients method & treatment	The number of total patients (n=64)	The number of total patients Percentage(%)
Percutaneous cancellous screw fixation	16	25(%)
Cancellous screw and bone grafting	4	6.2(%)
ORIF with butteres plate and screws	30	46.8(%)
ORIF with butteres plate and bone graft	12	18.8(%)
ORIF with butteres plate and external fixator	2	3.2(%)

Surgically treatment methods for 64 patients\ORIF: open reduction and internal fixation

Methods of Treatment

At whatever point internal fixation was accomplished, the patient was prepared 48 hours after removal of the channels, for 2-5 days the scope of the movement permitted was 0-20°, from the 5th-day scope of movement was bit by bit permitted to be increased to at least 90°. After suture expulsion, the full scope of development was permitted. At whatever point there was a question about the rigidity of fixation, external splinting in the form of plaster of Paris piece was given for help. The scope of movement works out (CPM) were done every day under cautious supervision and splint reapplied. Every one of patients was educated and encouraged to do static quadriceps activities and dynamic activities with a quadriceps board however much as could be expected and for the duration of the day. fractional weight bearing was deferred until 6-8 weeks and full weight permitted following 12-16 weeks. Pre-operative care: Assent of the patients for anesthesia and surgery was obtain .nil by mouth(NBM)8 hours before surgery.Injection TT.5cc IM detail was injected.

Post-operative care: The patient's outstanding care after surgery, we received the patients and send to ICU for monitoring about patients blood body temperature and respiratory function monitored by hourly. after monitoring the normal function of respiratory then patients through the department and give the antibiotics were prescribed for 7-10 days.After 2-3 days monitoring, we did postoperative X-ray because check the position of patients foot.

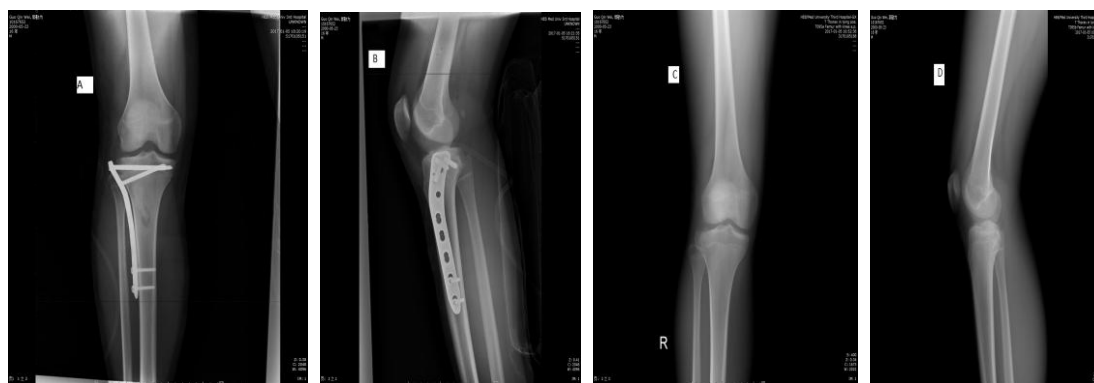

Figure 4: A 16-years man was surgically treated with lateral plateau of tibia plateau fracture Type 11 fracture with a split depression of the lateral tibial plateau. The lateral plateau was exposed beneath the meniscus and the depressed articular surface fragments were elevated 'en masse' by opening the peripheral fracture deJect. Autologous cancellous bone grafts were inserted into the remaining metaphyseal void ,followed by reduction of the split fragment and fixation with a buttress plate and lag screws, with anatomic reduction of the articular fragments and rigid fixation .(A)front view of postoperative X-ray.(B)side view of postoperative X-ray.(C) front view of preoperative x-ray.(D) side view of preoperative X-ray.

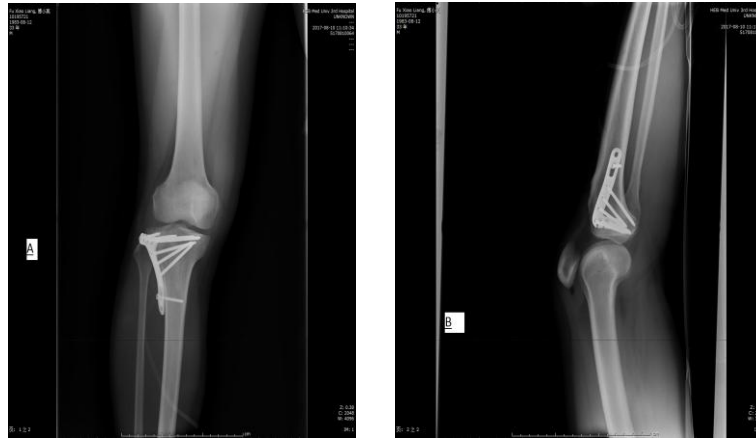


Figure 4: A 33-years man was surgically treated tibial plateau fracture.(A) Front position view of postoperative lateral plateau X-ray, isolated depression fracture (rare) ,Compression fracture of lateral plateau.(B)side position view of postoperative lateral plateau X-ray.

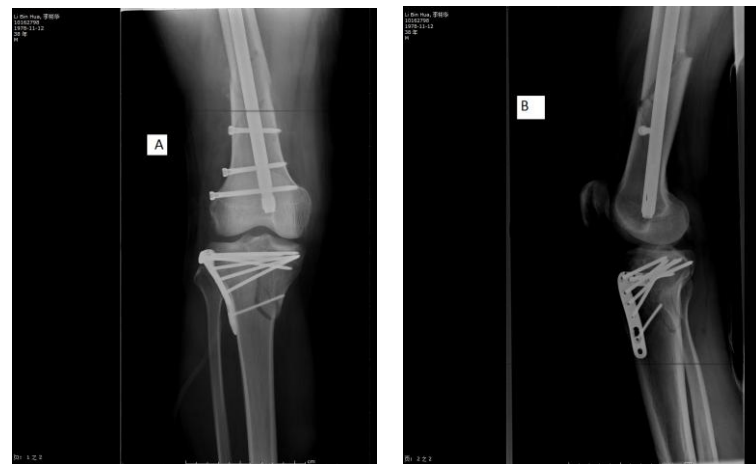


Figure 5: A 38 years man was surgically treated with medial plateau fracture .(A) front position view of postoperative medial plateau fracture X-ray. , split or split-depression fracture. (B)side view of postoperative X-ray

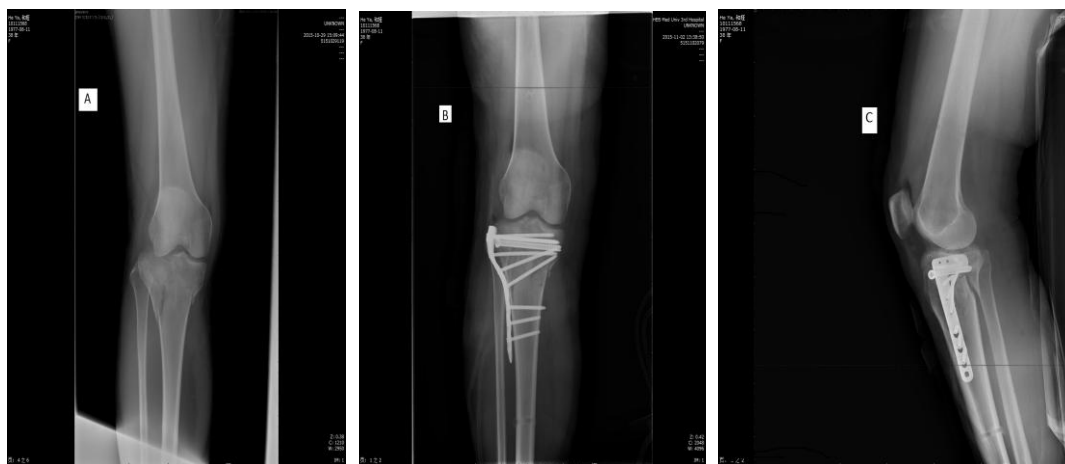

Figure 6: A 39-years old female was surgically treated with biocondylar fracture of tibial plateau .(A) Preoperative X-ray biocondylar fracture of tibial plateau.(B) front view of postoperative X-ray.Medial and lateral plateau fractures with or without compression (C)Side view of postoperative X-ray.

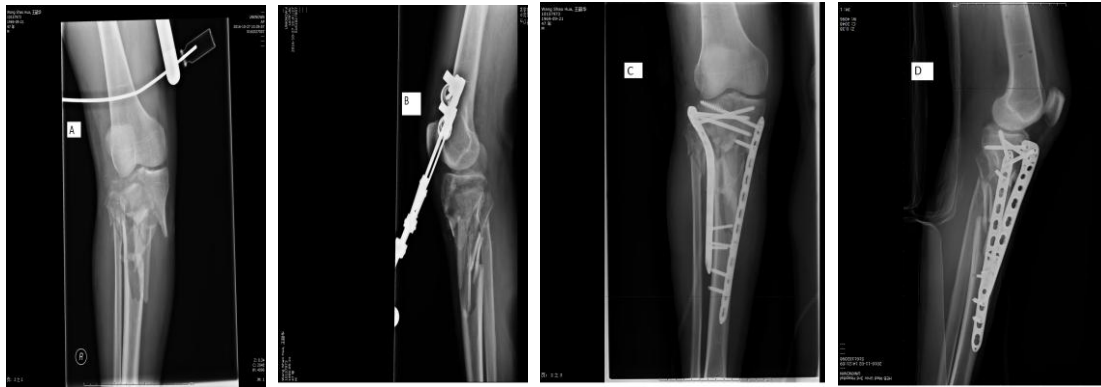

Figure 7: A 47 years old man was surgically treated with tibia plateau fracture with separation of metaphysis from diaphysis.(A)Front view of preoperative X-ray.(B)Side view of preoperative X-ray (C)front view of Postoperative X-ray.Complex bicondylar fracture with separation of condylar components from diaphysis .(D)side view of postoperative X-ray.

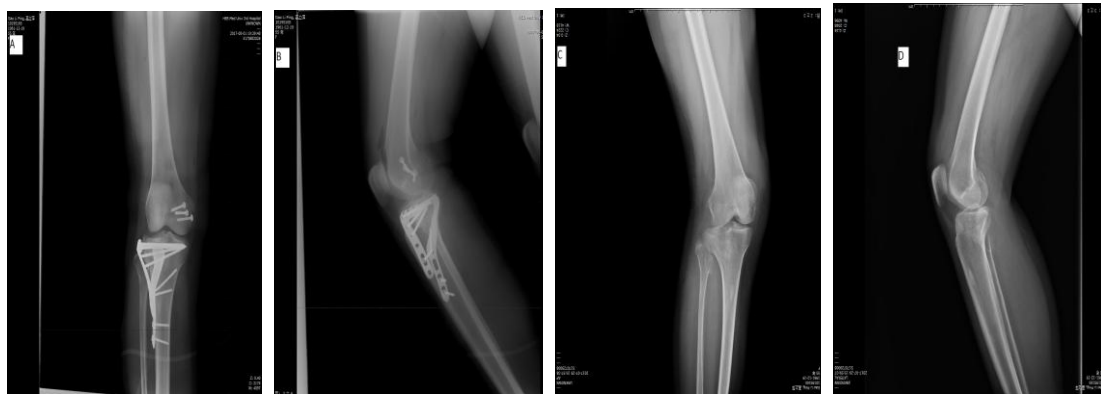

Figure 8: A 55-years old female was surgically treated with lateral plateau fracture of tibia plateau. split-depression fracture (most common).(A) front view of postoperative X-ray.(B)side view of postoperative X-ray.(C) Front view of preoperative X-ray.(D)side view of preoperative X-ray

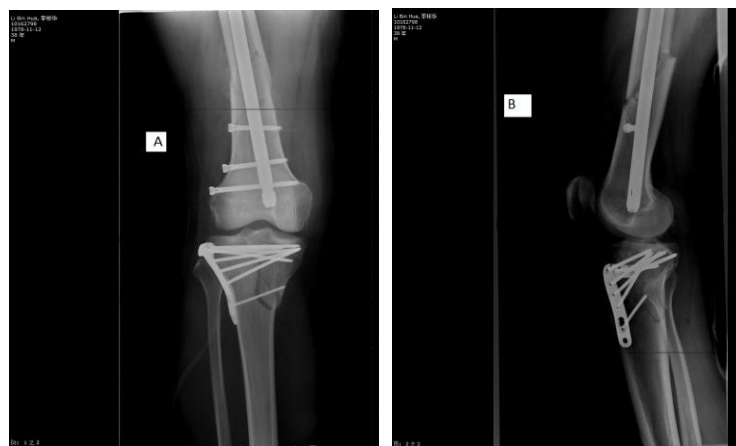

Figure 9: A 38-years man surgically treated was medial plateau fracture, split or split-depression fracture.(A) front side view of postoperative X-ray.(C)side view of postoperative X-ray.

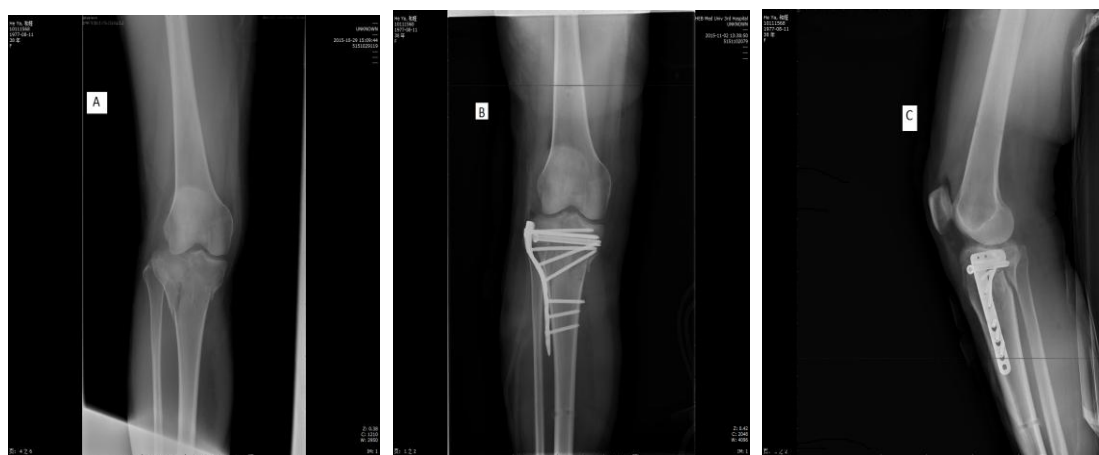

Figure 10: A 39-years old female was surgically treated with bicondylar fracture of tibia plateau. Medial and lateral plateau fractures with or without compression.(A) front view preoperative X-ray.(B)front view postoperative X-ray .(C)side view of postoperative X-ray.

III RESULTS

Perception and investigation of results were done in relation to age, type of fracture, a technique for treatment, duration of immobilization, complications and the comments of various age bunches in points of interest has appeared in[Table-2].

Patients age	The number of total patients (n=64)	The number of total patients Percentage(%)
21-30	6	9.4(%)
31-40	34	53.1(%)
41-50	16	25.0(%)
51-60	8	12.5(%)
Sex		
Male	58	90.6(%)
Female	6	9.4(%)

Shows patient age groups and sex Vs number of cases

None of the patients were immobilized when secure, inflexible fixation was finished. In case of uncertainty about the inflexibility of fixation, related ligament damage or osteoporosis, the immobilization was extended ideally in above knee cast up to 3 weeks. Two cases of contamination and another case of serious metaphyseal comminution must be immobilized for 6-8 weeks[Table-3]. The majority of the cases had a great range of painless knee motion (0-130°), with exception of the last group where one patient created knee stiffness [table-4].

The Immobilization Period	The number of total patients (n=64)
<10 days	48
Upto 3 weeks	10
Upto 6 weeks	6

Period of immobilization.

Complications	Total complications number of patients (n=10)
Knee stiffness	3
Malunion	2
Infection and wound dehiscences	3
External lag	1
Redepression	1

Shows numbers of patients with different complications.

All fractures jointed inside expected time. Not a solitary case of non-union was noted in given arrangement. The normal time for the union was 14 weeks (go 10-22 weeks). Out of 64 cases treated with surgical technique,

28 cases gave great outcome and 4 cases of poor outcome were seen, for the most part, because of the seriousness of the injury and infections [table-5]. Reflectively it was put that high-speed injuries (Type IV-VI) have poorer result than low-speed injuries (Type I-III) [5].

The clinical outcome of total patients	The number of total patients (n=64)	The number of total patients Percentage(%)
excellent	28	43.75(%)
Good	28	43.75(%)
Fair	4	6.25(%)
Poor	4	6.25(%)

The clinical outcome of total patients of surgery.

IV DISCUSSION

It's very difficult to be a great because of their intraarticular fractures, a major traumatic injury occurring because of RTA, tumble from stature, viciousness etc. it is at times connected with other bony or soft injuries. Any fracture around the joint (particularly weight-bearing knee joint in the lower limb) is of central significance as it brings in significant morbidity and unfavorably influences personal satisfaction. Consequently, In this way, the treatment of upper tibial fractures with intra-articular extension is a test for the orthopedic surgeons. In exhibit think about, the greater part of fractures occurred between the age of 20 and 60 years with the most extreme rate in the gainful age group of 31-40 years (53.1%). Honkonen SE [6] additionally demonstrated age occurrence 20-60 years with a normal rate of 39.8 years which associates with the present examination. Lee et al., [7] too demonstrated that the normal period of tibial plateau fractures in patients was 42 years. Albuquerque et al. watched that 71% of wounds happened in those age 30-60 years, with most extreme recurrence between 40-49 years[8]. High vitality wounds are more typical in adolescents and low vitality fractures in elderly patients [4]. The tibial plateau fractures are ordinarily found in the dynamic and beneficial age group particularly in male patients as they participate in more exercises and travels. In given examination males were more influenced than females which were likewise detailed by, Manidakis et al.,(58.4%) [9], Lee et al., (65.71%) [7], Mehin et al.,(56%) [10]. Albuquerque et al., (70.3%) [8] In given arrangement, Schatzkar Type I and Type II overwhelmed the aggregate fractures making 50% [Table-6]. Additionally Rademakers et al., detailed that 64% patients supported a fracture of the lateral condyle (Schatzker 1/2/3) [11]. Mehin and co-workers announced around 30% of the wounds were high-review Type-VI tibia plateau fractures, while 35% brought down review Type-III fractures [10]. In X-ray examination of 103 patients, Gardner et al., detailed that the most incessant fracture example was a lateral plateau split-depression (Schatzker II) [12]. Number and level of cases, with different Schatzkar kinds of fracture, announced in different examinations has been classified in [Table-6].

Types of fracture(Schatzkar classification)[3]	Schatzkar et al.[13]	Albuquerque et al.[8]	Manidakis et.al[9]	Present study percentage of total patients (n=64)/(%)
Lateral plateau fracture without depression(I)	4(6)	20(8.4)	31(24.8)	20(31.25%)
Lateral plateau fracture with depression (II)	18(25)	84.(35.1)	42(33.6)	12(18.75%)
Compression fracture of the lateral central plateau (III)	25(36)	21(8.8)	21(16.8)	4(6.25%)
Medial plateau fracture(IV)	7(10)	28(11.7)	9(7.2)	8(12.5%)
Bicondylar plateau fracture (V)	2(3)	38(15.9)	6(4.8)	12(18.75%)
Plateau fracture with diaphyseal discontinuity(VI)	14(20)	48(20.1)	16(12.8)	8(12.5%)
Total	70	239	125	64

Schatzkar type of fracture reported in various studies

In this arrangement, we examined 64 cases of basic tibial plateau fractures treated just by surgical strategies. diverse authors utilize distinctive criteria for the surgical management of these fractures. In exhibit contemplate, 3mm depression was considered as a sing for surgery. Schatzkar [13], revealed 70 cases of tibial plateau fracture of assorted types treated by traditionalist (56%) and surgical (44%) with normal follow up of 28 months satisfactory outcome were acquired in 58% of cases of preservationist group and 78% by open technique.

In the early 50% of the twentieth century, a creator announced two investigations having the attractive result of good to excellent short and long-term results with surgical technique of treatment [14,15]. Another distributed investigation of 159 cases of tibial plateau fracture of various types revealed better “good-excellent” results in surgery (84%) than traditionalist (62%) techniques [16]. Mehin and coworkers revealed that “of 286 patients with tibial plateau fractures, of whom 77% were treated with operatively” [10]. Additionally Pasa et al., excessively detailed that 30 % were treated with minimalistically and 70% by a surgical system [17].

We don't have defined the stringent criteria as to the specific procedure of fixation for a particular type of fracture. So each case was individualized and regarded appropriately as it needs. The majority of type I, some compose type II and an instance of type V was treated with percutaneous cancellous screw fixation. The split fracture, of >3mm uprooting, was 79 treated by ORIF. Bone grafting was incorporated ORIF with Buttress plate and screws type II, III, V, and VI wherever essential. Of 114 patients with proximal tibial fractures, Pasa et al., utilized fixation with a cancellous screw and washer in 25, and a buttress plate in 27 patients. They likewise detailed that better outcomes were accomplished in the treatment of Intra-articular fractures of the proximal tibia by negligibly intrusive fixation with cancellous screws [17].

The advantages of early knee movement include – decrease knee stiffness and enhanced cartilage mending (regeneration). Be that as it may, these advantages are to be warily adjusted by danger, including loss of fracture diminishment, failure of internal fixation and bargained ligament and soft tissue recuperating. Schatzker et al. expressed that the visualization is given by the level of displacement, kind of fracture, the technique of treatment and quality of postoperative care [18]. we accomplished 44% fantastic outcome 44% great outcome (general 88% acceptable outcome) with our standard surgical care utilizing different standard fixation 80 methods. Moreover, we had 6% reasonable and 6% poor outcome as far as a utilitarian result. These outcomes are practically identical and keeping pace with other reported standard investigations [Table-7].

Authors	Result
Joseph schatzkar[13]	86%
Honkonen SE[6]	86%
Radmarkers et al.[10]	94%
Manidakis [9]	69%
Urrueal AM [18]	76%
Present study percentage of total patients (n=64)/(%)	88%

Studies showing acceptable result of surgical treatment.

V CONCLUSION

- Tibial plateau fractures are expanding (particularly the high-speed injuries) with the expansion in card crashes.
- Surgical treatment when shown (especially discouraged and dislodged fractures) is worthwhile to get a stable knee.
- The surgical management of tibial plateau fractures is testing and gives amazing anatomical diminishment and inflexible obsession to reestablish articular congruity, encourage early knee movement by lessening post-traumatic osteoarthritis in this way accomplishing optimal knee function.

REFERENCES

- [1]. Jacofsky DJ, Haidukerwych GJ. Insall & Scott Surgery of the knee. Philadelphia: Churchill Livingstone; 2006. Tibia plateau fractures. In: Scott WN; pp. 1133–46.
- [2]. Wang SQ, Gao YS, Wang JQ, Zhang CQ, Mei J, Rao ZT. Surgical approach for high-energy posterior tibial plateau fractures. Indian J Orthop. 2011 Mar-Apr;45(2):125–31.
- [3]. Markhardt BK, Gross JM, Monu J. Schatzker Classification of Tibial Plateau Fractures: Use of CT and MR Imaging Improves Assessment. Radio Graphics. March 2009;29:585–97.
- [4]. Zeltser DW, Leopold SS. Classifications in brief: Schatzker classification of tibial plateau fractures. Clin Orthop Relat Res. 2013 Feb;471(2):371–74.
- [5]. Mills WJ, Nork SE. Open reduction and internal fixation of High energy tibial plateau fractures. Orthop Clin North Am. 2002;33:177–94.
- [6]. Honkonen SE. Indications for surgical treatment of tibial condyle fractures. Clin Orthop Relat Res. 1994 May;(302):199–205.
- [7]. Lee JA, Papadakis SA, Moon C, Zalavras CG. Tibial plateau fractures treated with the less invasive stabilisation system. Int Orthop. 2007 June;31(3):415–18.
- [8]. Albuquerque RP e, Hara R, Prado J, Schiavo L, Giordano V, Amaral NP do. Epidemiological study on tibial plateau fractures at a level I trauma center. Acta Ortopédica Brasileira. 2013;21(2):109–15.
- [9]. Manidakis N, Dosani A, Dimitriou R, Stengel D, Matthews S, Giannoudis P. Tibial plateau fractures: functional outcome and incidence of osteoarthritis in 125 cases. Int Orthop. 2010 April;34(4):565–70.
- [10]. Mehin R, O'Brien P, Broekhuysen H, Blachut P, Guy P. Endstage arthritis following tibia plateau fractures: average 10-year follow-up. Can J Surg. 2012 Apr;55(2):87–94.
- [11]. Rademakers MV, Kerkhoffs GM, Sierrevelt IN, Raaymakers EL, Marti RK. Operative treatment of 109 tibial plateau fractures: five-to 27-year follow-up results. J Orthop Trauma. 2007 Jan;21(1):5–10.

- [12]. Gardner MJ, Yacoubian S, Geller D, Suk M, Mintz D, Potter H, et al. The incidence of soft tissue injury in operative tibial plateau fractures: a magnetic resonance imaging analysis of 103 patients. *J Orthop Trauma*. 2005 Feb;19(2):79–84.
- [13]. Schatzker J, McBroom R, Bruce D. The tibial plateau fracture : the Toronto experience 1968-1975. *Clin Orthop*. 1979;138:94–104.
- [14]. Palmer I. Compression fracture of lateral tibial condyle and their treatment. *J Bone Joint Surg Am*. 1939 Jul 01;21(3):674–80.
- [15]. Palmer I. Fractures of the upper end of the tibia. *J Bone Joint Surg [Br]* 1951;33-B:160–6.
- [16]. Roberts JM. Fractures of the condyles of the tibia : an anatomical and clinical end-result study of one hundred cases. *J Bone Joint Surg [Am]* 1968;50-A:1505–21.
- [17]. Pasa L, Kelbl M, Suchomel R, Procházka V, Filipínský J. Treatment of intra-articular proximal tibial evaluation of two- to seven-year follow-up. *Acta Chir Orthop Traumatol Cech*. 2007 Oct;74(5):336–41.
- [18]. Urruela AM, Davidovitch R, Karia R, Khurana S, Egol KA. Results following operative treatment of tibial plateau fractures. *J Knee Surg*. 2013 Jun;26(3):161–5

Pengcheng Wang. Md, Phd." The Clinical Study of Surgical Management of Tibial Plateau Fractures."
Quest Journals Journal of Medical and Dental Science Research 5.3 (2018): 42-50.