



Research Paper

## Primary axillary cutaneous neuroendocrine carcinoma of the skin : about a case and literature review

A achbouk<sup>1</sup>, azekhmam<sup>2</sup>, oukabli<sup>2</sup>, y ribag<sup>1</sup>, k elkhatib<sup>1</sup>

<sup>1</sup> Plastic and reconstructive surgery department

<sup>2</sup> Pathological Anatomy Laboratory

Mohamed V Military Hospital, RABAT

Corresponding author: A achbouk

**SUMMARY : Introduction:** Cutaneous neuroendocrine carcinoma or Merkel's tumor is an aggressive skin tumor that usually progresses rapidly. We report the case of a rare axillary localization.

**Observation:** A 45-year-old woman presented with a tumor closet of left axillary localization, without palpable axillary adenopathy. Histological and immunohistochemical examinations led to the diagnosis of neuroendocrine carcinoma.

The primary cutaneous origin was retained due to the negativity of the thoracic and abdominal-pelvic imaging. The evolution was favourable after radical surgery.

**Discussion:** To our knowledge, this axillary localization has never been reported. The absence of lymph node metastasis despite the large tumor volume suggests a mildly lymphatic form of cutaneous neuroendocrine carcinoma.

**Key words:** Cutaneous neuroendocrine carcinoma, axillary localization, immunohistochemistry.

Received 25 Feb. , 2020; Accepted 05 Mar., 2020 © the Author(S) 2020.

Published With Open Access At [www.Questjournals.Org](http://www.Questjournals.Org)

### I. INTRODUCTION :

The cutaneous neuroendocrine carcinoma (CNEC) or Merkel's tumor is a rare tumor, developed from the sweat glands. It is usually located at the cephalic end, especially in the periorbital region [1]. It was described in 1972 by Toker as trabecular carcinoma of the skin. It is a rare tumour in the elderly, and most often the lesion is asymptomatic and presents as an erythematous, sometimes purplish plaque or nodule [2]. It is a low-grade malignant tumour with a low metastatic potential [3], and is slow-growing, but with local recurrences in almost 50% of cases [4].

Diagnosis has been facilitated by the contribution of electron microscopy and especially immunohistochemistry and its treatment is above all surgical [5].

We report through a clinical observation of a patient with a primary cutaneous neuroendocrine carcinoma with axillary localization the anatomical-clinical and immunohistochemical aspects of this pathological entity.

#### Patient and observation:

This is a 45 year old Patient, with no notable history, who consulted in our training in November 2019, for a left axillary tumor that had appeared 8 months previously, and which had progressively increased in volume( figure 1). On examination, the mass consists of a nodular cupboard, of hard consistency, purplish coloration, about 6 /4 cm with peripheral inflammation, mobile in relation to the underlying planes (Figure 1). The lymph node areas are free. An anatomopathological analysis of a biopsy specimen with a margin of 1 cm showed a carcinomatous tumour proliferation of generally solid organoid architecture, in the form of clumps and islets in the dermis. This tumour proliferation has an abundant mucinous component in the form of mucin puddles (alcian blue) or floating trabeculae and strands of tumour cells. The latter are endowed with an abundant cytoplasm that is clarified, with highly anisokaryotic nucleoli showing numerous patterns of mitosis. The diagnosis is confirmed by the immuno-histochemical study which concluded to a malignant neuroendocrine carcinoma of Merkel with a positive labelling of the tumour cells with anti-estrogens evaluated at 40%, in addition, the absence of labelling with anti-progesterones, mamaglobin, GCDEP15 and GATA3 was noted. Also, absence of labelling with synaptophysin, chromogranin, CK7 and CK20. Under general anaesthesia, the

patient was given additional excision, passing laterally at 2 cm from the tumour, and in depth, removing the clavi-pectoro-axillary fascia. Histological analysis of the specimen confirms the biopsy data and indicates that the lateral and deep excisional limits are healthy. There are no vascular emboli. Direct closure of the loss of skin substance was possible in 2 planes on an aspirating redon drain with application of a compression dressing. The sequelae were simple.

A thoracic X-ray was performed as part of the extension workup and showed no bone lysis, as well as a thoraco-abdominal-pelvic CT scan including no adenopathies.

The patient benefited from regular clinical monitoring in search of local, transit, lymph node or remote recurrence. The paraclinical surveillance will include a thoraco-abdomino-pelvic CT scan scheduled in 6 months.

## **II. DISCUSSION:**

The reputation of rarity of CNECs seems relative since Halioua and Ortonne (7) count 450 cases over a 15-year period. This tumour occurs in adult females, the average age of onset is 60 years (15-92 years), no cases are described in children. The tumour is almost exclusively of interest to Caucasians [8].

Merkel cell carcinoma (MCC) is a skin tumour belonging to the group of neuroendocrine carcinomas [5].

The main risk factors for MCC are advanced age, sun exposure and immunosuppression [9]. Very recently, a virus, now called Merkel cell polyomavirus, has been shown to be involved in the pathogenesis of TCM [5].

It is not only a locoregionally aggressive tumour, but also includes a high risk of distant metastasis. In a recent review of the literature covering 875 cases [10], local recurrence was noted in 25% of cases; regional lymph node metastatic extension appeared in 52%. Regional lymph node metastasis occurs in 52% of cases and distant metastasis is noted in 34%. In 34% of cases. The average time to recurrence is 3 to 16 months. The treatment of CNEC is based on wide surgical removal. Adjuvant radiotherapy of the tumour bed and prophylaxis of the drainage area appear to be beneficial in controlling the locoregional course of the disease [11], but due to the low incidence of CNEC, no prospective studies have been able to formally validate this therapeutic approach.

MCC is clinically presented as a cutaneous or subcutaneous nodule or plaque. The average diameter is 2 cm. It is generally well limited, not encapsulated and mobile in relation to the underlying planes, painless, non-pruritic, most often red then purplish in colour, spares the epidermis and grows rapidly [6,12]. The clinical presentation of the MCC is non-specific; a positive diagnosis is based on histological analysis of a biopsy or excision of the tumour, supplemented by immunohistochemistry that includes the presence of neuroendocrine markers. The possible tumour locations, in descending order, are: cervicocephalic region (54%), lower limbs (27%), upper limbs and trunk (19%) [6]. The mucous membranes are generally respected, and exceptionally lymphadenopathies or metastases may be indicative. Histopathologically, three different types of architecture are described [8]:

the trabecular type: is represented by spherical cell clusters with an abundant cytoplasm and a centered nucleus, soft tissue invasion is the rule. This typical form remains the least frequent;

Intermediate cell NECC with a structure reminiscent of pulmonary neuroendocrine carcinoma. The dissociation of the cells simulates a lymphomatous appearance. This is the most common variety;

Small cell NCCC: the pure forms cannot be distinguished from small cell carcinomas of the lung or other localizations.

The immunohistochemical study is of major interest because it represents the diagnostic element in difficult cases by eliminating rather easily especially, a lymphoma and a melanoma [6,8].

Surgical treatment involves both the site of the primary tumour and the lymph node drainage area. Several situations are possible:

In the absence of lymph node involvement and distant clinical or radiological metastasis: it is recommended that the tumour be resected with a clinically healthy lateral skin margin of 2-3 cm deep down to the fascia, which will be preserved in the absence of clinical invasion. Reconstruction is either immediate, which is often possible, or second intention in extended forms, and will favour simple techniques facilitating subsequent monitoring (direct suture, total skin grafting, etc.) to the detriment of complex flaps [6].

It is recommended to perform biopsy-exeresis of the sentinel lymph node for anatomopathological study.

In case of clinical or radiological lymph node involvement, and in the absence of distant visceral metastasis: lymph node removal is indicated, with extensive removal of the primary tumour.

If the biopsy of the sentinel lymph node has been carried out and the histological analysis is negative, there is no a priori indication for prophylactic radiotherapy in the drainage area. However, this can be discussed

at a multidisciplinary consultation meeting on a case-by-case basis, depending on the associated poor prognostic factors [6].

If drainage has been performed (clinical lymph node involvement or positive sentinel node), radiotherapy is recommended in the operated lymph node area.

Radiotherapy may be proposed as palliative treatment for some metastatic sites, taking into account the radiosensitivity of the tumour [12].

Adjuvant chemotherapy does not improve patient survival [13]. In cases of metastatic dissemination, chemotherapy remains the therapeutic weapon of choice, although there are no data showing an improved prognosis at this stage of the disease [6, 14, 15] where exclusive palliative management can be discussed.

Patients should be offered self-monitoring for other skin cancer, local, transit or lymph node recurrence. The frequency of monitoring should be discussed in relation to the associated risk factors.

### III. CONCLUSION

Cutaneous neuroendocrine carcinoma is a low-grade malignant tumour with low metastatic potential, but the recurrence rate is very high. It is an aggressive tumour with a sharply increasing incidence, mainly due to the ageing population. It is important to know this entity because it can simulate a metastasis of mammary or digestive origin. The diagnostic and therapeutic management of this tumour is not codified, based essentially on surgery but whose prognosis remains gloomy despite current therapeutic progress.

#### Conflicts of interest

The authors do not declare any conflict of interest.

#### Authors' contributions

All authors contributed to the development of this article. They have read and approved the contents of this article.

#### REFERENCE:

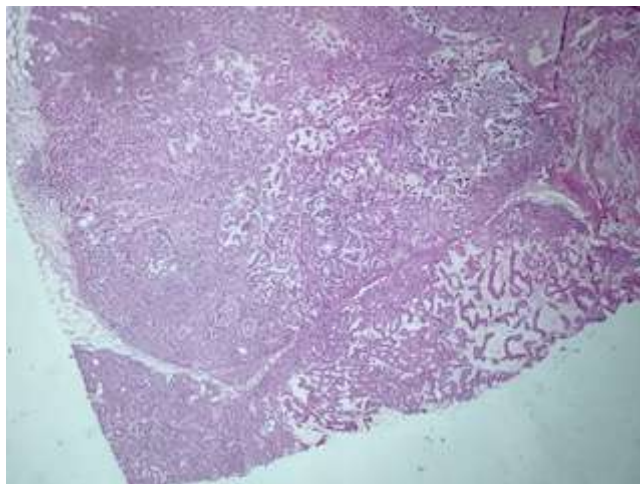
- [1]. Ihsane Souaf , Hassania Ameurtesse, Fatema Zehra Debbagh, Karima Idrissi, Kawter Znati, Affaf Amarti : Carcinome mucineux primitif cutané: à propos de deux cas et d'une revue de la littérature
- [2]. Pan African Medical Journal. 2014; 18:340 doi:10.11604/pamj.2014.18.340.2970
- [3]. D. LEBAS, O. CARPENTIER, E. MARTIN DE LASSALLE, M.-O. VILAIN, F. PIETTE : Carcinome neuroendocrine cutané primitif géant de la jambe
- [4]. Ann Dermatol Venereol 2004;131:579-82
- [5]. Le Boit PE, Burg G, Weedon D, Sarasain A. World Health Organization Classification of Tumours: Pathology and Genetics of Skin Tumours.
- [6]. Lyon, IARC Press. 2006.
- [7]. Nadia Kourda, Ines Zaraq, Leila Abid, Karima Zitouni, Ali Adouani, Sarah Baltagi-Ben Jilani, Rachida Zermani. Carcinome mucineux primitif cutané.
- [8]. Annales de Pathologie. 2006;26(3):211-21. PubMed | Google Scholar
- [9]. M. Benessahraoui a, V. Dalstein a, F. Lorchel b, M.-P. Algros c, E. Puzenat a, P. Louvat d, B. Hassam e, P.-H. Humbert a, F. Aubin : Carcinome à cellules de Merkel : étude descriptive de 24 cas (1993–2001)
- [10]. La revue de médecine interne 24 (2003) 560–56
- [11]. Samira Boukind, Oumkeltoum Elatiqi, Meriem Dlimi, Driss Elamrani, Yassine Benchamkha, Saloua Ettalbi : Le carcinome neuroendocrine cutané primitif: à propos d'un nouveau cas et revue de la littérature
- [12]. Pan African Medical Journal. 2015; 20:395 doi:10.11604/pamj.2015.20.395.6149
- [13]. B. HLILOUA, J.P. ORTONNE. Les carcinomes neuro-endocrines cutanés.
- [14]. Ann. Dermatol. Vénérolog. 1988, 115, 1305-1322.
- [15]. H. HACHI(1), A. BOUGTAB (1), L. GAMRA (2), F. TIJAMI (2), CH. BAROUDI (1), A. OTTAMANY (1), A. JALIL (1), S. BENJELLOUNE (1), F. AHYOUD (1), A. SOUADKA : LE CARCINOME A CELLULES DE MERKEL A PROPOS D'UN NOUVEAU CAS ET REVUE DE LA LITTERATURE
- [16]. Médecine du Maghreb 1996 n°60
- [17]. Houssine Boufettal, Mohammed Noun, Sakher Mahdaoui, Saïd Hermas, Naïma Samouh :
- [18]. Une tumeur du sein inhabituelle : le carcinome endocrine mammaire primitif
- [19]. Imagerie de la Femme, 2011-03-01, Volume 21, Numéro 1, Pages 35-38
- [20]. AkhtarS,OzaKK,WrightJ : Merkelcellcarcinoma: reportof10casesand review of the literature.
- [21]. J Am Acad Dermatol 2000;43:755-67
- [22]. Medina-Franco H, Urist MM, Fiveash J, Heslin MJ, Bland KI, Beenken SW : Multimodality treatment of Merkel cell carcinoma: case series and literature review of 1024 cases.
- [23]. Ann Surg Oncol 2001;8:204-8.
- [24]. Boccara O, Girard C, et al : Recommandations du groupe de cancérologie cutanée de la Société française de dermatologie pour la prise en charge diagnostique et thérapeutique du carcinome à cellules de Merkel.
- [25]. Annales de Dermatologie et de Vénérologie. 2011 Jun-Jul;138(6-7):475–482. [PubMed] [Google Scholar]
- [26]. Ganeski KM, Nghiem P. Merkel cell carcinoma adjuvant therapy: Current data support radiation but not chemotherapy. J Am Acad Dermatol. 2007 Jul;57(1):166–9. [Article PMC gratuit] [PubMed] [Google Scholar]
- [27]. Tai PT, Yu E, Winquist E, Hammond A, Stitt L, Tonita J. Chemotherapy in neuroendocrine/Merkel cell carcinoma of the skin: cases series and review of 204 cases. J Clin Oncol. 2000 Jun;18(12):2493–9. [PubMed] [Google Scholar]
- [28]. Poulsen MG, Rischin D, Porter I, Walpole E, Harvey J, Hamilton C, et al. Does chemotherapy improve survival in high-risk stage I and II Merkel cell carcinoma of the skin? Int J Radiat Oncol Biol Phys. 2006 Jan;64(1):114–9. [PubMed] [Google Scholar]

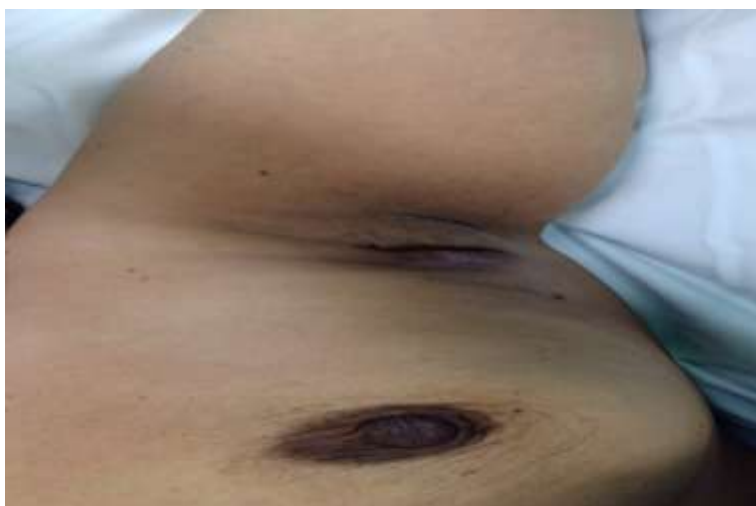

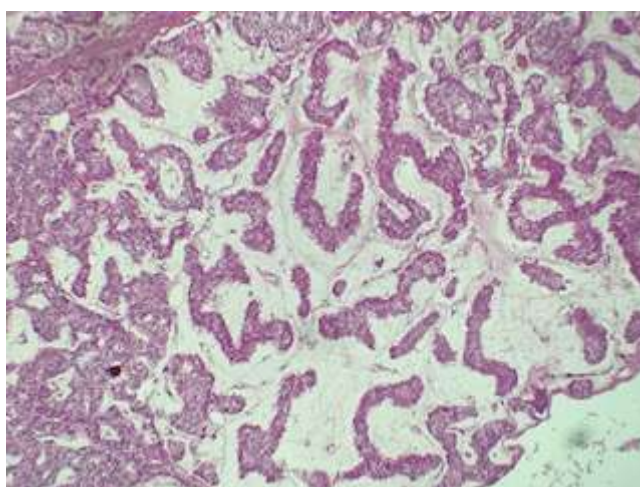
figure1 : clinical aspect of the tumor

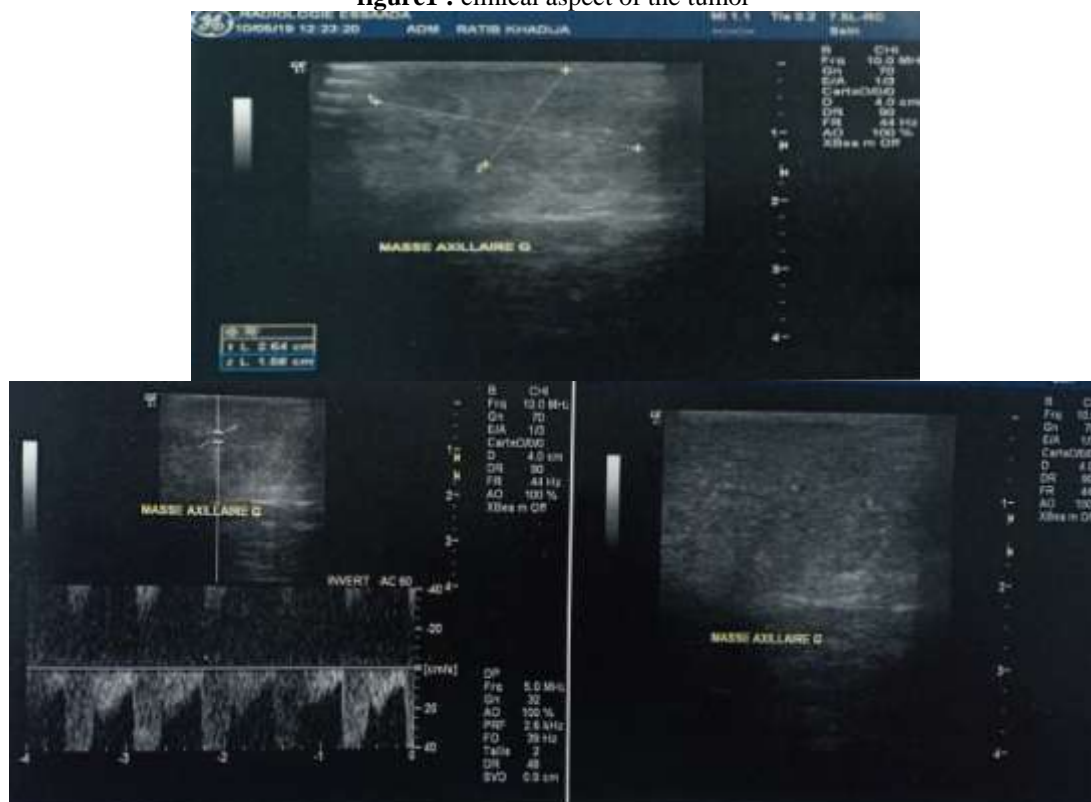

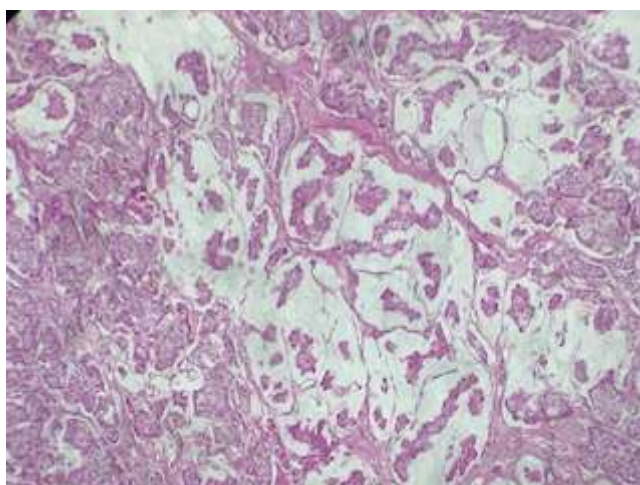
Figure2 : ultrasound image of the tumor



Hex10 low magnification. Showing carcinomatous proliferation of solid architecture with mucinous component.

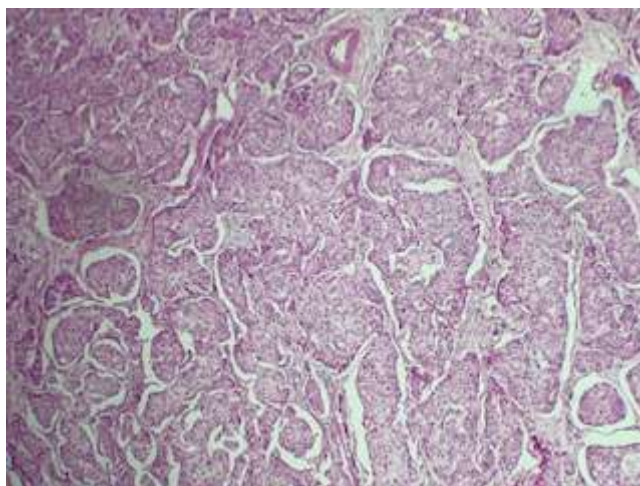


The 2ndHEX20mid magnification: eccrine component made of tubes and trabeculae and strands of tumour cells knotted in mucin puddles.

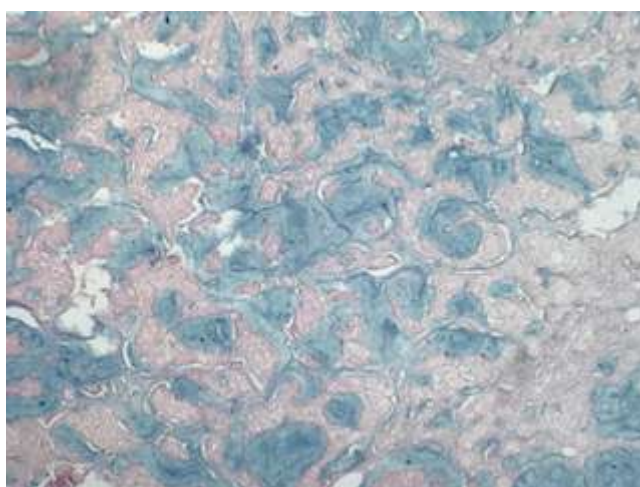


the 3rd HEX20; coalescing eccrine and neuroendocrine tumor components.

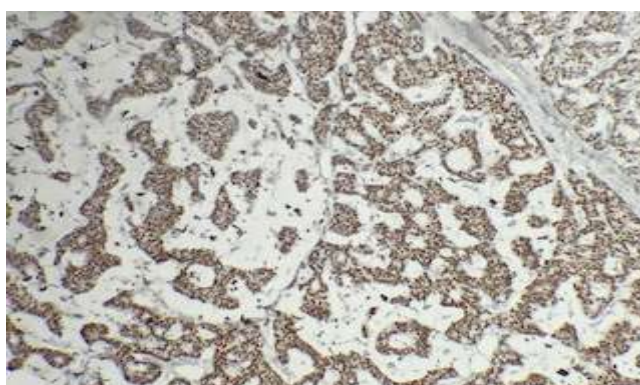




The 4th HEx20: Tumoral organelle component of Neuroendocrine architecture.



HEx10: special alcian blue staining showing mucin puddles.



Hex10: diffuse nuclear positivity from tumor cells to anti-estrogen receptors.

**Figure 3** : anatomopathological aspects of the lesion

A achboug " Primary axillary cutaneous neuroendocrine carcinoma of the skin : about a case and literature review » Quest Journals of Medical and Dental Science Research 7.1 (2020): 11-16.