



Research Paper

Duodenal Obstruction in Neonates – A Retrospective Analysis

Dr . Priya Shalini Lakra, Dr. Jay Kishor Soren.
Department of Paediatric Surgery, NRS Medical College, Kolkata

ABSTRACT

AIM-To analyse demography, clinical presentation ,operative findings ,procedure undertaken ,outcome in paediatric patients with duodenal obstruction.

METHODS – 100 cases of duodenal obstruction in the paediatric population within 2 year were studied regarding their time of presentation, duration of symptoms, operative finding and procedure that were undertaken and their outcome which were analysed.

RESULTS - Most of the patients presented in first week of life 58% . Equal number of male and female . Most of the patients presented with low birth weight i.e. 82%. 70.59% of the deaths were those that presented after 7 days of life. Majority presented with cases of Duodenal atresia (66%) as a cause of duodenal obstruction

CONCLUSION-Antenatal diagnosis should be improved for early detection of obstruction . Early diagnosis and proper resuscitation of the patient is necessary

Received 29Apr, 2020; Accepted 13 May, 2020 © the Author(S) 2020.
Published With Open Access At www.Questjournals.Org

I. INTRODUCTION

Congenital duodenal obstruction is a rare congenital anomaly. The incidence of duodenal obstruction in neonates 1 in 10000 to 1 in 40000 births.[1]

Several intrinsic and extrinsic congenital lesions can lead to complete or partial obstruction of the duodenum, including embryologic defects in the development of the foregut, disturbances in recanalization or rotation, and abnormal embryologic relationships with neighboring anatomical structures.[2] Intrinsic duodenal obstruction can be caused by duodenal atresia, stenosis, or diaphragm and extrinsic duodenal obstruction can be caused by annular pancreas, malrotation, or preduodenal portal vein.[3]

These days, approximately , half of all cases are detected antenatally on fetal ultrasonography with the characteristic presence of a ‘double bubble’ sign in the upper abdomen representing dilated fluid-filled stomach and proximal duodenum.

Classical presentation of duodenal obstruction in newborn- bilious vomiting with scaphoid abdomen. Genetic and structural abnormalities including chromosomal anomalies should be considered since associated anomalies, including cardiac and aneuploidy, are common occurring in up to 84% of infants depending on the reported population [4].

Advances in surgical management, intensive care medicine, and postoperative nutritional support over the last decades have contributed greatly to improved survival of newborns with duodenal obstruction

AIMS

To analyse demography, clinical presentation , operative findings, procedure undertaken, outcome.

II. METHODS AND METHODOLOGY

100 patients admitted in the Department of Paediatric Surgery, NRS Medical College, Kolkata between 2017 to 2019 with features of duodenal obstruction were studied regarding their time of presentation, duration of symptoms, operative finding and procedure that were undertaken and their outcome which were analysed.

INCLUSION CRITERIA

Patients with X-ray suggestive of duodenal obstruction

EXCLUSION CRITERIA

- 1) Patients with diagnosed cases of malrotation
- 2) Other forms of intestinal atresia

III. METHODOLOGY

Patients with bilious vomiting and X ray abdomen suggestive of duodenal obstruction were taken for emergency surgery.

IV. RESULTS

Most of the patients presented in first week of life(58%) . All the patients had symptoms since birth of varying severity. Equal number of male and female . Most of the patients presented with low birth weight [82%]. Mean body weight in the neonatal age group is 1.91 kg. 52% of patients belonged to Hindu religion.70.59% of the deaths were those that presented after 7 days of life. Majority presented with cases of Duodenal atresia (66%) as a cause of duodenal obstruction.

DEMOGRAPHIC PROFILE

CHARACTERISTICS	NO. OF PATIENTS
> AGE AT PRESENTATION	
< 7 DAYS	58
>7 DAYS	42
> SEX	
MALE	50
FEMALE	50
> BODY WEIGHT	
<1KG	0
<1.5 KG	14
<2.5 to >1.5KG	68
Equal to or above 2.5KG	18
> RELIGION	
HINDU	52
MUSLIM	48
OTHERS	0
> CLINICAL PRESENTATION	
BILIOUS VOMITING	90
OTHERS	10

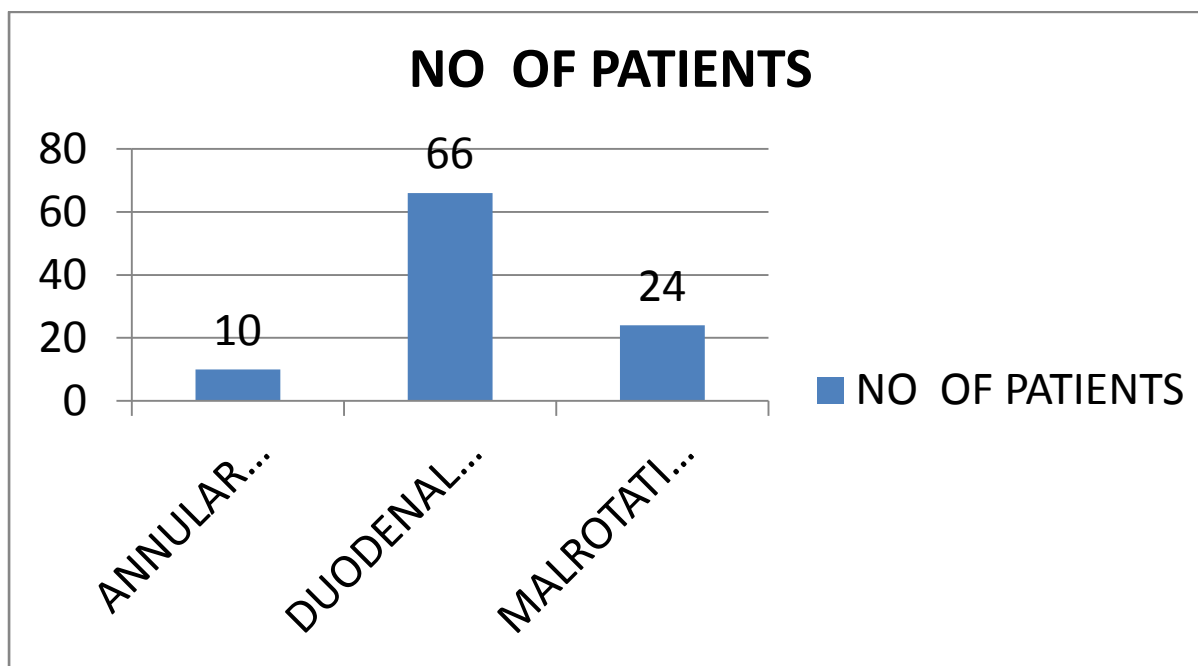


Figure 1: CAUSES OF DUODENAL OBSTRUCTION

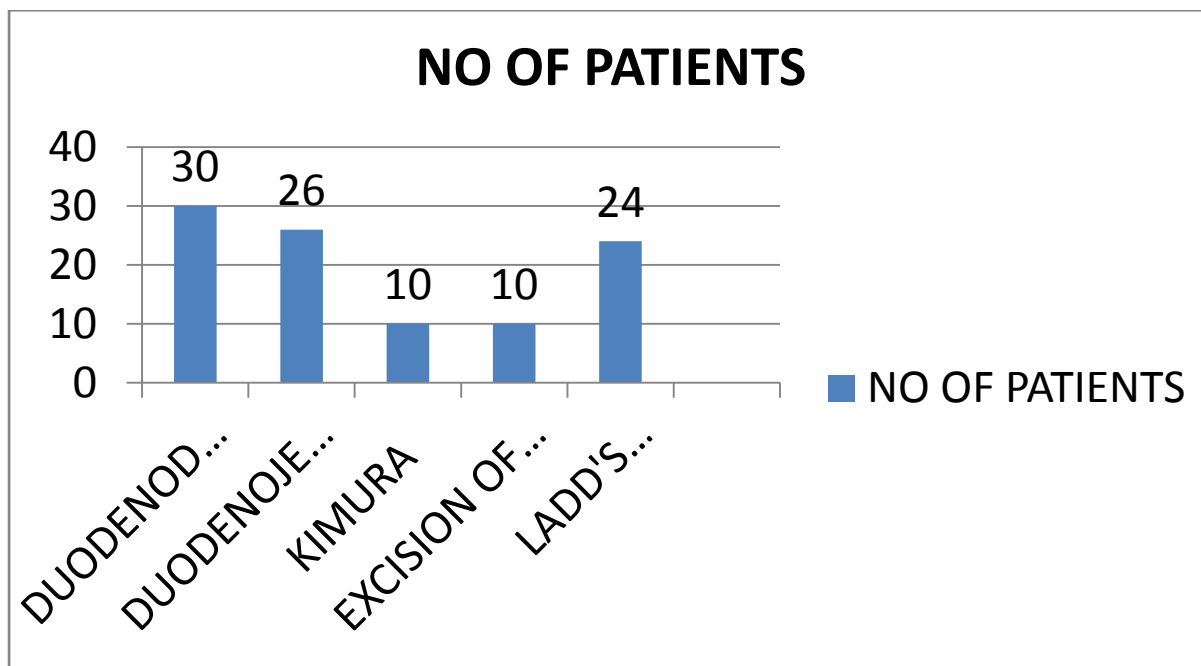


Figure 2: OPERATIVE INTERVENTION

V. DISCUSSION

Most common cause of duodenal obstruction in neonates is duodenal atresia and least common cause being annular pancreas. Almost all of the neonates presented with bilious vomiting. 82% cases were associated with low birth weight. Mean body weight of patients in the study group is 1.91 kg. In a study by Qing-Jiang Chen et al average birth weight in patients of duodenal obstruction 3048.33 ± 625.40 g. [6]

No cases were diagnosed antenatally. The overall prenatal detection rate of 59% is similar to the 53% reported in a single centre study from the USA and 52% from a European prenatal ultrasound population-based study. [7, 8]

There was an equal proportion of male and female patients. Most of the studies show male predominance in the disease. But results found in study by Norman et al showed similar results. [9]

We had taken religion as a factor for the demographic profile as some religion have a higher incidence of congenital anomalies due to consanguineous marriages. Most of the patients belonged to Hindu religion in our study.

58% of the patients in our study presented at less than 7 days of life. In study by George Stephen Bethell et al the median age of first review by a paediatric surgeon was 0 (0–13) days. [10]

90% of patients presented with bilious vomiting in our study. In a study by H Kilbride majority of the patients presented with bilious vomiting. [8]

Association was found with Tracheoesophageal fistula, Anorectal malformation, Down's syndrome, Prune belly Syndrome, Malrotation. The most frequently associated anomalies were cardiac, seen overall in 48% in study by George Stephen Bethell.

66 cases of duodenal atresia, 24 cases of malrotation and 10 cases of annular pancreas were found in our study.

The operative intervention depends on the type of obstruction.

8 patients were found to have leak postoperatively, 10 had wound dehiscence.

Total mortality was 37%. Mortality was more in the patients that presented after 7 days of life in neonatal group. Congenital duodenal obstruction carries significant morbidity and mortality because of low birth weights, associated complex anomalies, and postoperative complications. Causes of death in our study was assumed to be the low birth weight, dehydration status of the patient, postoperative complication associated anomalies and sepsis in these patients.

VI. CONCLUSION

The mortality of patients with congenital duodenal obstruction in our study are significantly high. Antenatal diagnosis should be improved for early detection of obstruction. Early diagnosis, proper preoperative resuscitation and nutrition of the patient is essential for dealing with this congenital disease. Effective measures are urgently needed to improve the outcome.

REFERENCES

- [1]. Nixon HH, Tawes R: Etiology and treatment of small intestinal atresia. *Surgery* 69: 4 1—51, 1971.
- [2]. Bailey PV, Tracy TF JrConnors RH, Mooney DP, Lewis JE, Weber TR. Congenital duodenal obstruction: a 32-year review. *J Pediatr Surg* 1993;28:92-95.
- [3]. Mustafawi AR, Hassan ME. Congenital duodenal obstruction in children: a decade's experience. *Eur J Pediatr Surg* 2008;18:9397.
- [4]. Ladd WE. Congenital duodenal obstruction. *Surgery* 1937;1:878885
- [5]. Takahashi D, Hiroma T, Takamizawa S, et al. Population-based study of esophageal and small intestinal atresia /stenosis. *Pediatr Int* 2014;56:838–44
- [6]. Qing-Jiang Chen, Zhi-Gang Gao, Jin-Fa Tou, Yun-Zhong Qian, Min-Ju Li, Qi-Xing Xiong, Qiang Shu. Congenital duodenal obstruction in neonates: a decade's experience from one center. *World J Pediatr*, Vol 10 No 3 . August 15, 2014.
- [7]. Haeusler MC, Berghold A, Stoll C, et al. Prenatal ultrasonographic detection of gastrointestinal obstruction: results from 18 European congenital anomaly registries. *Prenat Diagn* 2002;22:616–23.
- [8]. Kilbride H, Castor C, Andrews W. Congenital duodenal obstruction: timing of diagnosis during the newborn period. *J Perinatol* 2010;30:197-200
- [9]. Norman CH, Pacis AB. Congenital duodenal web in an adult. *J Natl Med Assoc* 1978; 70: 797-8
- [10]. Bethell GS, et al. *Arch Dis Child Fetal Neonatal Ed* 2019;0:F1–F6. doi:10.1136/archdischild-2019-317085

Dr . Priya Shalini Lakra, et. al. "Duodenal Obstruction in Neonates – A Retrospective Analysis." Quest Journals of Medical and Dental Science Research 7.1 (2020): 31-34.