



Research Paper

## Management of open apex with using platelet rich fibrin matrix and mineral trioxide aggregate as apical barrier: A Single Step Apexification(CASE REPORT)

Dr. Seema D. Pathak<sup>1</sup>, Dr. Pradnya V. Bansode<sup>2</sup>, Dr. M.B. Wavdhane<sup>3</sup>, Dr. Rinky Hajong<sup>4</sup>

1. Professor, Department of conservative dentistry and endodontics, GDC & Hospital, Aurangabad/ MUHS, India
2. Head of the department, Professor, Department of conservative dentistry and endodontics, GDC & Hospital, Aurangabad/ MUHS, India
3. Associate professor, Department of conservative dentistry and endodontics, GDC & Hospital, Aurangabad/ MUHS, India
4. MDS Student, Department of conservative dentistry and endodontics, GDC & Hospital, Aurangabad/ MUHS, India

\*Corresponding Author: Dr. Rinky Hajong

### ABSTRACT

Apexification is a procedure for closure of the open apex in an immature necrotic tooth. The absence of a natural apical constriction in a nonvital permanent tooth makes endodontic treatment a challenge. There is a need to induce or create an apical barrier against, which the obturating material can be condensed. Traditionally, calcium hydroxide is considered as the gold standard to induce apexification. Due to certain drawbacks such as very long treatment period, possibility of tooth fracture, and incomplete apical barrier formation, it is being replaced by materials, which have a more predictable outcome like mineral trioxide aggregate (MTA). One-step apexification with MTA reduces the treatment time when compared with traditional calcium hydroxide apexification, which requires an average time of 12–19 months. In one-step apexification using MTA, the technical problem encountered is controlling the overfill or underfill of MTA. The use of a matrix material helps to overcome this shortcoming. Platelet rich fibrin (PRF) is an immune platelet concentrate, which can be used as a matrix, it also promotes wound healing and repair. This case report presents a case of one step apexification using MTA as an apical barrier and autologous PRF as an internal matrix.

**KEYWORDS:** Apexification, apical plug, mineral trioxide aggregate trioxide aggregate, one-step apexification, open apex, platelet rich fibrin.

Received 16 November, 2020; Accepted 20 December, 2020 © The author(s) 2020.

Published with open access at [www.questjournals.org](http://www.questjournals.org)

### I. INTRODUCTION

Apexification is the process of induction of calcific barrier across the open apex or the continued development in the apical region in an immature tooth with necrotic pulp.<sup>1</sup> Traditional approach of apexification procedure involves the induction of formation of an apical barrier while, in the recent times, an artificial apical barrier is formed by the placement of various materials which included tricalcium phosphate, freeze-dried bone, freeze-dried dentin, and mineral trioxide aggregate (MTA). However, these materials tend to extrude beyond the apex impinging on the periodontal tissue. The placement of an artificial barrier or a matrix provides an apical stop against which sealing material can be placed and packed. Several materials proposed to create a matrix include calcium hydroxide, absorbable collagen, hydroxyapatite, and autologous platelet-rich fibrin (PRF) membrane.<sup>2</sup> In recent times, MTA has gained considerable attention for single-visit apexification.<sup>3</sup>

Various studies using MTA for apexification have shown promising results. The advantage of MTA apexification are: (i) Reduction in treatment time (ii) possibility to restore the tooth with a minimal delay (iii) no changes in the mechanical properties of dentine (iv) excellent biocompatibility and (v) stimulation of repair.<sup>4</sup>

Platelet rich fibrin (PRF) which is a second generation platelet concentrate can be used as a resorbable matrix material against which MTA apical barrier can be placed. PRF is a matrix of autologous fibrin, in which are embedded a large quantity of platelet and leukocyte cytokines during centrifugation. PRF was first described by Choukroun et al. in France. It has been shown to have several advantages such as ease of preparation, autologous, promotion of wound healing, bone growth, bone maturation and hemostasis.<sup>5</sup>

This case report describes the management of an immature tooth (with open apex) with a single-step apexification procedure with MTA apical barrier and autologous PRF membrane as an internal matrix

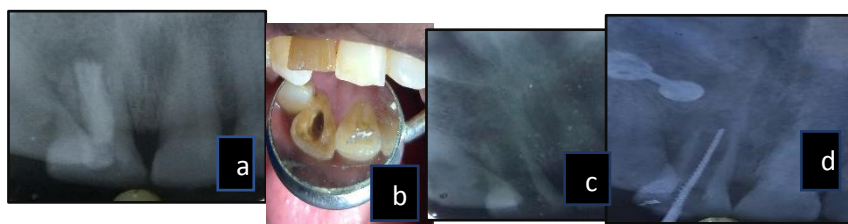
## II. CASE REPORT

A 50-year-old female patient reported to the department with chief complaint of pain in the upper right front tooth region. She gave a history of trauma 35 years back. At that time, the patient consulted the dentist and Root Canal Treatment was done with tooth 11. The patient was asymptomatic since then. On intraoral clinical examination, it was found the affected tooth 11 to be discolored and tender on percussion. Radiographic examination showed that periapical lesion was present on the apical region of the right central incisor and wide open apices with incomplete obturation [Figure 1a]. The treatment suggested to the patient was nonsurgical root canal treatment with single visit apexification procedure using apical plug of MTA.

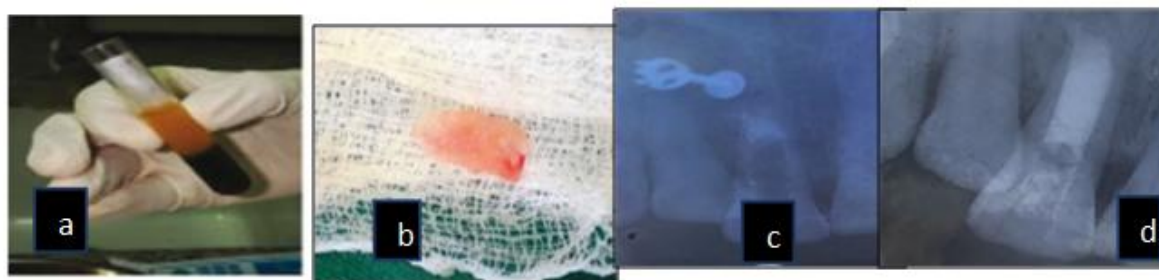
After administration of local anesthesia, the removal of earlier filled Gutta Percha from the canal was done using H Files [Figure 1b,c]. Working length was determined with a K file and was confirmed radiographically [Figure 1d]. Root canal preparation was done with a no.70 k file (Dentsply Maillefer, Ballaigues, Switzerland) using circumferential filing motion. Root canal debridement was done using alternate irrigation with 1.25% NaOCl and saline and a final irrigation with 2% chlorhexidine. The canal was dried with paper point, and Calcium Hydroxide was placed as an intracanal medicament and the access cavity was sealed with a temporary restoration. At the next 1 week recall appointment, the tooth was asymptomatic and non-tender on percussion. It was decided to use PRF membrane as an internal matrix against which MTA would be placed as an apical barrier. The intracanal medicament was removed from the canal using copious irrigation with saline. The canal was debrided further with NaOCl and saline, and final irrigation was done with chlorhexidine. The canal was dried with paper point.

Platelet rich fibrin membrane was prepared using the procedure described by Dohan et al., blood (8.5 ml) was drawn by venipuncture of the antecubital vein. This blood was collected in a 10 ml sterile glass tube without anticoagulant, and was centrifuged immediately at 3000 revolutions/min (rpm) for 10 min. After the centrifugation the resultant in the glass tube consisted of the topmost layer of acellular platelet poor plasma, PRF clot in the middle and red blood cell's at the bottom [Figure 2a]. The PRF clot was squeezed in a piece of sterile gauze to obtain a PRF membrane [Figure 2b]. PRF membrane was introduced into the canal and was gently compacted using hand pluggers to form an apical barrier at the level of apex. MTA PROROOT (MTA™ Dentsply, India) was mixed according to the manufacturer's instructions and was placed in the apical portion of canal against the PRF matrix, subsequent increments were condensed with hand pluggers till a thickness of 4 mm [Figure 2c]. A wet cotton pellet was placed into the canal, access cavity was sealed with temporary cement.

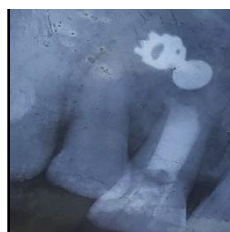After 1 week the patient was asymptomatic, temporary restoration and cotton pellet was removed. A hand plunger was tapped against the MTA barrier to confirm the setting of MTA. The remaining portion of the canal was backfilled with thermoplastized gutta-percha (Calamus Dual, Dentsply Maillefer, Switzerland) with AH Plus resin sealer (Dentsply DeTrey, Germany) [Figure 2d]. The tooth was immediately restored with a composite restoration (Dentsply Spectrum composite kit). Three month follow-up revealed the patient remained asymptomatic with restored esthetics and functions [Figure 3]



**Figure 1: (a) Preoperative Radiograph (b) Intra-oral picture wrt 11 after removal of Gutta Percha (c) Radiograph after removal of Gutta Percha wrt 11 (d) working length radiograph**



**Figure 2: a) Preparation of platelet rich fibrin (PRF), (b) PRF Membrane retrieved, (c) placement of PRF into the tooth and MTA Plug, (d) Post Obturation Radiograph**



**Figure 3: Follow up Radiograph after 3 months**

### III. DISCUSSION

The major problem in cases of a wide open apex is the need to limit the material, thus avoiding the extrusion of a large amount of material into the periodontal tissue. Using a matrix avoids the extrusion of the material into the periodontal tissues, reduces leakage in the sealing material and allows favorable response of the periodontal tissues. The apical barrier technique utilizing calcium sulfate or a combination of calcium sulfate and collagen in a powdered form has been performed in the past. Various materials have been used for formation of apical barrier during apexification. This case report has introduced a new concept of using PRF as an apical matrix membrane. PRF is a matrix of autologous fibrin, in which are embedded a large quantity of platelet and leukocyte cytokines during centrifugation.<sup>5</sup> The intrinsic incorporation of cytokines within the fibrin mesh allows for their progressive release over time (7-11 days)<sup>6</sup>, as the network of fibrin disintegrates.<sup>7</sup> The easily applied PRF membrane acts much like a fibrin bandage serving as a matrix to accelerate the healing of wound edges.<sup>8</sup>

According to Simonpieri et al (2009)<sup>9</sup>, the use of this platelet and immune concentrate offers the following many advantages: Firstly, the fibrin clot plays an important mechanical role, with the PRF membrane maintaining and protecting the grafted biomaterials and PRF fragments serving as biological connectors between bone particles. Secondly, the integration of this fibrin network into the regenerative site facilitates cellular migration, particularly for endothelial cells necessary for the neo-angiogenesis<sup>10</sup>, vascularization and survival of the graft. Third, the platelet cytokines (PDGF, TGF- $\beta$ , IGF-1) are gradually released as the fibrin matrix is resorbed, thus creating a perpetual process of healing.<sup>10</sup> Lastly, the presence of leukocytes and cytokines in the fibrin network can play a significant role in the self-regulation of inflammatory and infectious phenomena within the grafted material. The combination of PRF membrane as a matrix and MTA has been demonstrated to be an effective alternative for creating artificial root-end barriers and to induce faster periapical healing for single visit apexification of the cases with large periapical lesions.

### IV. CONCLUSION

The combination of PRF as a matrix and MTA as an apical barrier can be considered as a good option for single-step apexification procedure. It has shown promising results with successful clinical outcome.

### REFERENCES

- [1]. Trope M. Treatment of immature teeth with non vital pulps and apical periodontitis. *Endotopic*2007;14:51-9.
- [2]. Lemon RR. Nonsurgical repair of perforation defects. Internal matrix concept. *Dent Clin North Am* 1992;36:439-57.
- [3]. Parirokh M, Torabinejad M. Mineral trioxide aggregate: A comprehensive literature review – Part I: Chemical, physical, and antibacterial properties. *J Endod*2010;36:16-27
- [4]. Simon S, Rilliard F, Berdal A, Machtou P. The use of mineral trioxide aggregate in one-visit apexification treatment: A prospective study. *Int Endod J* 2007;40:186-97.
- [5]. Dohan DM, Choukroun J, Diss A, Dohan SL, Dohan AJ, Mouhyi J, et al. Platelet-rich fibrin (PRF): A second-generation platelet concentrate. Part I: Technological concepts and evolution. *Oral Surg Oral Med Oral Pathol Oral Radiol Endod* 2006;101:e37-44.
- [6]. Yoshida T, Itoh T, Saitoh T, Sekine I Histopathological study of the use of freeze-dried allogenic dentin powder and True Bone Ceramic as apical barrier materials. *J Endod.* 1998;24:581-6

- [7]. Huang FM, Yang SF, Zhao JH, Chang YC Platelet-rich fibrin increases proliferation and differentiation of human dental pulp cells. *J Endod.* 2010;36:1628-31
- [8]. Gaßling VLW, Açil,Y, Springer IN, Hubert N, Wiltfang J Plateletrich Plasma and Platelet-rich fibrin in human cell culture. *Oral Surg Oral Med Oral Pathol Oral RadiolEndod.* 2009;108:48-55.
- [9]. Simonpieri A, Del Corso M, Sammartino G, Dohan Ehrenfest DM The Relevance of Choukroun's Platelet-Rich Fibrin and Metronidazole during Complex Maxillary Rehabilitations Using Bone Allograft. Part II: Implant Surgery, Prosthodontics, and Survival. *Implant Dent.* 2009;18:220-9.
- [10]. Mazor Z, Peleg M, Garg AK, Luboshitz J Platelet-rich plasma for bone graft enhancement in sinus floor augmentation with simultaneous implant placement: patient series study. *Implant Dent.* 2004;13:65-72

Dr. Rinky Hajong, et. al. "Management of open apex with using platelet rich fibrin matrix and mineral trioxide aggregate as apical barrier: A Single Step Apexification(CASE REPORT)." *Quest Journals of Medical and Dental Science Research* 7.6 (2020): 37-40.