



Endodontic Management of Hypertaurodontism: A Case Report

Dr. Pradnya V. Bansode¹, Dr. Seema D. Pathak², Dr. M.B. Wavdhane³,
Dr. Sameer S. Khedkar⁴

1. Professor, Head of the department , Department of conservative dentistry and endodontics, GDC & Hospital, Aurangabad/ MUHS, India
 2. Professor, Department of conservative dentistry and endodontics, GDC & Hospital, Aurangabad/ MUHS, India
 3. Associate professor, Department of conservative dentistry and endodontics, GDC & Hospital, Aurangabad/ MUHS, India
 4. MDS Student, Department of conservative dentistry and endodontics, GDC & Hospital, Aurangabad/ MUHS, India
- *Corresponding Author: Dr. Sameer S. Khedkar

ABSTRACT

Taurodontism is a rare dental anomaly in which the involved tooth has an enlarged and elongated body and pulp chamber with apical displacement of the pulpal floor. Endodontic treatment of a taurodont tooth is challenge to a clinician and requires special handling because of the proximity and apical displacement of the roots. The present article describes the diagnosis and management of hypertaurodontism by endodontic treatment in a right maxillary first molar.

Key words: Pulp chamber, root canal, taurodontism.

Received 10 Jan, 2021; Revised: 22 Jan, 2021; Accepted 25 Jan © The author(s) 2021.

Published with open access at www.questjournals.org

I. INTRODUCTION

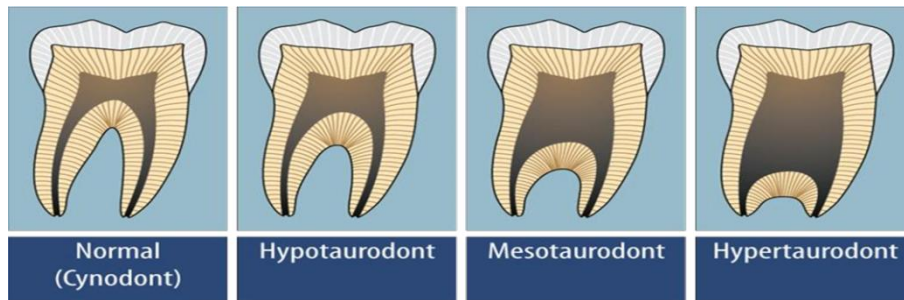
- ▶ The term taurodontism comes from the Latin term tauros, which means ‘bull’ and the Greek term -odus, which means ‘tooth’ or ‘bull tooth’.[1]
- ▶ Taurodontism is the tooth anomaly showing change in the tooth shape with enlarged tooth body on the expense of roots which are reduced in size. Such cases may have enlarged pulp chamber which may reach close to the root apex and apically displaced furcation areas. Sometimes, these furcal areas may be only a few millimeters above the roots apices.[3]
- ▶ Taurodontism was first explained by Gorjanovic - Kramberger (1908).[2]

ETIOLOGY & PATHOGENESIS

- ▶ The etiology behind the taurodontism anomaly is supposed to be a primitive pattern, a mutation, a specialized or retrograde character, an X-linked trait, familial or an autosomal dominant trait as per various theories reported earlier.
- ▶ Several theories of pathogenesis of such anomaly have also been proposed: an unusual developmental pattern, a delay in pulpal chamber calcification, Hertwig’s epithelial root sheath (HERS) alteration, an odontoblastic deficiency. [4,6]

CLASSIFICATION

- ▶ Based on the relative displacement of pulp chamber floor, taurodontism can be of three types - hypotaurodontism, mesotaurodontism and hypertaurodontism (Shaw, 1928)



▶ Later on, Rossiwall (1977) clearly confirmed that a tooth to be categorized as taurodontic tooth, if the distance from the bifurcation or trifurcation of the root to the cemento-enamel junction (CEJ) should be greater than the occluso-cervical height. [6,7]

DIAGNOSIS

Anatomic Features: There is elongated and enlarged pulp chamber having greater occluso-cervical height than normal that results in its apical extension below the CEJ.

▶ It also generates a rectangular shape of tooth as the CEJ constriction is less marked than that of the normal tooth.

▶ Also, the bifurcation or trifurcation of molars is apically displaced, resulting in shorter roots than normal one and enlarging the body of the tooth.[8]

Clinical Features: Clinically, a taurodont seems as a normal tooth. Since the body and roots of a taurodont tooth is found to be below the alveolar margin, it is very difficult to recognize it clinically. Therefore, the taurodontism is usually distinguished from well developed diagnostic and/or digital radiographs[8]

Radiographic features: The radiographic characteristics of taurodont tooth include: Extremely large pulp chamber with a greater apico-occlusal height than normal and lacks the usual constriction at the cervical region of the teeth with exceedingly short roots and root canals, location of bifurcation or trifurcation (near the root apices), despite a normal crown size[5]

▶ Finally, for the endodontic management of such taurodontic tooth, it becomes very important to have high-quality diagnostic radiographs. Cone Beam Computed Tomography (CBCT) is a new diagnostic imaging method that is very useful for effective evaluation of root canal morphology. It has proved its importance in locating and identifying root canals, especially in case of anatomic variations and difficulties.[2,7]

Differential diagnosis

▶ Certain metabolic conditions like pseudohypoparathyroidism, hypophosphatasia, and hypophosphatemic vitamin D-resistant and dependent rickets (Enlarged pulp chamber but with normal tooth form).

▶ Early stages of dentinogenesis imperfecta (Appearance may resemble the large pulp chambers).

▶ The developing molars may appear similar to taurodonts (but they differ with wide apical foramina and incompletely formed roots).

II. CASE REPORT

▶ A 28-year-old male patient reported to the department of conservative dentistry and endodontics in our institution with a chief complaint of pain in maxillary right posterior region for 2 weeks. On clinical examination, proximal caries with respect to 16 was seen and the tooth was tender on percussion. (fig 1)

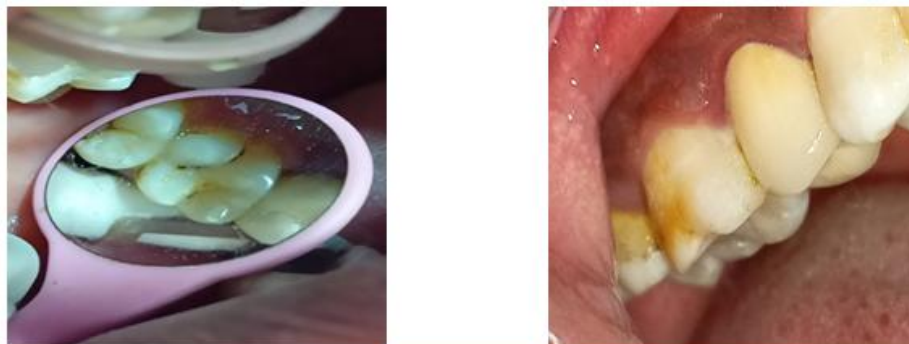

Figure 1

The preoperative radiograph revealed a large pulp chamber and short roots, indicating taurodontism . Furthermore, deep caries involving the pulp seen with respect to 16.(fig 2)

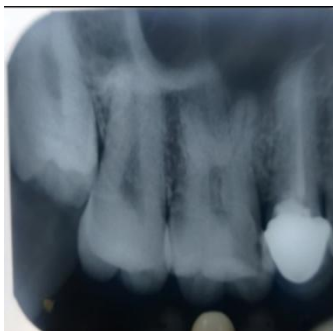

Figure 2

There was no relevant medical and family history which confirmed that taurodontism in this case was not associated with any other syndromes or diseases. A diagnosis of acute irreversible pulpitis was made with respect to 16 based on the radiographic findings. The tooth was indicated for a nonsurgical root canal treatment, the patient was explained about the treatment plan, and he was willing for endodontic treatment.

Firstly, the patient was given a block injection of lidocaine with 1:80,000 epinephrine. Isolation is one of the keys to success of endodontic therapy. Before starting with the access cavity preparation, the tooth was isolated with rubber dam. Following this, the access cavity preparation was done. The pulp chamber as expected was large and root canal detection with naked eye is little difficult. Three canal orifices were tracked and all of them were located quite deep into the pulp chamber.(fig 3)

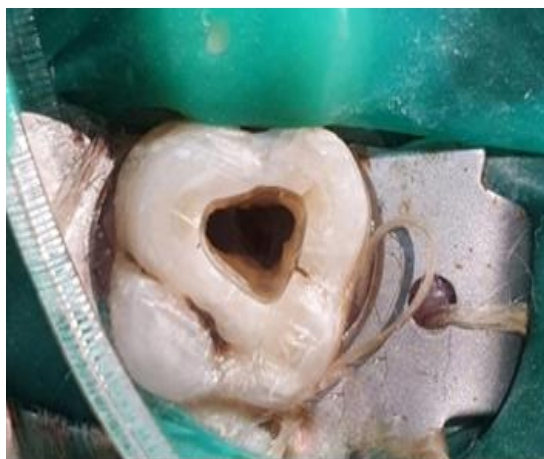


Figure 3

Electronic working length was first determined using an electronic apex locator (J. Morita Mfg Corp, Japan). Three root canals were confirmed, namely mesiobuccal, distobuccal, and large palatal canal. Canal instrumentation was then performed using ProTaper rotary Ni-Ti files (Dentsply-Maillefer, Ballagius, Switzerland).

Mesiobuccal and distobuccal canals were prepared till F2 while the large palatal canal was prepared till F3 and a master cone radiograph was taken.(fig 4)

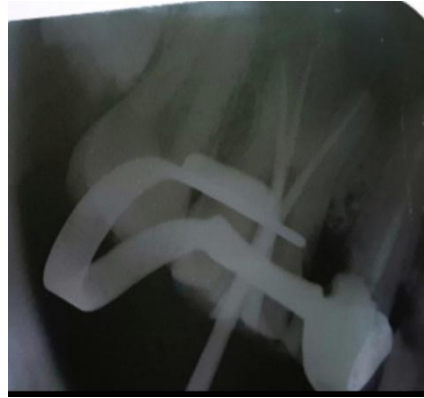


Figure 4

Irrigation was done using 2.5% sodium hypochlorite and ultrasonic activation(Ultra-X , ORIKAM). The canals were then dried using paper points. Trifurcation was sealed with F2 and F3 cones respectively . The gutta percha was sheared off with a warm fast pack. (ORIKAM)(fig 5)

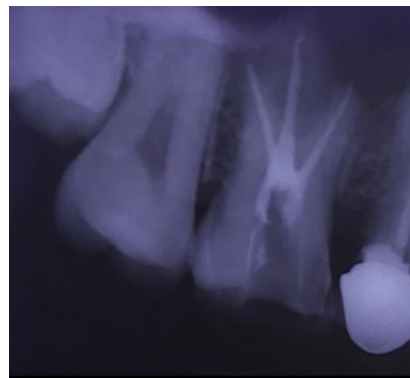
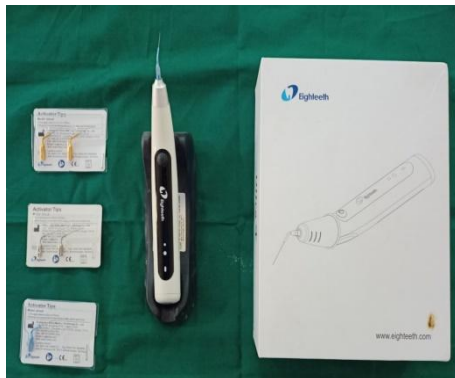

Figure 5

The wide main canal was then backfilled with eighteenth fast pack and AH plus sealer(Thermoplasticized Gutta Percha technique). AH-26 sealer (Dentsply DeTrey, Konstanz, Germany) was used for obturation. The post obturation restoration was done using composite. The patient was kept under observation. Clinically the patient was totally asymptomatic.(fig 6)

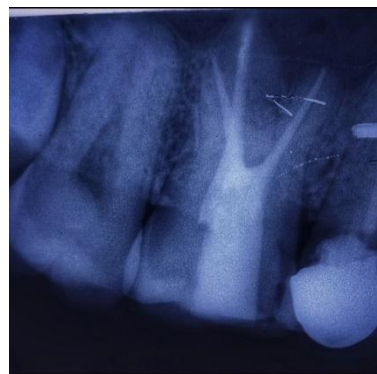
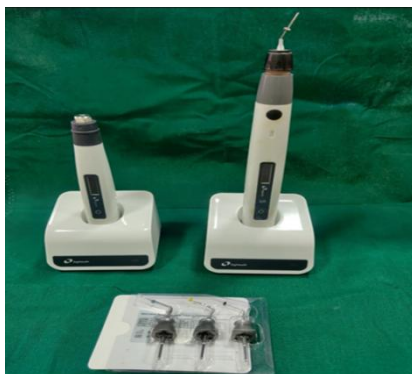

Figure 6

III. CONCLUSION

- ▶ Taurodont teeth have wide range of anatomic variations including the size and shape of pulp chambers, varying degrees of obliteration and canal complexity, apical displacement of canal orifices, and the potential for additional root canal systems.
- ▶ The dental practitioners should be well aware about these significant changes.
- ▶ While managing such tooth endodontically, careful exploration of the grooves between all orifices, particularly with magnification; ultrasonic irrigation; and a modified obturating technique are recommended. [6,8]

REFERENCES

- [1]. Ruprecht A, Batniji S, el-Neweihi E. The incidence of taurodontism in dental patients. *Oral Surg Oral Med Oral Pathol* , 1987 ;63:743-750.
- [2]. Joseph M. Endodontic treatment in three taurodontic teeth associated with 48, XXXY Klinefilter syndrome: a review and case report. *Oral Surg Oral Med Oral Pathol Oral Radiol Endod*, 2008
- [3]. Jafarzadeh H, Azarpazhooh A, Mayhall JT. Taurodontism: a review of the condition and endodontic treatment challenges. *Int Endod J*, 2008; 41(5):375-643.
- [4]. Bhat S., Sargod S., Mohammed SV. Taurodontism in deciduous molars- A case report. *J Indian Soc Pedod Prev Dent*, 2004; 22:193-199.
- [5]. Llamas R., Jimenez-Planas A. Taurodontism in premolars. *Oral Surgery, Oral Medicine and Oral Pathology*, 1993; 75: 501-506.
- [6]. Shiffmann A, Chanannel I. Prevalence of taurodontism found in radiographic dental examination of 1,200 young adult Israeli patients. *Community Dent Oral Epidemiol*, 1978; 6:200-203.
- [7]. Lehtinen R. Taurodontism A report of a case with familiar occurrence. *Suom Hammaslaak Toim*, 1971; 67:71-74.
- [8]. Hamner JE, Witkop CJ, Metro PS. Taurodontism; Report of a case. *Oral Surg Oral Med Oral Pathol*, 1964; 18:409-427.