

A case report on Dilated pore of Winer

ABSTRACT

Here we report a case of a young male presented with a nodular lesion on the leg and on histopathology diagnosed as Dilated pore of Winer.

KEY WORDS: Dilated pore of winer, skin nodule, adenexal tumor

Received 28 May, 2021; Revised: 08 June, 2021; Accepted 10 June, 2021 © The author(s) 2021.
Published with open access at www.questjournals.org

I. INTRODUCTION

Dilated pore of Winer is a benign adenexal tumor of follicular differentiation. It was usually seen on the head and neck and can also be found on the trunk of middle aged and elderly individuals. Prognosis is excellent for these lesions as they are benign and do not require any further testing or work up.

II. CASE REPORT

25 year old male presented with history of a blackish nodular swelling in the medial aspect of right lower limb with a central depression with foul smelling blackish discharge for a duration of 5 months. Initially the lesion appeared as a small papule with gradually increased in size over a period of 5 years. No history of similar illness in the past or in the family. The lesion was excised and sent for histopathological examination.

On microscopy shows a markedly dilated infundibulum with keratin and atrophic hair structures in the subinfundibular region. Epidermis is acanthotic with thin strands invading the dermis.

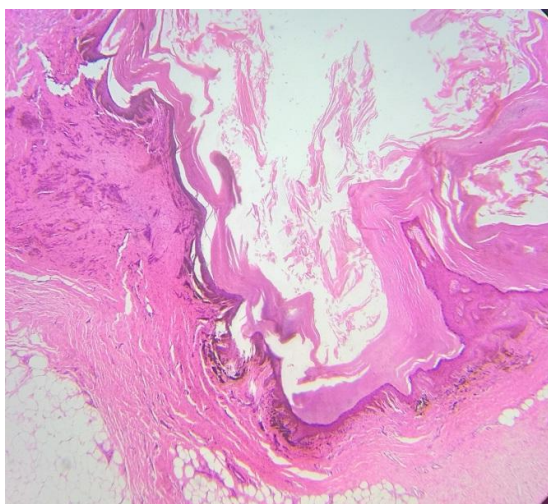


Figure 1: H& E (10X)

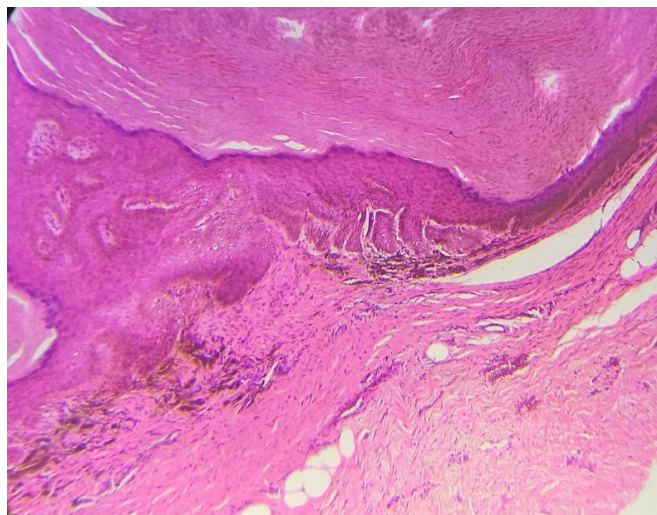

Figure 2: H & E (40X)

III. DISCUSSION

Dilated pore of Winer was first reported in 1954 by Louis H Winer. It was usually seen as solitary brown to black, giant comedo with central pore in young adult males. The exact pathophysiology of a dilated pore is unknown. It was considered as a benign adenexal tumor of follicular differentiation. Histopathologically shows markedly dilated infundibulum with keratin and atrophic hair structures in the subinfundibular region.

Acanthotic hypertrophic epidermis with thin strands invades the dermis. Prognosis is good. Excision biopsy should be deep to prevent recurrence.

IV. CONCLUSION

Dilated pore of Winer is a benign adenexal neoplasm of follicular differentiation. This case is reported for its classical clinical presentation, histopathology and its rarity.