



Research Paper

A Case Report of Successfully Managed Endo-Perio Lesion by Interdisciplinary Approach.

Dr. Mohan valiathan, Dr. Sajid Hussain, Dr. Mohanasatheesh

Department of Periodontics and Implantology, Shree Balaji Dental College and Hospital, Chennai, Tamil Nādu, India.

ABSTRACT

The relationship between pulpal and periodontal disease was first described by Simring and Goldberg in 1964. Since then, the term endo-perio lesions has been used to describe lesions due to inflammatory products found in varying degrees in both pulp and periodontal tissues. The pulp and periodontium have embryonic, anatomic, and functional interrelationships. As the tooth matures and the root is formed, three main avenues are created between pulp and periodontal ligament, i.e., dentinal tubules, lateral and accessory canals, and apical foramen. These are the pathways that may provide a means by which pathological agents pass between the pulp and periodontium, thereby creating the endo-perio lesion. Lateral canals play an important role in the spread of infection from the pulp to the periodontium. This paper reports a case of a 33-year-old patient with a combined Endo-Perio lesion.

KEY WORDS: Endo-Perio Lesion, Pulp Necrosis, Periapical Abscess, Secondary Periodontitis.

Received 19 Apr, 2022; Revised 01 May, 2022; Accepted 03 May, 2022 © The author(s) 2022.

Published with open access at www.questjournals.org

I. INTRODUCTION

The relationship between pulpal and periodontal disease was first described by Simring and Goldberg¹ in 1964. Since then, the term endo-perio lesions has been used to describe lesions due to inflammatory products found in varying degrees in both pulp and periodontal tissues. The pulp and periodontium have embryonic, anatomic, and functional interrelationships. They are ectomesenchymal in origin

(1). The pulp originates from the dental papilla and periodontal ligament from the dental follicle. They are separated by the formation of tooth bud. As the tooth matures and the root is formed, three main avenues are created between pulp and periodontal ligament i.e., (a) dentinal tubules, (b) lateral and accessory canals, (c) apical foramen².

(2). These are the pathways that may provide a means by which pathological agents pass between the pulp and periodontium, thereby creating the perio-endo lesion. Pulpal inflammation and necrosis are initiated by dental caries, restorative procedures, trauma, and chemical irritation. The oral bacteria and their components can arrive at the pulp via dental microtubules. Often in these cases, some typical signs of periodontal involvement can be observed.

Clinically symptoms such as thermal hypersensitivity, pain on percussion and radiographically a slight enlargement of the periapical periodontal space can be detected^{4 5}. In such cases, if pulp does not undergo necrosis, it reacts by producing reparative dentin formation. After the removal of etiological factors, the symptoms and signs of periapical radiolucencies should disappear. Pulp necrosis is always associated with periapical response and according to studies, it is microbiological in nature^{5 8}. After an initial phase

Where the pathological phenomenon expands from the apical part of the pulp to the periapical tissue, the second phase involves either of the possible two ways: 1) the formation of an abscess or 2) establishment of the balance between host response and bacterial challenge^{9 10}. In case of an abscess formation inflammation spreads through the periodontium. The abscess may drain through a fistula or via the periodontal ligament, with ligament and adjacent bone destruction, which can involve the entire root length. In case of the balance establishes between the host response and bacterial challenge, there will be the formation of a richly vascularized granulation tissue infiltrated by different inflammatory cells. The granulation tissue may increase in size or become cystic lesion over time. The radiographic aspect of the periodontal response to pulp necrosis consists of an area of radiolucencies localized in the proximity of the apical foramen or sometimes the accessory

lateral canals. The lateral canals contain vessels and connective tissue. Since the width of lateral canals is reduced by continuous deposition of dentin and root cementum the apical foramen remains the main pathway through which the inflammation can spread to the periodontal ligament in permanent teeth. In a periapical abscess, the lesion may perforate the cortical bone close to the apex, elevate the periosteum and overlying soft tissues, and drain into the gingival sulcus. Meanwhile, the drainage may also tract along the periodontal ligament and into the gingival sulcus or in multirooted teeth into the furcation^{3 6 7 8}. The endo-perio lesion presents a challenge to the clinicians as far as diagnosis and prognosis of involved teeth are concerned. Proper diagnosis of the lesion is essential for appropriate treatment^{7 9}. When endodontic infection drains through the periodontal ligament, a typical narrow and deep probing site can be detected or unusual extensive destruction of the periodontal tissue as in the reported following case.

II. CASE REPORT

The patient's name Mrs. Sarasu age 33 female residing in Chennai came to the department of periodontics at Sree Balaji dental college and hospital Chennai with a chief complaint of pain in the gums for the past 1 year and pain in the lower front teeth for the past 4 days

The patient's dental history reveals that she underwent uneventful extraction 10 years back

The patient's medical history reveals an accident 10 years back and suffered from a head injury, was under medication but stopped 6 months back

On extraoral examination right and left submandibular lymph nodes were palpable and lips were incompetent

An intraoral examination revealed a very poor oral hygiene and ulcers 2-3 in number in the labial mucosa, gingiva was giving a fiery red appearance with blunt and everted interdental papilla, soft and edematous consistency with loss of stippling

Recession in relation to 45, 46 with generalized bleeding on probing and exudates from 41,42,31,32

Mobility in Grade I (11, 21, 22, 43, 32, 33, 35), Grade II (41, 42, 31)

Radiographic (OPG) and Blood Investigation were done, OPG examination revealed horizontal bone loss and damage to the underlying supporting structures

With all the examinations we came to a conclusion and gave our diagnosis as generalized chronic periodontitis

The patient underwent phase I therapy which included our preliminary treatment such as scaling and root planning oral hygiene practices were also reinforced to the patient, the patient also underwent an emergency phase of treatment which included removal of hopeless teeth

The patient was recalled after one week which was part of our periodontal therapy protocol but at this time patient complained of pain in relation to 14 and 15

Extra orally there was a punctum seen on the right side of the face patient also gave a history of some discharge from the above-mentioned site

Intraoral periapical radiograph revealed presence of a carious lesion in relation to 15

The patient was referred to the department of operative and conservative dentistry for the opinion and management of 15

On endodontic treatment, it was reported that during the period of irrigation, the irrigant was seen to be leaking out through the punctum and therapy established the fact that there was a sinus tract present along with a periodontal pocket measuring 8mm.

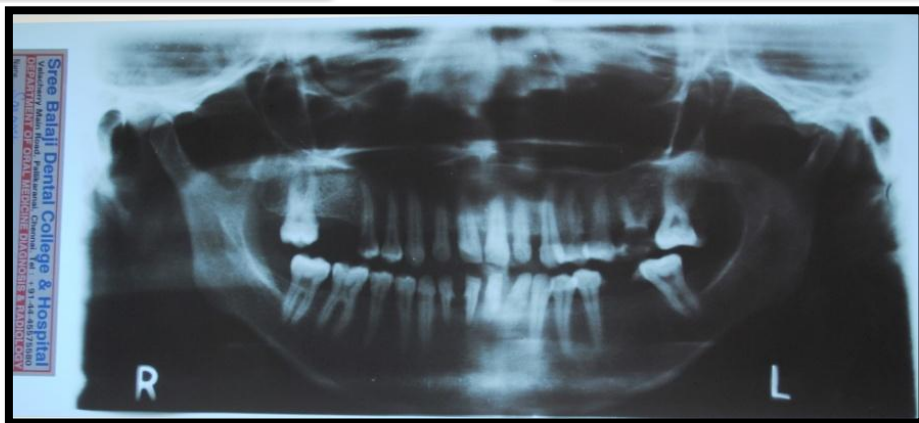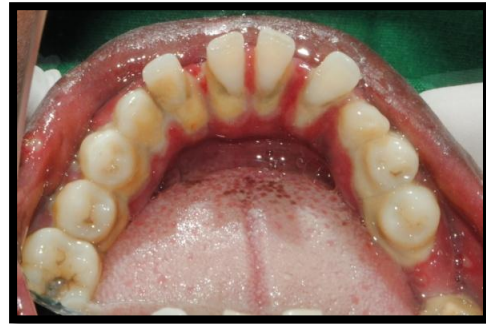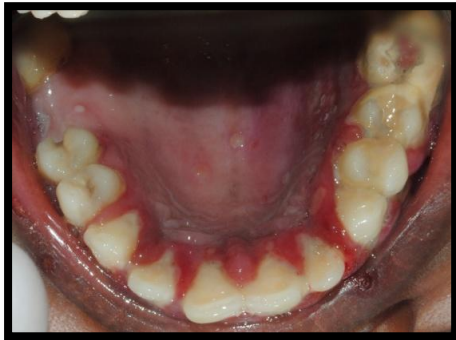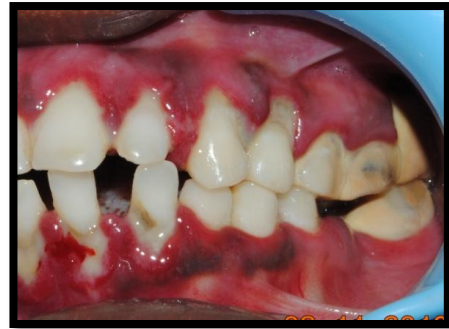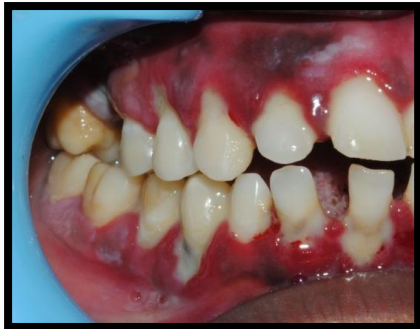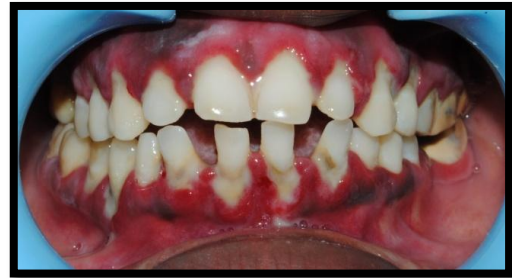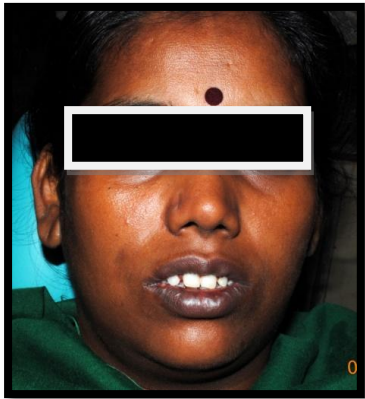Root canal was completed and patient was given antibiotics and pain killers, she was recalled after a week we found a good healing and the punctum was decreased.

III. CONCLUSION

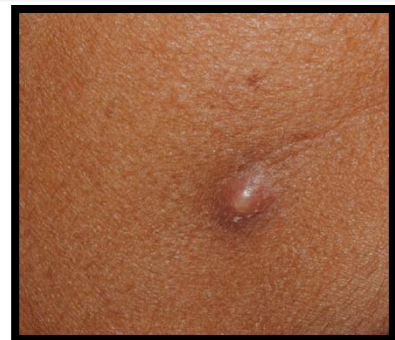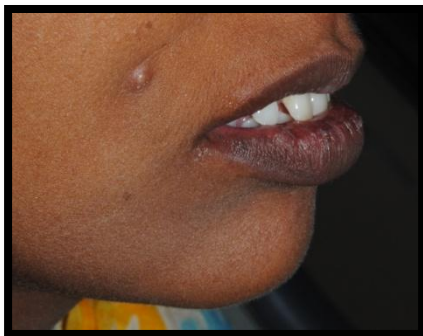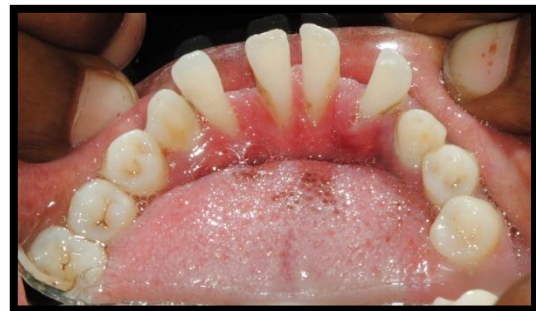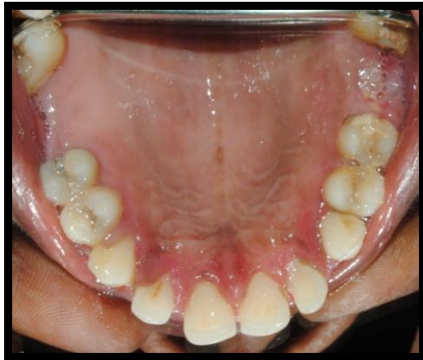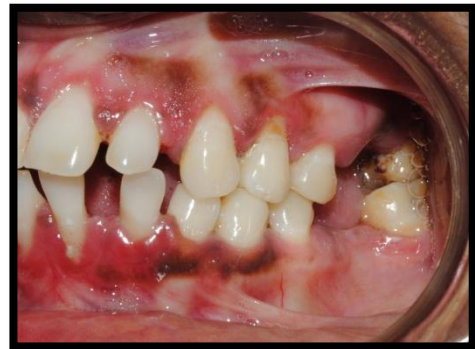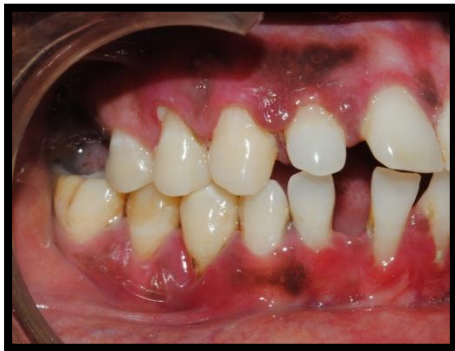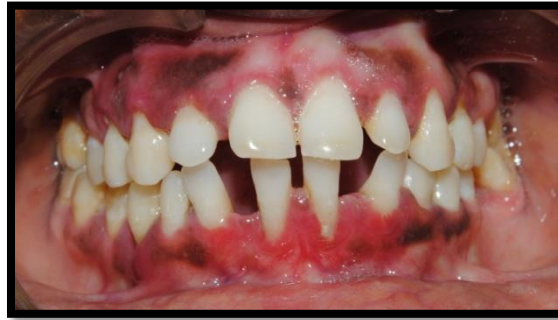The presentation of the case with mild pain associated with a deep pocket around a noncarious tooth 15, with a horizontal bone loss on the mesial aspect of 15 was typically pointing towards periodontal lesion, with extraoral sinus opening on the right-hand side of the face above the cheek, But the pulp vitality test which showed the non-vital nature of the tooth was a pivoting founding towards the endodontic nature of the lesion. So following endodontic treatment of the tooth the periodontal lesion did reduce but did not subside completely. This showed a secondary involvement of periodontal lesion along with endodontic origin. Hence it was treated with sub-gingival scaling and root planing followed by flap surgery which helped in reducing the probing depth.

Hence this case report demonstrates the nature of periodontal lesion as a secondary involvement to an originally endodontic lesion involving the tooth. As well as it demonstrates that the lateral canal can be one of the important criteria deciding for the periodontal involvement of periodontal tissue in an endodontic lesion, and in turn the prognosis of the tooth.

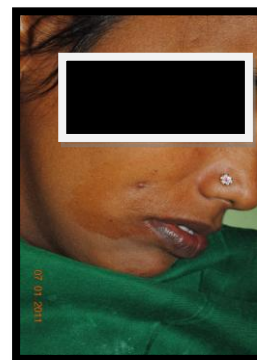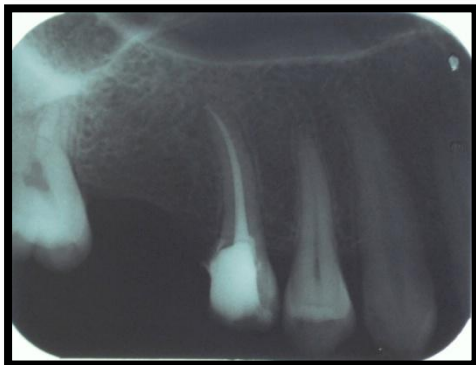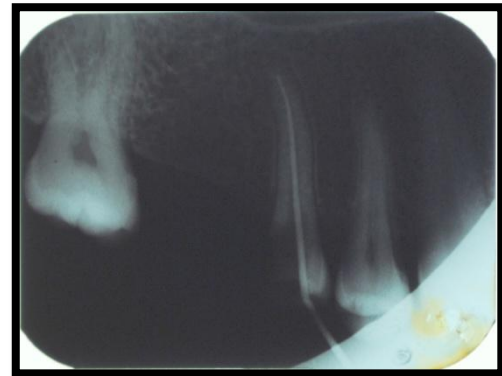
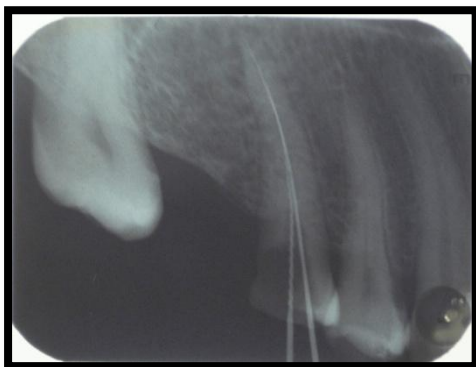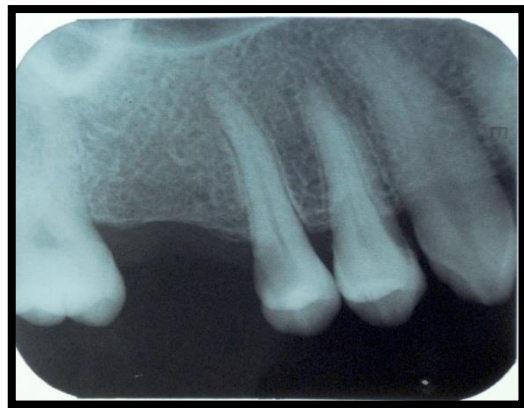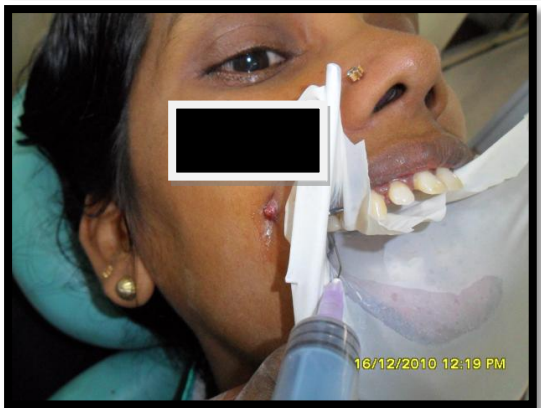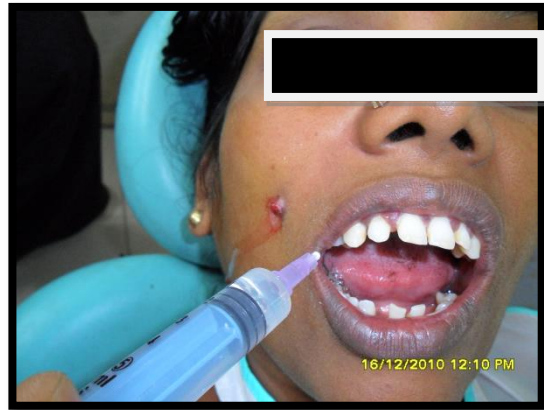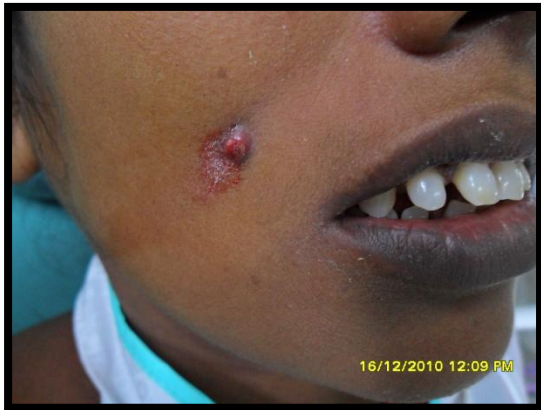PRE-OP PHOTOGRAPHS



PHOTOGRAPHS AFTER PRELIMINARY TREATMENT



DURING ENDO MANAGEMENT



REFERENCES:

- [1]. Simring M, Goldberg M. The pulpal pocket approach: retrograde periodontitis. *The Journal of Periodontology*. 1964 Jan;35(1):22-48.
- [2]. Newman MG, Takei H, Klokkevold PR, Carranza FA. *Newman and Carranza's Clinical periodontology E-book*. Elsevier Health Sciences; 2018 May 29.

A Case Report of Successfully Managed Endo-Perio Lesion by Interdisciplinary Approach.

- [3]. Pasternak-Júnior B, Teixeira CS, Silva-Sousa YT, Sousa-Neto MD. Diagnosis and treatment of odontogenic cutaneous sinus tracts of endodontic origin: three case studies. *International endodontic journal*. 2009 Mar;42(3):271-6.
- [4]. Paul BF, Hutter JW. The endodontic-periodontal continuum revisited: new insights into etiology, diagnosis and treatment. *The Journal of the American Dental Association*. 1997 Nov 1;128(11):1541-8.
- [5]. Peters DD, Baumgartner JC, Lorton L. Adult pulpal diagnosis. I. Evaluation of the positive and negative responses to cold and electrical pulp tests. *Journal of Endodontics*. 1994 Oct 1;20(10):506-11.
- [6]. Solomon C, Chalfin H, Kellert M, Weseley P. The endodontic-periodontal lesion: a rational approach to treatment. *The Journal of the American Dental Association*. 1995 Apr 1;126(4):473-9.
- [7]. Bonaccorso A, TR T. Endo-perio lesion: Diagnosis, prognosis and decision-making. *ENDO (Long Engl)*. 2014;8(2):105-27.
- [8]. Pasternak-Júnior B, Teixeira CS, Silva-Sousa YT, Sousa-Neto MD. Diagnosis and treatment of odontogenic cutaneous sinus tracts of endodontic origin: three case studies. *International endodontic journal*. 2009 Mar;42(3):271-6.
- [9]. Frick KJ, Rosen E, Tsisis I. Endodontic Considerations in the Management of Endodontic-Periodontal Lesions. *Endodontic-Periodontal Lesions*. 2019:15-51.
- [10]. Tubules D. Endodontic and Periodontal Interrelationship. This ebook is uploaded by dentalebooks. com. 2009:94.